

An Unusual Case of Difficult Extubation

MEHRDAD TAVAKOLI, M.D.,* AND GUENTER CORRSSEN, M.D.†

The self-inflatable spongy-cuffed endotracheal tube (Bivona tube) has been used in cases in which prolonged endotracheal intubation is necessary. The tube is most commonly used for prolonged mechanical ventilation in our intensive care unit, where the following complication occurred with its use.

REPORT OF A CASE

A 54-year-old white woman was admitted to the medical intensive care unit with a diagnosis of chronic respiratory failure. She had a long history of chronic obstructive pulmonary disease, recently complicated by acute pneumonia. After her admission to the MICU, the trachea was intubated nasally with a self-inflatable spongy-cuffed tube. Mechanical ventilation was satisfactory, and the clinical course improved. However, on the fourth hospital day the inflation tube of the endotracheal tube was accidentally pulled out at the point of insertion through the endotracheal tube (fig. 1).

Since the pilot tube was inoperative, the cuff could not be deflated for extubation. Direct laryngoscopy was performed using topical anesthesia to visualize the larynx, and the tube was pulled back until the cuff rested against the vocal cords. Withdrawal of the tube allowed visualization of the site at which the pilot tube was dislodged.

* Associate Professor.

† Professor and Chairman.

Received from the Department of Anesthesiology, University of Alabama Medical Center, Birmingham, Alabama 35294. Accepted for publication May 26, 1976.

Address reprint requests to Dr. Tavakoli.

A syringe with a plastic intravenous catheter, size 16, was connected to the endotracheal tube at the inflation-tube site, the cuff was deflated, and the tube was removed atraumatically (fig. 2).

DISCUSSION

The purpose of this report is to document a hazardous complication of the use of the Bivona tube and a possible defect in its manufacture. The inadvertent separation of the deflation tube resulted in "permanent" inflation of the spongy cuff. Whereas such an accident in most tubes would produce cuff deflation and leakage around the trachea, in the present case extubation was impossible.

Difficult extubations with conventional cuffs reported previously may be attributed to three mechanisms.¹ 1) The most common cause is persistent inflated cuff. The connector compresses the cuff tube and prevents deflation because a constrictive band of the internal wall of the cuff isolates a herniated portion. Entrapped air may have to be released by puncture through the cricothyroid membrane. 2) An excessively large cuff may hook on the vocal cords. 3) The tube may adhere to the tracheal wall due to absence of lubricant.²

In the present case, difficult extubation was caused by inflation of a tube that requires negative pressure to deflate, and there was no intact deflation tube. Under direct vision, the nasal tube was removed until the cuff rested just distal to the vocal cords. Fortunately,

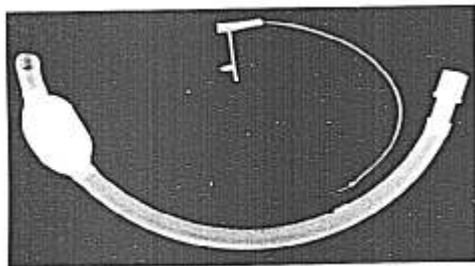
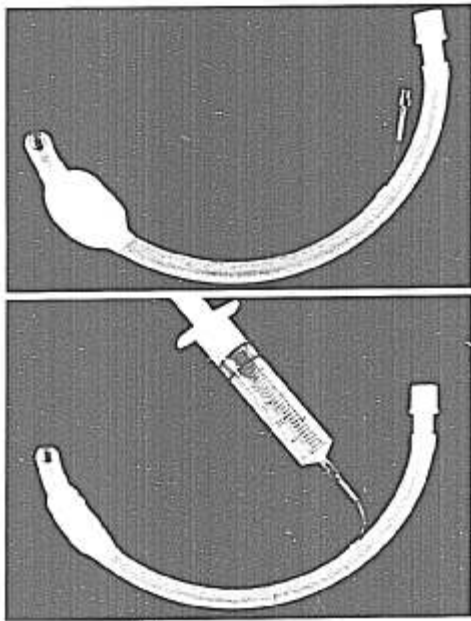


FIG. 1. Bivona endotracheal tube. The pilot tube has become disconnected from the body (see text). The result of this accident is that the tube remains inflated, and tracheal extubation is impossible.

FIG. 2. A, placement of a plastic 16-gauge intravenous catheter into the pilot tube. This is the maneuver the authors used to deflate the cuff. B, connection of a 30-ml syringe to the plastic intravenous catheter with the air aspirated so that the Bivona tube cuff is deflated.



repositioning of the tube enabled the pilot deflation tube to be cannulated with an appropriate-sized needle, and negative pressure could be applied, with subsequent cuff deflation and successful extubation. Had the cuff not been deflated, the vocal cords would have been traumatized by removal of the inflated spongy cuff.

REFERENCES

1. Blanc VF, Tremblay NAG: The complications of tracheal intubation: A new classification with a review of the literature. *Anesth Analg (Cleve)* 53:202-213, 1974
2. Dehain JJ, Lebrigand M, Binet JB, et al: Quelques incidents et accidents de l'intubation tracheale prolongee. *Ann Otolaryngol (Paris)* 85:379-380, 1968