

The author thanks Mrs. D. Grist, Mrs. R. Ichileik, and Miss E. Vieira for their invaluable assistance; all the volunteers for their co-operation; and for kindly supplying the Quantiflex apparatus, the Commercial and Industrial Dental Co., Johannesburg.

## REFERENCES

1. Langa H: Relative Analgesia in Dental Practice. Philadelphia, W.B. Saunders, 1968
2. Allen GD: Nitrous oxide-oxygen sedation machines and devices. Report of Councils on Dental Materials and Devices, and on Dental Therapeutics. J Am Dent Assoc 88: 611-614, 1974
3. Pleasants J: The case against relative analgesia. Dent Clin North Am 14:839-847, 1971
4. Faulconer A, Pender JW, Bickford RG: The influence of partial pressure of nitrous oxide on the depth of anesthesia and the electro-encephalogram in man. ANESTHESIOLOGY 10:601-609, 1949
5. Tomlin PJ, Howarth FH, Robinson JS: Post-operative atelectasis and laryngeal incompetence. Lancet 1:1402-1405, 1968
6. Taylor PA, Towey RM: Depression of laryngeal reflexes during ketamine anaesthesia. Br Med J 2:688-689, 1971
7. Kaplan S, Isdale JM, Furman EB: Pharyngeal reflexes and ketamine anaesthesia. S Afr Med J 47:795-796, 1973

## The Precordial Electrocardiographic Lead ( $V_5$ ) in Patients Who Have Coronary-artery Disease

JOEL A. KAPLAN, M.D.,\* AND SPENCER B. KING, III, M.D.†

The electrocardiograph (ECG) is now used as a routine monitor during anesthesia and operation. Cannard and co-workers showed the value of the ECG in diagnosing rhythm disturbances during anesthesia.<sup>1</sup> Standard limb lead II is usually observed because its axis parallels the electrical axis of the heart and the P wave is usually easily seen.<sup>2,3</sup>

In recent years, coronary-artery disease has become the number one health problem in the United States. Patients coming for all types of surgical procedures have significant coronary-artery disease, and many have histories of acute myocardial infarction or angina pectoris. In these patients, the ECG should be used to identify myocardial ischemia during the stress of anesthesia and operation, as well as for arrhythmia recognition.

The graded ECG exercise test is routinely used by cardiologists to diagnose coronary-artery disease. Blackburn showed that 89 per cent of the ST-segment information contained in the conventional 12-lead exercise ECG is found in lead  $V_5$ .<sup>4</sup> Therefore, we be-

gan monitoring lead  $V_5$ , along with leads I, II, III, AVR, AVL, AVF, in all patients with known coronary-artery disease. Below, we present three cases in which significant myocardial ischemia occurred intraoperatively and was observed *only* in lead  $V_5$ . This information led to early treatment of the ischemic episodes.

### REPORT OF THREE CASES

*Case 1.* A 65-year-old man was scheduled for a saphenous vein-bypass graft to the left anterior descending coronary artery. He had previously had three episodes of myocardial infarction and had progressively unstable angina pectoris. The ECG showed Q waves in leads II, III, and AVF, and nonspecific ST-segment changes. Coronary arteriography demonstrated total obstruction of the right coronary artery and more than 75 per cent cross-sectional narrowing of the left anterior descending coronary artery. Left ventricular end-diastolic pressure was 16 torr, and calculated ejection fraction was 0.40. Medications included digoxin and procainamide. Preoperative blood pressures ranged from 120/80 to 140/85 torr, while heart rate was 80/min.

Anesthesia was induced with morphine, 35 mg, and diazepam, 15 mg, and maintained with 50 per cent nitrous oxide, enflurane, and pancuronium. Vital signs were stable, with blood pressure 115/60 torr, heart rate 65/min, central venous pressure 10 cm  $H_2O$ , and isoelectric ST-segments in all seven leads of the electrocardiogram during the initial stages of the anesthesia and operation. At the time of the sternotomy, the patient was receiving 50 per cent nitrous oxide and 1 per

\* Associate Professor and Director, Division of Cardiothoracic Anesthesia.

† Associate Professor, Department of Medicine and Radiology.

Received from Emory University School of Medicine, Atlanta, Georgia 30322. Accepted for publication June 19, 1976.

Address reprint requests to Dr. Kaplan.

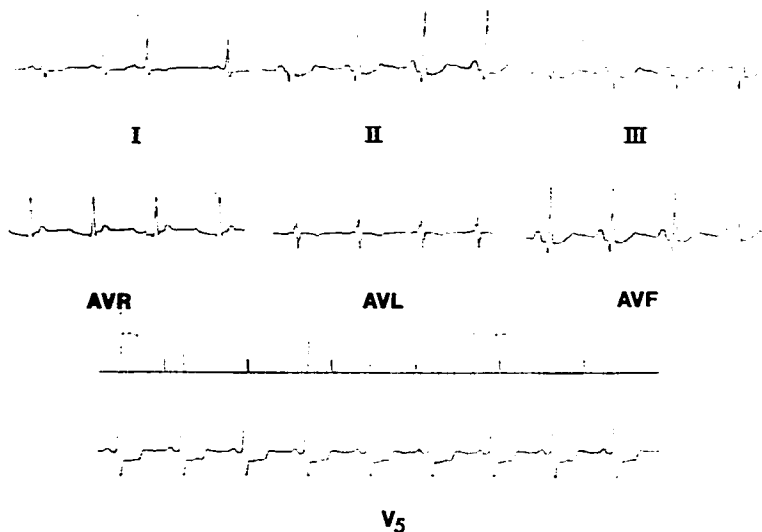


FIG. 1. Electrocardiogram after median sternotomy—heart rate is 90 beats/min. Q waves are present in leads II, III, and AVF. 3-mm horizontal ST-segment depression is present in  $V_5$ . Standardization is 1 millivolt equals 10 mm.

cent inspired concentration of enflurane. Shortly after sternotomy, the blood pressure increased to 160/90 torr, and heart rate increased to 90/min. The ECG showed no change in leads I, II, III, AVR, AVL, and AVF, but lead  $V_5$  had a 3-mm horizontal ST-segment depression (fig. 1). The myocardial ischemia in the precordial lead corresponded to the known lesion in the left anterior descending coronary artery, and was treated by increasing the concentration of enflurane and administering nitroglycerin iv at a rate of 64  $\mu\text{g}/\text{min}$ . Within five minutes, the blood pressure returned to 120/60 torr, the heart rate to 80/min, and the ST-segment of  $V_5$  was isoelectric. The remainder of the operation was uneventful, and the patient did not have a perioperative myocardial infarction.

*Case 2.* A 79-year-old woman who had cerebral vascular insufficiency was scheduled for a right carotid endarterectomy. She had had acute myocardial infarction five months preoperatively, and was having daily episodes of angina pectoris. Medications included propranolol, 20 mg, *q.i.d.*, isosorbide dinitrate, and dipyridamole. The ECG was read as nonspecific ST-segment changes. Preoperative blood pressures ranged from 110/70 to 200/100 torr, and heart rates from 50 to 75 beats/min.

Anesthesia was induced with thiopental, 150 mg, and maintained with 60 per cent nitrous oxide and enflurane (1 to 1½ per cent inspired concentration). Through the first 30 minutes of the operation vital signs remained normal, and the seven leads of the ECG all had isoelectric ST-segments. With further dissection deep into the neck, the blood pressure gradually climbed to 240/120 torr, while the heart rate remained 75/min in spite of increasing the inspired concentration of enflurane to 2½ per cent and controlling ventilation. The ECG showed no significant change in leads I, AVR, and AVL; nonspecific ST-segment depression in II, III, and AVF; but again, lead  $V_5$  had a 2-mm horizontal ST-segment depression (fig. 2A). The myocardial ischemia was relieved by decreasing the oxygen demand with an infusion of nitroglycerin at 32 to 96  $\mu\text{g}/\text{min}$ . The blood pressure returned to 150/80 torr with little change in II, III, and AVF, while lead  $V_5$  gradually returned toward normal (1 mm of up-sloping ST-segment depression) (fig. 2B). The patient recovered uneventfully and did not have another episode of myocardial infarction.

*Case 3.* A 47-year-old man who had 90 per cent obstruction of the left main coronary artery was

scheduled for saphenous vein-bypass grafts to the left anterior descending and circumflex coronary arteries. Ventriculography showed normal left ventricular function, and the preoperative ECG had only nonspecific ST-segment changes. Preoperative medications consisted of propranolol, 80 mg, *q.i.d.*, isosorbide dinitrate, and nitroglycerin. Blood pressures ranged from 130/80 to 160/90 torr, and heart rates from 60 to 70/min.

Morphine, 40 mg, and diazepam, 25 mg, were given for induction, and 50 per cent nitrous oxide and 1 to 2 per cent enflurane for maintenance of anesthesia. Vital signs remained stable early in the procedure, with blood pressures ranging from 110/70 to 150/90 torr, and all leads isoelectric on the ECG. Upon opening the pericardium, the

blood pressure dropped from 110/70 to 90/55 torr, with a heart rate of 70/min and a central venous pressure of 8 cm H<sub>2</sub>O. The standard ECG leads remained unchanged, but V<sub>5</sub> showed severe ST-segment depression (fig. 3). This was treated by shutting off the 1 per cent enflurane and administering 12.5 mg ephedrine. The blood pressure returned to 125/75 torr, and V<sub>5</sub> became isoelectric again. The remainder of the surgical procedure was uneventful.

#### DISCUSSION

Standard bipolar lead II measures the difference in potential between the left leg and

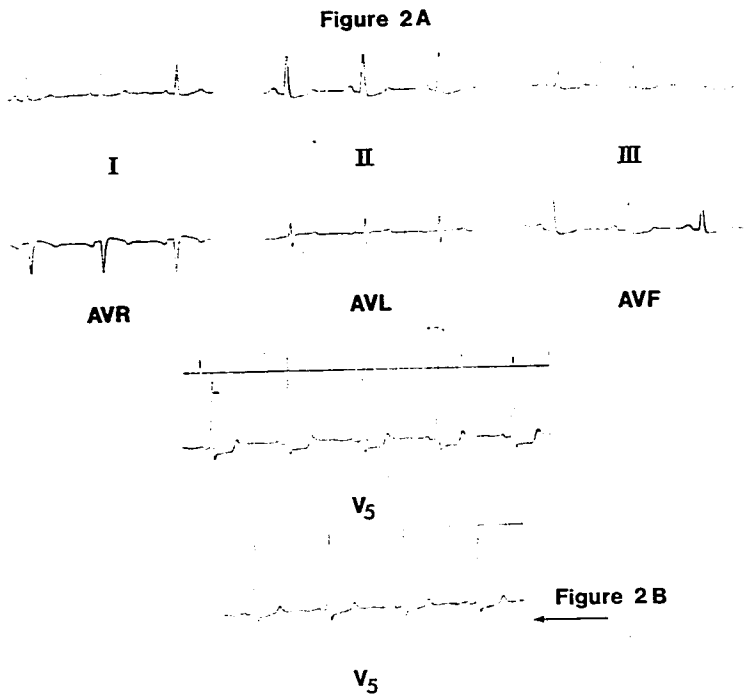


FIG. 2. A, electrocardiogram associated with hypertension of 240/120 torr. 1-mm ST-segment depression is present in leads II, III, and AVF. V<sub>5</sub> shows 2-3 mm horizontal ST-segment depression. B, V<sub>5</sub> has only 1 mm of up-sloping ST-segment depression after the blood pressure decreases. Leads II, III, and AVF remained unchanged from above.

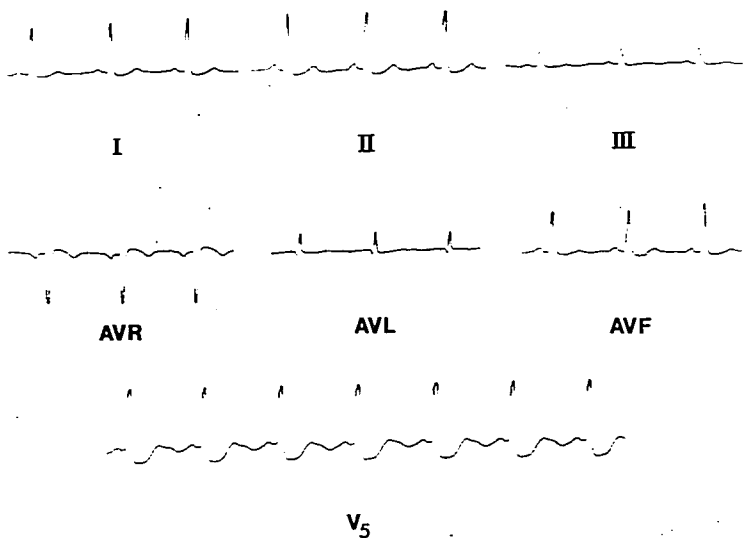


FIG. 3. Electrocardiogram associated with mild hypotension (90/55 torr) upon opening the pericardium.  $V_5$  shows severe ST-segment depression, while only minimal ST-segment changes are present in leads I, II, and AVF.

the right arm. This lead parallels the P wave vector, which points from the SA-node to the AV-node. Thus, lead II makes identification of the P wave easier and helps in differentiating ventricular from supraventricular arrhythmias. Inferior-wall myocardial ischemia may also be seen by ST-segment depression in lead II; however, the more common anterior or lateral wall ischemia may be missed.

We can gain additional information by placing electrodes around the bend of the thorax in order to view the heart from different angles. The precordial leads are unipolar, with the three limb electrodes connected together near zero potential, leaving the chest electrode as the predominant source of the ECG pattern. Since the major left ventricular electrical forces are directed along the long axis of the left ventricular mass, a lead selected near the cardiac apex ( $V_5$ ) will

best reflect these potentials. We attach the three limb electrodes in their normal positions (right arm, left arm, left leg), in addition to a fourth electrode in the  $V_5$  position (fifth interspace at the anterior axillary line). Disposable adhesive ECG pads are used and the  $V_5$  lead is covered with a small piece of Steri-drape to keep it dry. The four electrodes are then brought directly into those monitors that have a V lead selector (Tektronix, Datascope) or into a switch box (Hewlett-Packard) from which leads I, II, III, AVR, AVL, AVF, or  $V_5$  can be chosen. In those systems with only three electrodes, the  $V_5$  lead can be obtained by placing the left-arm electrode in the  $V_5$  position and selecting lead AVL. All leads are recorded before induction of anesthesia and whenever changes occur during the surgical procedure. The electrocardiogram is standardized with 1 millivolt equalling 10 mm. We consider 1 mm hor-

izontal or down-sloping ST-segment depression from baseline a significant sign of myocardial ischemia.<sup>5</sup>

It has long been recognized that multiple-lead electrocardiography is important in diagnosing ischemia during stress testing. Mason showed that in 56 patients with ST-segment changes, leads  $V_1$  to  $V_6$  were the most useful, and lead I the least informative.<sup>5</sup> In a study of 100 patients, Redwood demonstrated that the left lateral leads (I, AVL,  $V_5$  to  $V_6$ ) had ten times more positive tests than the vertical leads (II, III, AVF).<sup>6</sup> Finally, Fortuin,<sup>7</sup> Hegge,<sup>8</sup> and Robertson<sup>9</sup> have demonstrated that in most cases the location of the ST-segment changes correlates with arteriographic localization of the patient's coronary-artery disease. ST-segment changes in leads II and III correspond to disease of the right coronary artery, and ischemic changes in leads  $V_1$  to  $V_6$  indicate disease of the left anterior descending artery or circumflex coronary artery. However, in some patients it is not possible to localize the site of obstruction.

The seven leads of the electrocardiogram are recorded before induction of anesthesia in all patients with coronary-artery disease. This gives us a good baseline for intraoperative or postoperative comparison. When acute myocardial ischemia is due to increased oxygen demand, it is treated promptly by reducing the myocardial oxygen demand with either nitroglycerin (decreasing preload and afterload)<sup>10</sup> or propranolol (decreasing heart rate and contractility), or by increasing the depth of general anesthesia (Cases 1 and 2). When ischemia is due to decreased myocardial oxygen supply, it is treated by decreasing the depth of general anesthesia

and increasing the blood pressure, and thus the coronary blood flow (Case 3).

In summary, these three cases demonstrate the value of a precordial ECG lead in diagnosing myocardial ischemia during cardiac and non-cardiac surgery. In these cases, the myocardial ischemia would have remained undiagnosed and untreated without the  $V_5$  lead.

#### REFERENCES

1. Camnard TH, Dripps RD, Helwig J, et al: The electrocardiogram during anesthesia and surgery. *ANESTHESIOLOGY* 21:194-202, 1960
2. Dripps RD: Introduction to Anesthesia. Philadelphia, W.B. Saunders, 1972, pp 86-87
3. Russell PH, Coakley CS: Electrocardiographic observation in the operating room. *Anesth Analg (Cleve)* 48:784-788, 1969
4. Blackburn H, Taylor HL, Okamoto N, et al: The exercise electrocardiogram: A systematic comparison of chest lead configurations employed for monitoring during exercise. *Physical Activity and the Heart*. Edited by Karlomen M. Springfield, Ill., Charles C Thomas, 1966
5. Mason RE, Låkar I, Biern RO, et al: Multiple lead exercise electrocardiography. *Circulation* 36:517-525, 1967
6. Redwood DR, Epstein SE: Uses and limitations of stress testing in the evaluation of ischemic heart disease. *Circulation* 46:1115-1131, 1972
7. Fortuin JN, Friesinger GC: Exercise induced ST-segment elevation. *Am J Med* 49:459-464, 1970
8. Hegge FN, Tuna N, Burchell HB: Coronary arteriographic findings in patients with axis shifts or ST-segment elevations on exercise-stress testing. *Am Heart J* 86:603-615, 1973
9. Robertson D, Kostuk WT, Abuja SP: The localization of coronary artery stenosis by 12 lead ECG response to graded exercise test. *Am Heart J* 91:437-444, 1976
10. Kaplan JA, Dimbar RW, Jones E: Nitroglycerin infusion during coronary-artery surgery. *ANESTHESIOLOGY* 45:14-21, 1976