

DISCUSSION

A continuous gas flow may increase the resistance to exhalation. The amount of this resistance will depend on the rate of the continuous gas flow, the rate of the patient's expiratory flow, and the size of the orifice on the expiratory valve. In the ventilator described, partial charging of the exhalation valve by the continuous flow in the mechanical circuit retarded exhalation. Also, the continuous flow of gas maintained a slight, continuous positive airway pressure. Further charging of the expiratory valve caused complete valve closure.

The manufacturer apparently has revised and replaced the incompetent valve on all existing models of this ventilator. However, the complication described might occur with any continuous-flow system if the expiratory limb became occluded or had

significant flow resistance. Unfortunately, no suitable alarm has been developed to detect this type of complication. Therefore, one must ensure complete separation of the exhalation valve and continuous-flow systems at all times. In addition, the importance of low-resistance expiratory valves is magnified if continuous gas flow is used during IMV.

The authors thank Dr. Jerome H. Modell for support and advice, Pauline Snider for editorial advice, and William J. Embro for technical assistance.

REFERENCES

1. Downs JB, Perkins HM, Modell JH: Intermittent mandatory ventilation. An evaluation. *Arch Surg* 109:519-523, 1974
2. Johnstone RE, Smith TC: Rebreathing bags as pressure-limiting devices. *ANESTHESIOLOGY* 38:192-194, 1973

Anesthesiology
46: 73-75, 1977

Re-establishment of Radial-artery Patency for Arterial Monitoring

THOMAS W. FEELEY, M.D.*

Radial arterial cannulation for measurement of arterial blood pressure and blood gases is of considerable importance to the management of many critically ill patients.¹ In patients who require prolonged cannulation, thrombotic occlusion of the artery often results in the eventual failure of the catheter to function. We have seen four patients with radial-artery thrombosis in whose cases radial arterial monitoring was considered mandatory for optimal care. The technique described below re-established flow in the thrombosed artery to allow monitoring.

METHOD

The procedure was used in four patients on five occasions. There had been previous radial arterial cannulations in four of the five arteries explored. A palpable pulse was absent in all cases. The radial artery was isolated by a cutdown at the wrist. A ligature was placed loosely around the artery proximal and distal to the proposed puncture site (see figure 1). An 18-gauge 2-inch plastic catheter† was placed into the lumen of the vessel using the catheter needle for introduction. Aspiration of blood was attempted. In all cases no blood could be aspirated. The catheter was removed. Retrograde

flow from the palmar arch could be demonstrated by proximal occlusion of the artery in all five instances. A #3 French embolectomy catheter‡ was then introduced into the vessel through the arteriotomy made by the Angiocath. The catheter was advanced proximally approximately 25 cm, the balloon inflated, and the catheter slowly withdrawn. Sufficient thrombotic material was removed to re-establish flow after one passage of the catheter in three of the procedures. In the remaining two procedures two and three passes were required to re-establish flow. An 18-gauge Angiocath was then inserted into the vessel through the same arteriotomy site. The proximal ligature was tied around the vessel and catheter to prevent bleeding from the arteriotomy in two of the five procedures. The distal ligature was removed and the skin closed.

RESULTS

The clinical data are summarized in table 1. The five catheters placed in this manner functioned for as long as 72 hours. In Patient 1 the catheter was removed after 48 hours, at which time it was still functional. A functioning catheter was present in Patient 2 for 32 hours until his death. Patient 3 had bilateral radial-artery thrombectomies. A catheter in the right radial artery functioned for 72 hours before thrombosing, whereupon a catheter placed in the left radial artery functioned until his death 45 hours later. Patient 4 had a functioning catheter for 40 hours, after which it was removed.

* Clinical Fellow in Anaesthesia, Harvard Medical School, and Chief Resident in Anaesthesia, Beth Israel Hospital, Boston, Massachusetts 02215. Present address: Department of Anesthesia, University of California, San Francisco, California 94143.

Accepted for publication September 6, 1976.

Address reprint requests to Dr. Feeley.

† Angiocath. Deseret Pharmaceutical Co., Inc., Sandy, Utah 84070.

‡ Shiley arterial embolectomy catheter. Shiley Laboratories, Inc., Santa Ana, California 92711.

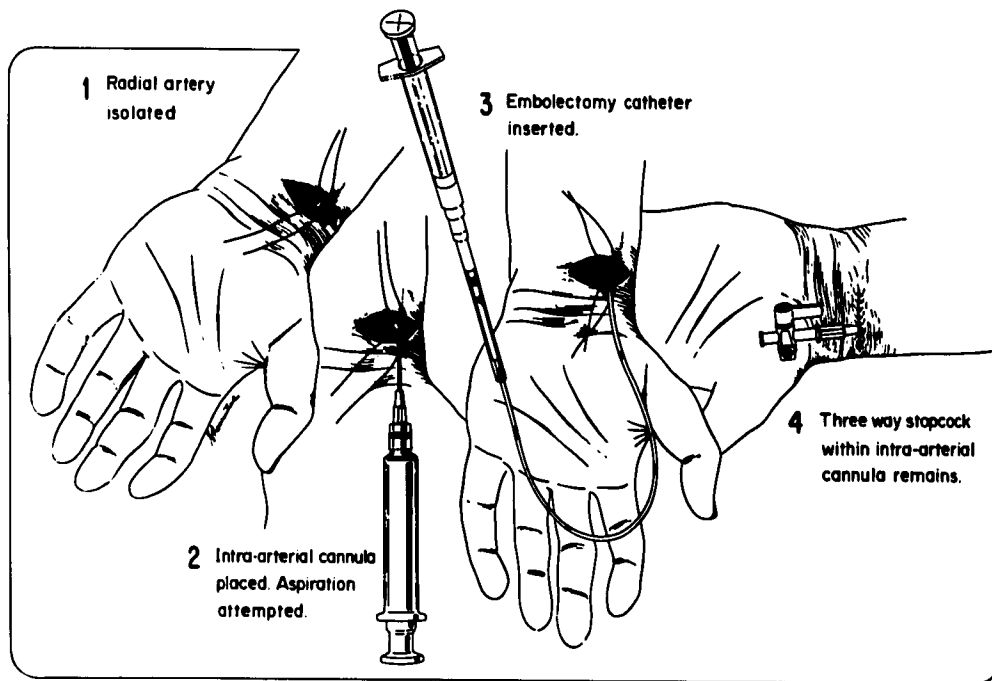


FIG. 1. Technique of catheter thrombectomy of the radial artery. The radial artery is isolated at the wrist by cutdown and a ligature is placed around it proximal and distal to the proposed puncture site (1). An 18-gauge Angiocath is inserted into the artery, the cannula is removed, and an attempt is made to aspirate blood (2). If no blood can be aspirated the Angiocath is removed and a #3 French embolectomy catheter is inserted through the arteriotomy made by the Angiocath (3). The catheter is advanced proximally 25 cm, the balloon inflated, and the catheter slowly withdrawn to remove thrombotic material. When flow is re-established the 18-gauge Angiocath is reintroduced into the vessel for monitoring and a three-way stopcock is attached. The distal ligature is removed. The proximal ligature may be removed or tied if necessary to control bleeding from the arteriotomy site. The skin is then closed (4).

There was no case of ischemia to the digits or bleeding from the cutdown site. All catheters performed satisfactorily for arterial pressure monitoring and blood-gas sampling.

DISCUSSION

Catheter thrombectomy allowed re-establishment of radial arterial patency for monitoring in situations in which the usual sites were not available. There was evidence of thrombus formation secondary to prior radial arterial cannulation four of the five times the technique was used. The etiology of the radial arterial thrombosis in Patient 1 was obscure. A

non-tapered 18-gauge plastic catheter has a thrombosis rate proportional to the duration of cannulation to a maximum of 38 per cent after 40 hours, after which the rate does not increase.² All of the patients who had had prior cannulation had catheters in place for more than 40 hours.

Each of the patients received flow to the digits from collateral circulation, demonstrable by retrograde flow from the palmar arch. Retrograde cannulation of the arch would have placed the digits at risk of ischemia, as would ulnar arterial cannulation. The opposite radial artery of two patients could not be used because of the presence

TABLE 1. Clinical Data

	Age (Years), Sex	Diagnosis	Duration Prior Cannulation	Time Since Decannulation	Duration Function New Cannula*
Patient 1	66, M	Ruptured abdominal aortic aneurysm	—	—	48 hours
Patient 2	58, M	Hepatic failure	6 days	5 days	32 hours
Patient 3 Right radial Left radial	72, M	Aspiration pneumonia	8 days 7 days	7 days 4 days	72 hours 45 hours
Patient 4	69, M	Ruptured abdominal aortic aneurysm graft	48 hours	19 days	40 hours

* Time from insertion until catheter was either removed or the radial artery rethrombosed.

of a nonfunctioning radial-artery catheter. In the other two patients the opposite radial artery could not be used because numerous attempts at percutaneous cannulation had been unsuccessful.

There are several advantages in using this technique of catheter thrombectomy. The collateral circulation to the palmar arch can be demonstrated. A #3 French embolectomy catheter is easy to insert through the arteriotomy made by the 18-gauge Angiocath. After flow in the radial artery has been re-established, the Angiocath is reinserted through the same arteriotomy, avoiding the need for suturing the arteriotomy. A tie is placed around the artery and catheter when necessary to prevent excessive bleeding from the arteriotomy. Catheter throm-

bectomy of the radial artery is a means of successfully re-establishing radial arterial flow when the radial artery is felt to be the optimal site for blood pressure and blood-gas monitoring.

The author thanks Drs. J. Hedley-Whyte, J. J. Skillman, and E. Salzman for their review of the manuscript.

REFERENCES

1. Hedley-Whyte J, Burgess GE III, Feeley TW, et al: Applied Physiology of Respiratory Care. Boston, Little, Brown and Company, 1976, pp 95-99
2. Bedford RF, Wollman H: Complications of percutaneous radial artery cannulation: An objective prospective study. ANESTHESIOLOGY 38:228-236, 1973

Anesthesiology
46: 75-77, 1977

Paroxysmal Supraventricular Tachycardia during Anesthesia

DAVID H. SPRAGUE, M.D.,* AND SAMUEL D. MANDEL, M.D.*

Compared with their ventricular counterparts, paroxysmal supraventricular tachycardias often are considered benign dysrhythmias unless they are prolonged and refractory to standard treatment or occur in the presence of myocardial disease.^{1,2} However, during the altered hemodynamic state associated with anesthesia, these dysrhythmias may rapidly produce deleterious cardiovascular effects that necessitate immediate therapy to prevent serious sequelae. This point is illustrated by the following cases.

REPORT OF FOUR CASES

Case 1. A 24-year-old healthy woman was scheduled for cesarean section because of cephalopelvic disproportion. After subarachnoid injection of tetracaine, a healthy infant was delivered while the maternal blood pressure and pulse remained in the range of 110-120/50-65 torr and 95-110 beats/min. As an infusion of oxytocin was started, the pulse abruptly increased to 190 beats/min, and the blood pressure decreased to 100/50 torr. The electrocardiogram (fig. 1) indicated a 1:1 ratio of atrial to ventricular conduction with a regular ventricular rate. Although carotid massage was performed, no change in heart rate was obtained. As the tachycardia continued, the blood pressure decreased to 55/40 torr. Therefore, methoxamine (20 mg, iv, in divided doses) was given, causing the pulse to slow to 100 beats/min and blood pressure to increase to 125/60 torr. Fifteen minutes later, another abrupt increase in pulse to 180 beats/min occurred with a decrease in blood pressure to 90/50 torr. Carotid massage at this time produced a slowing of the rate to 96 beats/min and an increase in blood pressure to 120/65 torr. At this time,

results of arterial blood-gas and serum electrolyte determinations were normal. The rest of the patient's hospitalization was uneventful.

Case 2. A 20-year-old woman was scheduled for incision and drainage of an infected hand. After being premedicated with meperidine and atropine, the patient was brought to the operating room and anesthesia was induced with thiopental, nitrous oxide, and halothane. Shortly after induction, the patient's pulse increased abruptly from 92 to 184 beats/min. The electrocardiogram showed rapid regular atrial activity with a 1:1 ratio of atrial to ventricular conduction. Carotid massage combined with edrophonium (20 mg, iv, in divided doses) produced no change in heart rate. Therefore, phenylephrine (2 mg, iv) was given and an abrupt reduction of rate to 98 beats/min occurred. The rest of the anesthetic course was uneventful.

Case 3. After being medicated with scopolamine and secobarbital, a 4-year-old boy was brought to the operating room for herniorrhaphy. Anesthesia was induced with thiopental and maintained with cyclopropane via an endotracheal tube. While the lower abdominal wall was being prepped, a sudden increase in pulse rate from 100 to 176 beats/min and a decrease in blood pressure from 110/70 to 85/60 torr occurred. The electrocardiogram indicated a 1:1 ratio of atrial to ventricular conduction at a fixed rate. After the anesthetic had been discontinued, carotid massage and positive airway pressure were administered, producing an abrupt return of the blood pressure and pulse to normal values. The anesthesia was continued without further cardiovascular instability.

Case 4. Three weeks after a subendocardial infarction, a 60-year-old woman was scheduled for a coronary-artery bypass graft. After receiving diazepam and morphine, the patient was brought to the operating room and an inhalational induction was performed using nitrous oxide and halothane. While anesthesia was maintained with nitrous oxide and halothane, the bypass graft procedure was performed during 55 minutes of extracorporeal circulation. After the extracorporeal circulation had been discontinued, the patient was able to maintain a blood pressure of 120-140/70-90 torr and a pulse of 100-

* Assistant Professor of Anesthesiology, Department of Anesthesiology, Yale University School of Medicine, 333 Cedar Street, New Haven, Connecticut 06510.

Accepted for publication September 6, 1976.

Address reprint requests to Dr. Sprague.