

Treatment of Diffuse Metastatic Cancer Pain by Instillation of Alcohol into the Sella Turcica

Jordan Katz, M.D.,* and Allan B. Levin, M.D.†

The technique of "chemical hypophysectomy" was modified for the management of pain due to metastatic cancer. Using stereotaxic control, a needle is introduced via the nose into the sella turcica. Absolute alcohol is then injected into the pituitary. Of 13 patients who had severe uncontrollable pain, 11 obtained marked symptomatic relief. The longest follow-up period to date is seven months, with results persisting. Sequelae are those associated with destruction of the pituitary gland, the most significant being diabetes insipidus. Several cerebrospinal fluid leaks prompted us routinely to instill alpha-ethyl cyanoacrylate to seal the sella floor. Three patients had slight extraocular nerve palsies. There was no death related to the procedure. (Key words: Cancer, pain therapy; Anesthetic techniques, pituitary ablation.)

MANAGEMENT OF PAIN in patients who have diffuse metastatic cancer is normally very difficult. If chemotherapy or radiotherapy is not successful, the patient is usually subjected to neurodestructive procedures and/or maintained on narcotics. In many patients who have diffuse metastatic cancer, the usual neurosurgical procedures are not possible, and the use of narcotics becomes the only therapeutic avenue remaining. Narcotics are effective to a point. However, tolerance often occurs, necessitating larger doses, which accentuate the unwanted sequelae of their use—anorexia, confusion, malaise, constipation, respiratory depression, etc. Even with the higher doses, many patients do not receive adequate pain relief. The search for additional means of therapy continues in order to help this group of patients through the terminal portion of their illness. The following is a report of our experience with a new pain-relieving procedure, instillation of alcohol into the sella turcica.¹

Materials and Methods

Thirteen patients who had diffuse metastatic cancer represent the preliminary investigational group. Seven of the patients had primary prostatic carcinoma, two had carcinoma of the cervix, two had clear-cell carcinoma of the kidney, one had carcinoma of the breast, and one had carcinoma of the bladder. All had diffuse metastases and uncontrollable pain.

* Professor and Associate Chairman, Department of Anesthesiology.

† Assistant Professor, Department of Neurosurgery.

Received from the University Hospitals, 1300 University Avenue, Madison, Wisconsin 53706. Accepted for publication September 23, 1976.

Address reprint requests to Dr. Katz.

General endotracheal anesthesia was established with a thiopental-N₂O/O₂-succinylcholine sequence. A wire spiral extender was interposed between the endotracheal tube and the circle system to facilitate maintaining the position of the patient in a Todd-Wells stereotaxic head holder (fig. 1). Occasionally, low concentrations of halothane were added to the anesthesia mixture for maintenance. Neuroleptanalgesia has also been advocated because it allows the operator to monitor eye movements during the injection.¹

The target was then placed at the posterior superior aspect of the sella turcica in the midline, using a procedure similar to that used previously for performance of radiofrequency hypophysectomy.² Cocaine, 4 per cent, was applied topically to produce vasoconstriction of the nasal mucosa. After preparation of the nasal passage with povidone-iodine solution, a drill guide was placed in the left nostril. The mucosa at the tip of the guide was infiltrated with 1 per cent lidocaine and epinephrine for additional hemostasis. Using a 2.7-mm drill, a hole was made in the floor of the sphenoid sinus, which was then thoroughly irrigated with bacitracin solution (5,000 µl/100 ml of saline solution).

A needle guide was then added to the probe and a 6-inch 20-gauge spinal needle was gently inserted through the floor of the sella turcica (figs. 2 and 3). In cases where the bone of the sella was hard, a small hole was drilled with a K-wire whose diameter was slightly larger than that of the spinal needle. The position of the needle was checked by x-ray; when it was at the target, absolute alcohol was injected. As much as 2 ml of alcohol per injection was deposited at various depths within the sella (fig. 4). A total of 5 to 6 ml was usually used.

In the cases of Patients 4 through 13, alpha-ethyl cyanoacrylate (0.5 ml) was injected as the spinal needle was withdrawn from the sella to prevent leakage of spinal fluid. The sphenoid sinus was once again irrigated with bacitracin solution. Last, before the patient was awakened, the nasal passages were packed with vaseline gauze.

Results

The results are represented in table 1. Our longest follow-up period to date has been seven months. Eleven of the 13 patients had good to excellent pain relief, which occurred almost im-

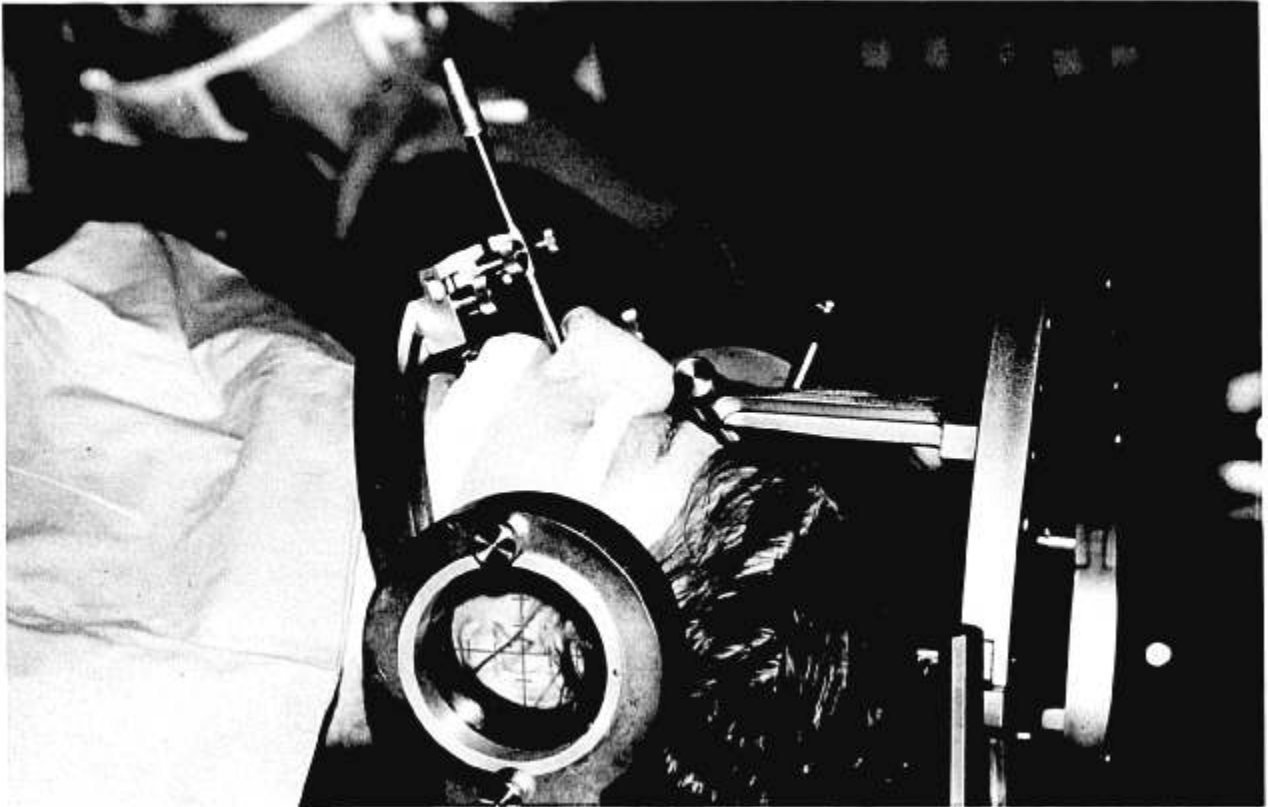


FIG. 1. Patient with Todd-Wells stereotaxic head holder in place.

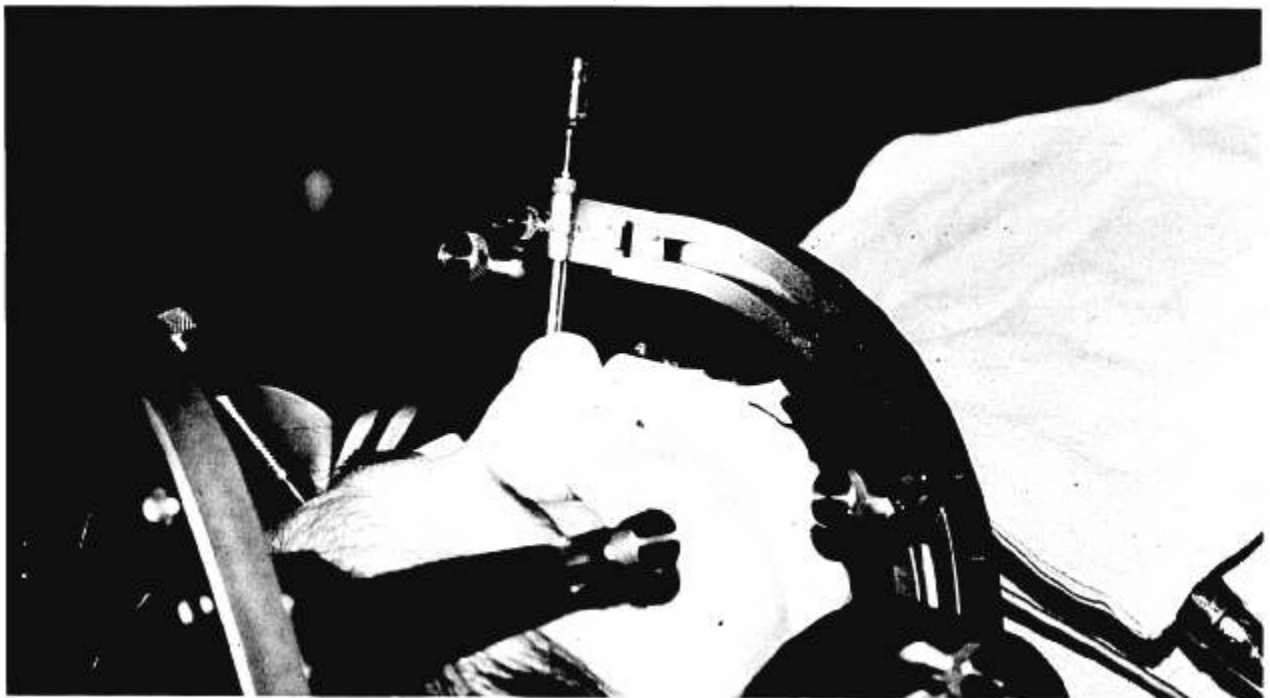


FIG. 2. Spinal needle inserted into sella turcica.

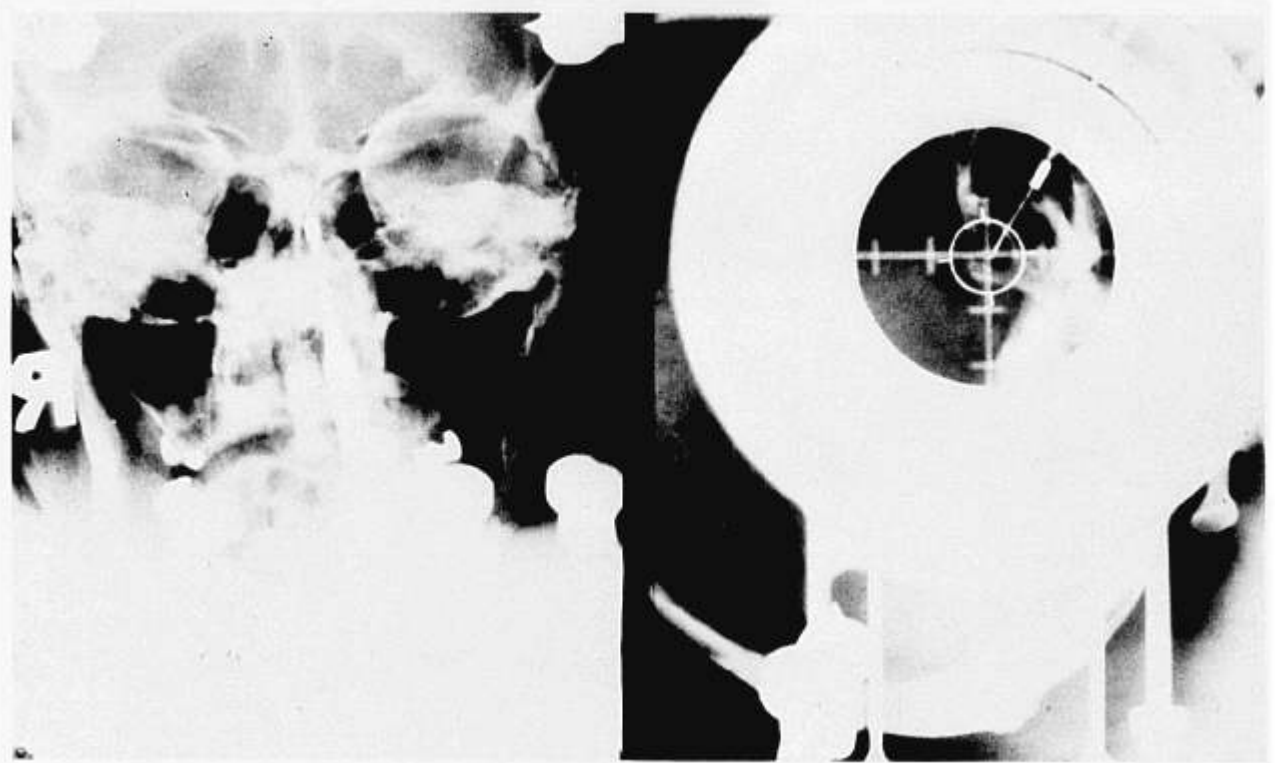


FIG. 3. Radiograph showing A-P and lateral views of spinal needle at target in sella.

mediately after the operative procedure. This reduction in pain persisted throughout the period of evaluation. Similar improvements in ambulatory status were noticed in those patients. Ten of the 13 patients had been confined to bed prior to the procedure due to pain. Five became ambulatory

within several days of operation. Three had limited mobility because of muscle weakness rather than pain. In only two was residual pain a significant part of the limitation of mobility.

Patients 2, 6, 7, 9, and 11 deserve further explanation. Patient 2, a young woman who had metastatic

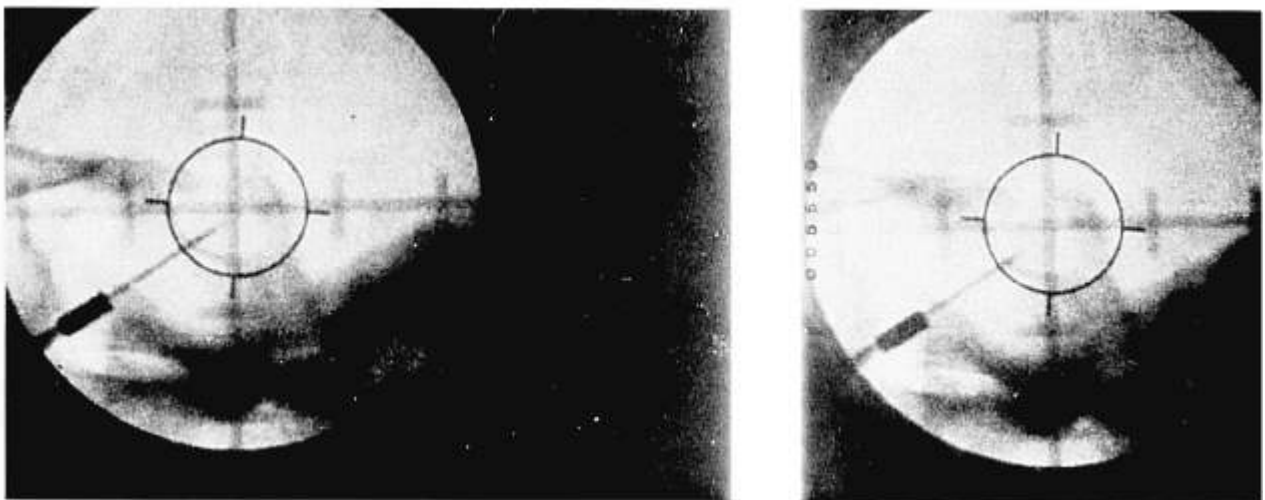


FIG. 4. Radiograph showing two positions of spinal needle during alcohol injection.

TABLE 1. Pain Status of the Patients*

	Site of Primary Tumor	Preoperative	Postoperative								Remarks
			24 Hr	2 Wk	4 Wk	8 Wk	12 Wk	16 Wk	20 Wk	26 Wk	
Patient 1	Prostate	4	3	2	1	1	1	1	1	1	Died of disease 20 weeks postoperatively
Patient 2	Cervix	4	3								See text
Patient 3	Prostate	4	1	0	1	1					Died of disease 9 weeks postoperatively
Patient 4	Kidney	4	0	0	0	0	1	1	1		Died of disease 20 weeks postoperatively
Patient 5	Prostate	4	1	1	2	1	2	2	2	2	Now 30 weeks postoperative
Patient 6	Prostate	4	2	0	1	2					See text
Patient 7	Prostate	3	0	0	2	0					See text
Patient 8	Prostate	3	1	1	1						Died of disease 6 weeks postoperatively
Patient 9	Kidney	4	2	1	1	2					See text
Patient 10	Bladder	4	0	2	2						Died of disease 4 weeks postoperatively
Patient 11	Cervix	4	0	2	3	3	1				See text
Patient 12	Prostate	4	0	0	0	0					Continued pain free—10 weeks postoperative
Patient 13	Breast	4	0	0							Died of disease 4 weeks postoperatively

- * 4 = poorly controlled with large doses of narcotics.
 3 = reasonable control requiring large parenteral doses of narcotics.
 2 = controlled with oral narcotics (*i.e.*, codeine).
 1 = controlled with oral analgesics (*i.e.*, aspirin).
 0 = controlled, no medication needed.

and invasive carcinoma of the cervix, was considered a treatment failure. Even though she had a modest decrease in pain, this was not deemed sufficient to withhold further therapy. Bilateral percutaneous cordotomies done four days apart provided good pain relief until her demise several months later.

Patient 11 was also a young woman who had metastatic and invasive carcinoma of the cervix. She had back and bilateral leg pain. Following injection there was alleviation of the back pain, which was due to osseous and paravertebral lesions. The leg pain, which was secondary to direct neural invasion did not respond. The patient continued to need narcotics. A left percutaneous cordotomy three months later provided excellent relief of the residual pain.

Patient 6 represents our single significant complication. It was noticed at the time of the advancement of the spinal needle into the sella turcica that the bone appeared quite soft. Two weeks after the procedure, the patient developed a significant cerebrospinal fluid (CSF) leak. This was followed in 48 hours by bacterial meningitis, which was treated

with penicillin, with clinical and laboratory evidence of remission. The CSF rhinorrhea persisted until, in the fifth postoperative week, alpha-ethyl cyanoacrylate was instilled into the floor of the sella to seal it and stop the leak. The patient remained relatively pain-free throughout the postoperative period. He died seven weeks after the original operation. Postmortem examination showed, in addition to the diffuse metastatic disease of the prostate, that 90 per cent of the pituitary and all of the pituitary stalk had been destroyed. The bone of the sella was invaded by tumor tissue not disclosed by preoperative x-rays. We believe this was the cause of the CSF leak. There was also an intracerebral hemorrhage secondary to rupture of a posterior communicating artery aneurysm, which was thought not to be due to the procedure. The hypothalamus showed only scattered areas of neuronal death. There was a moderate inflammatory reaction around the base of the hypothalamus.

Patient 7 had a slight recurrence of pain a month after the procedure that necessitated the oral use of

narcotics (codeine). He requested a second procedure, which was performed during the fourth week. This left him pain-free until his death in the eighth week after the original operation.

Patient 9 had immediate pain relief rated subjectively at 50 per cent. He remained unhappy with this extent of relief, and a second injection was performed nine days later, with further reduction in pain.

Diabetes insipidus severe enough to necessitate treatment occurred in ten of the 13 patients. Five of the ten patients needed pitressin tannate in oil, five units every other day, subcutaneously, in the early postoperative period. In the remaining five patients the diabetes was managed with oral and intravenous administration of fluids. Four patients needed intermittent lysine vasopressin nasal spray (a synthetic antidiuretic hormone) after discharge because of excessive urinary output. No patient was discharged during treatment with pitressin tannate. All patients were maintained on hydrocortisone and thyroid in the postoperative period.

In addition to Patient 6, two of our first three patients developed CSF leaks. This prompted the use of the alpha-ethyl cyanoacrylate in the remaining cases. With the exception of that of Patient 6, there has been no CSF leak requiring treatment. Two patients (4 and 8) developed slight ocular nerve palsies of the sixth and third nerves, respectively. The nerve deficits were minimal but remained until death.

In Patient 11, left third and sixth nerve palsies, as well as a hemianopsia in the left eye, developed. Within three weeks the neurologic deficits had cleared, leaving only ptosis and an upper nasal quadrant defect in the left eye, with otherwise full extraocular movements and fields of vision.

After the procedure Patient 13 had an inferior temporal field defect in the left eye, which cleared in about ten days. This patient died a month after the procedure. At autopsy, there was complete necrosis of the gland and stalk. Areas of coagulative necrosis in portions of the hypothalamus (tuber cinerium, infundibulum and medial eminence) were found. The paraventricular and supraoptic nuclei were intact, as was the optic nerve.

The reports on Patients 6 and 13 have been our only postmortem examinations to date.

Discussion

The use of chemical hypophysectomy for the relief of cancer pain was instituted in 1963 by Moricca.¹ Previous reports indicating benefit from surgical procedures such as adrenalectomy, orchidectomy, oophorectomy, and hypophysectomy prompted his initiation of this new technique. One or more stainless steel needles were introduced

through the nostril into the sella turcica under x-ray control. Small amounts of alcohol were then injected into the pituitary gland. Initially, patients who had hormone-related tumors, primarily metastatic carcinoma of the breast, were treated by this method of hypophysectomy. Prompted by the rapid onset of pain relief, earlier than would be expected if solely due to hormonal changes, the therapy was offered to all patients who had metastatic disease. From 1963 until 1973, Moricca treated 687 patients who had advanced malignancies. Of these patients 605 had pain relief that was characterized as complete, immediate and lasting. It was necessary to repeat the procedure a second time in a large proportion of cases, and occasionally even to repeat it a third and fourth time to maintain the level of analgesia. Nearly 1,600 sellar injections were carried out in the 687 patients. In addition to the pain relief, a high incidence of diabetes insipidus and lower incidences of hypoadrenalism and hypothyroidism, as well as decreases in libido, were reported. Rhinorrhea, ptosis, diplopia, and hemianopsia occurred in small percentages of patients, though the exact incidences cannot be determined from Moricca's published work and the complications were self-limited and minor. In a later presentation in 1975, his series had been expanded to 884 patients undergoing 2,120 procedures. Again, the results were reported as excellent.³

This work stimulated investigators at the Center for Pain Relief in Liverpool, England, to institute similar therapy. They have also reported gratifying results. Approximately a third of their patients obtained total pain relief; a third, significant relief; the remaining third had marginal, if any, decrease in discomfort. It must be remembered that this group of patients had proven refractory to usual therapeutic regimens. At the time of this writing the Liverpool series is approaching 100 patients. Two significant complications have occurred—one patient had permanent hemianopsia; a second died from infection spreading to the brain from the sphenoid sinus (personal communication).

In concurrent studies in England, using radiopaque material (Myodil) injected with the alcohol, it was noticed that the dye flowed up the pituitary stalk and across the floor of the third ventricle. When contrast material was injected into the sella turcica at autopsy the base of the hypothalamus was stained, as well as the pituitary and stalk.⁴

The reports of these two groups of investigators prompted us to institute this technique in treatment of patients whose pain status could not be adequately controlled by any modality. The use of a stereotaxic apparatus appeared to be a logical approach to the sella turcica. In our opinion,

the precision of such a method had advantages over the freehand needle advancement done by both the Italian and the English groups. It also allowed us to use a single 20-gauge spinal needle to enter the pituitary fossa and to advance this within the gland with precise control.

Our longest follow-up period to date has been 30 weeks, with continued remission of pain. However, the Italian group has had many patients in whom remission has lasted years. Pain relief, according to them, has been satisfactory even over these long periods. Similarly, the English investigators have had several patients who are approaching a year of satisfactory pain relief.

The complications from the procedure, including CSF rhinorrhea, diabetes insipidus, and other hormonal derangements, may appear significant. However, from the patient's point of view they are minor compared with the relief of pain that is afforded them. Most of the complications appear to be self-limiting or can be adequately controlled with hormonal replacement.

A clinical observation common to the three teams studying this technique is that in certain patients tumor regression appears to occur. This has been documented by radiographically demonstrated decreases in the sizes of osseous metastases. In addition, soft-tissue metastases have been found to decrease in size. In our limited series, this was dramatic in the case of Patient 5, who had a large supraclavicular mass that regressed to the point where it was no longer palpable 18 weeks post-operatively.

Two theories have been advanced to explain the efficacy of this type of treatment. The first is that hormonal deficiencies are caused by the complete disruption of the hypothalamic pituitary axis and destruction of a major portion of the pituitary gland. Although this may explain a part in the prolonged analgesia sustained by patients who have hormone-dependent tumors, it is unlikely that the immediate and profound pain relief can be explained in this way.

The second theory, proposed by both the Italian and English investigators, hypothesizes that "pain pathways" in the hypothalamus are in some way affected. There is ample anatomic evidence to show extensive neural connections among the hypothalamus, thalamus, limbic system, and various portions of the central gray matter.⁵⁻⁹ These systems receive information from lower spinal areas such as the lateral spinothalamic tract that are known to transmit the sensation of pain. In animal studies, electrical stimulation in all of the above-mentioned brain areas via stereotaxically placed electrodes has been shown to decrease responses to noxious stimuli.¹⁰⁻¹⁶ It has been sug-

gested by Liebeskind *et al.* that such stimulation results in analgesia by enhancing mechanisms that tend to modify pain appreciation. Periventricular and central gray regions, in particular, are thought to produce a morphine-like substance that decreases the response to aversive stimuli.¹⁷ Results of stimulation in man have been mixed, with some investigators claiming success and others finding the procedure unreliable in producing analgesia.¹⁸⁻²⁰

In any case, if alcohol does produce a lesion in the hypothalamus, it is probably destructive rather than stimulatory in nature. We have been unable to find evidence suggesting that destructive lesions in the region of the hypothalamus could modify the appreciation of pain, and conclude that the hypothesis that alcohol interrupts hypothalamic "pain pathways" is conjectural, at best.

We have no neurophysiologic explanation for the immediate and profound pain relief our patients obtained.

This method of hypophysectomy is technically simple, and should be considered for other related conditions where ablation of the pituitary gland is necessary.

References

1. Moricca G: Chemical hypophysectomy for cancer pain. *Adv Neurol* 4:707-714, 1974
2. Zervas NT: Technique of radiofrequency hypophysectomy. *Confin Neurol* 26:157, 1965
3. Moricca G: Neuroadenolysis (chemical hypophysectomy) for diffuse unbearable cancer pain (abstr). Proceedings of the First World Congress on Pain, Florence, Italy, September 5-8, 1975
4. Miles J, Lipton S: The mode of action by which pituitary alcohol injection relieves pain (abstr). Proceedings of the First World Congress on Pain, Florence, Italy, September 5-8, 1975
5. Kuypers HGJM: Certain fiber connections of the mesencephalic central gray matter, *Progress in Neurobiology*. Edited by Ariens-Kappers J. New York, Elsevier, 1956, pp 264-272
6. Beyer C, Tindal JS, Sawyer CH: Electrophysiological study of projections from mesencephalic central gray matter to forebrain in the rabbit. *Exp Neurol* 6:435-450, 1962
7. Morest DK: Connexions of the dorsal tegmental nucleus in rat and rabbit. *J Anat (Lond)* 95:229-246, 1961
8. Nauta WJH: Hoppocampal projections and related neural pathways to the mid-brain in the cat. *Brain* 81:319-340, 1958
9. Kuypers HGJM, Lawrence DG: Cortical projections to the red nucleus and the brain stem in the rhesus monkey. *Brain Res* 4:151-188, 1967
10. Mayer DJ, Wolfe TL, Akil H, et al: Analgesia from electrical stimulation in the brain stem of the rat. *Science* 174:1351-1354, 1971
11. Liebeskind JC, Gisele G, Besson JM, et al: Analgesia from electrical stimulation of the periaqueductal gray matter in the cat: Behavioral observations and inhibitory effects on spinal cord interneurons. *Brain Res* 50:441-446, 1973

12. Reynolds DV: Surgery in the rat during electrical analgesia induced by focal brain stimulation. *Science* 164:444-445, 1969
13. Akil H, Mayer DJ: Antagonism of stimulation-produced analgesia by p-CPA, a serotonin synthesis inhibitor. *Brain Res* 44:692-697, 1972
14. Black P, Cianci SN, Markowitz RS: Alleviation of pain by hypothalamic stimulation in the monkey. *Confin Neurol* 34:374-381, 1972
15. Schmidek HH, Ervin FR, Sweet WH: Alterations in the pain threshold produced by mesencephalic, thalamic, and limbic stimulation in the awake squirrel monkey (*Saimiri sciureus*). *Fed Proc* 27:518, 1968
16. Valenstein ES, Beer B: Reinforcing brain stimulation in competition with water reward and shock avoidance. *Science* 137:1052-1054, 1962
17. Liebeskind JC, Mayer DJ, Akil H: Central mechanisms of pain inhibition: Studies of analgesia from focal brain stimulation. *Adv Neurol* 4: 261-268, 1974
18. Heath RG, Mickle WA: Evaluation of seven years experience with depth electrode studies in human patients, *Electrical Studies on the Unanesthetized Brain*. Edited by Ramey ER, O'Doherty DS. New York, Hoeber, 1960, pp 214
19. Gol A: Relief of pain by electrical stimulation of the septal area. *J Neurol Sci* 5:115-120, 1967
20. White JC, Sweet WH: Pain and the Neurosurgeon—a Forty-Year Experience. Springfield, Ill., Charles C Thomas, 1969, pp 901-904

Pulmonary Physiology

ISOPROTERENOL AND PULMONARY SHUNTING Twelve mongrel dogs weighing 15-18 kg were anesthetized with pentobarbital and their lungs ventilated mechanically following tracheal intubation. The femoral vein and aorta were cannulated, and a Swan-Ganz catheter was placed in the pulmonary artery. Control values for pulmonary shunting, cardiac output, pulmonary arterial pressure, pulmonary-artery wedge pressure, and pulmonary vascular resistance were obtained following establishment of a steady state. An intravenous infusion of isoproterenol, 0.1 $\mu\text{g}/\text{kg}/\text{min}$, was given for two hours. Measurements were made 5, 15, 30, 60, 90, and 120 minutes following the start of the infusion. Pulmonary shunting, cardiac output, and pulmonary arterial pressure significantly increased at

all measurement times compared with control values, with maximum changes obtained at 30, 15, and 5 minutes, respectively. There was no significant change in pulmonary-artery wedge pressure. Pulmonary vascular resistance decreased at all measurement times. These decreases were significant only at 15, 30, and 60 minutes. The increase in pulmonary shunting was assumed to be due to ventilation-perfusion inequalities secondary to increased pulmonary blood flow and pulmonary arteriolar vasodilation. Use of isoproterenol in critically ill patients could lead to respiratory distress. (*Berk JL, and others: Pulmonary insufficiency produced by isoproterenol. Surg Gynecol Obstet* 143:725-726, 1976.)