

Clinical Reports

BURNELL R. BROWN, JR., M.D., Ph.D., Editor

Anesthesiology
46:145-147, 1977

Management of Cesarean Section in a Patient with Idiopathic Thrombocytopenic Purpura

JAMES P. ANGIULO, M.D.,* JAMES T. TEMPLE, M.D.,† JAMES J. CORRIGAN, JR., M.D.,‡
JORGE H. GALINDO, M.D.§

Previous reports of the management of idiopathic thrombocytopenic purpura (ITP) and pregnancy recommend cesarean section as the preferred method of delivery.^{1,2} Platelet transfusions are routine to minimize maternal hemorrhage at the time of operation.²⁻⁴ The following case illustrates a practical method to determine the optimal amount of platelets to transfuse.

REPORT OF A CASE

A 25-year-old white woman, gravida 1, para 0, was transferred to the Arizona Medical Center on October 18, 1975, with a diagnosis of thrombocytopenia. Four weeks prior to admission she had had a proven streptococcal upper respiratory tract infection treated with penicillin, glyceryl guaiacolate and dextromethorphan (Robitussin-DM). Shortly after the onset of her illness she had noticed erythematous patches over the anterior surfaces of both tibias. Three weeks prior to admission she had noticed an increased bruising tendency, and four days prior to admission, gingival bleeding upon brushing her teeth. The remainder of the history was non-contributory. Physical examination on admission was entirely within normal limits except for multiple ecchymotic areas over all extremities. Examination of the abdomen revealed the uterine size to be compatible with a 39-week gestation. Fetal heart tones were normal and the fetus was in a vertex presentation, but the presenting part was not engaged. The spleen was not palpable. Significant laboratory studies included hemoglobin 12.8 g/100 ml, hematocrit 38 per cent, leukocyte count 8,400/mm³, platelet count 10,000/mm³. The following tests were within normal limits: urinalysis, haptoglobin, plasma hemoglobin, prothrombin time, partial thromboplastin time, fibrinogen, SGPT, SGOT, LDH isoenzymes, bilirubin, antinuclear antibody, LE cell test, urobilinogen, and slide test for infectious mononucleosis (Mono Spot™)

* Assistant Professor of Anesthesiology.

† Chief Resident, Department of Anesthesiology.

‡ Professor of Pediatrics, Chief, Section of Pediatric Hematology-Oncology.

§ Assistant Professor of Obstetrics and Gynecology.

Received from the Departments of Anesthesiology, Obstetrics and Gynecology, and Pediatrics of the University of Arizona Medical Center, Tucson, Arizona 85724. Accepted for publication September 14, 1976.

Address reprint requests to Dr. Angiulo.

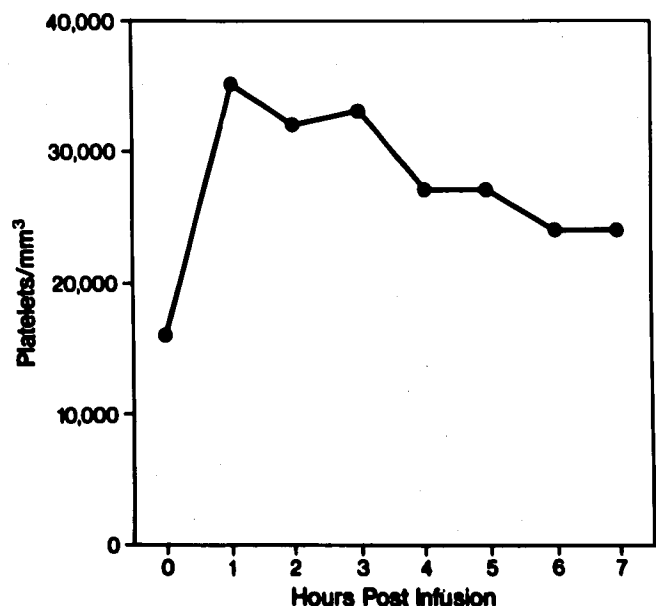


FIG. 1. Platelet survival after infusion of a six-platelet-concentrate challenge.

A bone marrow aspirate was normocellular, with an increased number of megakaryocytes; abnormal cells were not seen. On the basis of these findings, a diagnosis of acute immune thrombocytopenic purpura (idiopathic thrombocytopenic purpura, ITP) was made, and treatment was started with prednisone, 60 mg, *p.o.*, *t.i.d.* An ultrasonic scan of the abdomen on the fourth hospital day revealed a single fetus with a gestational age of 40 weeks. Platelet counts ranged from 3,000 to 16,000/mm³ during the first five days, and a cesarean section was planned for the sixth day.

Prior to operation the patient's response to a platelet challenge was determined. Six platelet concentrates produced a 19,000/mm³ increase in the platelet count (3,200/mm³ per concentrate). Approximately half the infused platelets were still circulating five to six hours after infusion (see fig. 1). Based on this challenge, it was estimated that 18 platelet concentrates would acutely increase the platelet count 58,000/mm³. The 18 concentrates were infused just prior to cesarean section, and the alterations in platelet count over the ensuing six hours are shown in figure 2.

Using nitrous oxide-relaxant general anesthesia, a normal 3,050-g male infant was delivered. Apgar scores

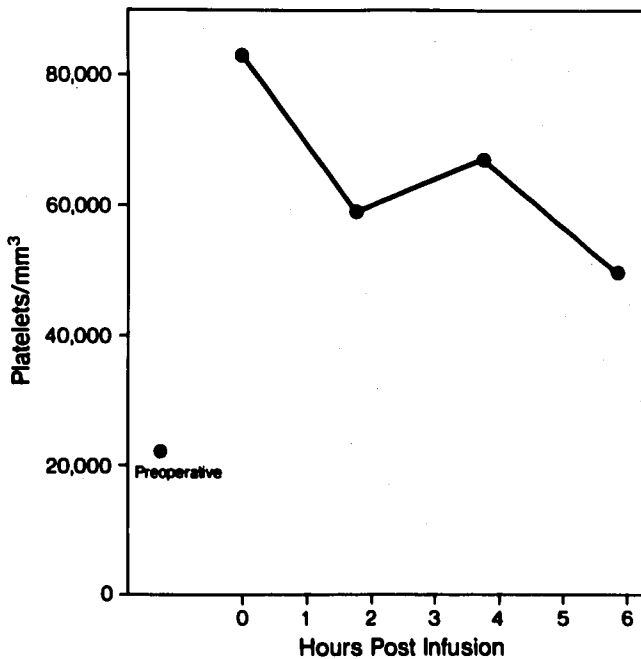


FIG. 2. Platelet survival after infusion of 18 platelet concentrates.

were 8 and 9 at 1 and 5 minutes. There was no unusual bleeding, and the estimated blood loss was 1,000 ml, with no blood transfusion given. Hemoglobin was 11.6 g/100 ml and hematocrit 34.2 per cent on the second postoperative day. The patient recovered without complication and was discharged on the twelfth postoperative day with a platelet count of 8,000/mm³. The patient continued to receive prednisone therapy for the next six weeks without significant response and underwent splenectomy on December 7, 1975, without complication. The corticosteroids were discontinued, and the platelet count five months after splenectomy was 245,000/mm³.

The infant did well throughout the hospital stay. He was slightly thrombocytopenic at birth, with a platelet count of 112,000/mm³ and with counts ranging between 119,000 and 216,000/mm³ during the next eight days.

DISCUSSION

The transplacental transfer of maternal anti-platelet antibodies frequently causes passive neonatal thrombocytopenia.^{1,5} This predisposes the infant to bleeding, the most hazardous form being intracranial hemorrhage. Territo recommends cesarean section for parturients with platelet counts of less than 100,000/mm³ to avoid the risks of cerebral trauma to the infant and hemorrhage in the mother from the expulsive efforts of labor.¹ To minimize the maternal hazards of operation, preoperative platelet transfusions are recommended. In the normal patient transfusion of a single platelet concentrate would be expected to increase the platelet count approximately 7,000 to 11,000/mm³/m²

body surface area with a platelet half-life of about four days.⁶⁻⁹ However, platelet survival is shortened in ITP as a result of platelet destruction, with a direct relationship between platelet count and values of platelet survival.³ Harker and Finch, studying normal individuals, found immediate post-transfusion platelet recovery to average 65 per cent of the amount infused. The platelets not in circulation were presumed to reflect splenic sequestration. These investigators found identical recovery values in patients with ITP; however, platelet survival as determined by peripheral platelet count was reduced to 48-230 minutes.¹⁰

In his review, Baldini lists only two major indications for platelet transfusions in ITP: temporary arrest of an acute life-threatening hemorrhage, or as preparation for surgical operation.³ He recommends two to six platelet concentrates for platelet transfusion one to two hours before operation. In other case reports of cesarean section in patients with ITP, varying numbers of platelet concentrates (five to 11) were given prior to operation.^{2,4}

A platelet count of at least 60,000 to 70,000/mm³ is recommended to provide normal hemostatic mechanisms prior to operation,^{11,12} and 18 platelet concentrates were necessary in our patient to achieve this level. If the previously cited recommendations had been followed, the increase in platelet count would have been inadequate. However, the platelet challenge used in this case allowed accurate determination of the number of platelet concentrates necessary to achieve hemostatic platelet levels.

Studying the survival curve of sodium-⁵¹chromate-tagged platelets would yield the same information as a challenge without the need for a large platelet transfusion. However, the authors were reluctant to expose the fetus to a radioactive substance. Moreover, the challenge that was performed can easily be done by anesthesiologists at hospitals where radioactive scanning devices are not readily available.

We recommend that platelet survival be determined prior to elective surgical procedures in patients who have ITP since a variety of platelet survival times can be expected in this group of individuals. Ideally, the platelets should be obtained by single-donor plateletpheresis to reduce the hazards of hepatitis transmission, increases in platelet antigens, and febrile reactions.

REFERENCES

1. Territo M, Finklestein J, Oh W, et al: Management of autoimmune thrombocytopenia in pregnancy and in the neonate. *Obstet Gynecol* 41:579-584, 1973
2. Jones WR, Storey B, Norton G, et al: Pregnancy compli-

- cated by acute idiopathic thrombocytopenic purpura. *J Obstet Gynaecol Br Commonw* 81:330-332, 1974
- Baldini MG: Idiopathic thrombocytopenic purpura and the ITP syndrome. *Med Clin North Am* 56:47-64, 1972
 - Laros RK, Sweet RL: Management of idiopathic thrombocytopenic purpura during pregnancy. *Am J Obstet Gynecol* 122:182-191, 1975
 - Flessa HC: Hemorrhagic disorders and pregnancy. *Clin Obstet Gynecol* 17:236-249, 1974
 - Blood Component Therapy. Edited by Myhre BA. American Association of Blood Banks, Washington, D. C., 1975, p 16
 - Morrison FS: Platelet transfusion. *Vox Sang* 11:656-662, 1966

- Abrahamsen AF: Survival of ⁵¹Cr-labelled autologous and isologous platelets as differential diagnostic aid in thrombocytopenic states. *Scand J Haematol* 7:525-528, 1970
- Kotilainen M: Platelet kinetics in normal subjects and in haematological disorders. *Scand J Haematol suppl* 5, 1969
- Harker LA, Finch CA: Thrombokinetics in man. *J Clin Invest* 48:963-974, 1969
- Huestis DW, Bove JR, Busch S: Practical Blood Transfusion. Boston, Little, Brown & Company, 1976, p 297
- Troup SB, Schwartz SI: Hemostasis, surgical bleeding and transfusion, Principles of Surgery. Edited by Schwartz SI. New York, McGraw-Hill, 1969, p 89

Anesthesiology
46:147-148, 1977

Broken-needle Complication with a Disposable Spinal Introducer

MARLENE ENG. M.D.,* AND ROD A. ZOROTOVICH, M.D.†

Disposable needles have become widely accepted for use in the administration of regional anesthesia. There is little chance of needle breakdown because of prior bending and straightening stresses on the needle shaft. The following case is reported to call attention to the fact that needle breakage remains a potential complication during regional block.

REPORT OF A CASE

A 19-year-old youth was scheduled for removal of a left femoral intramedullary nail utilizing spinal anesthesia. Premedication produced a sedated cooperative patient. He was placed in the left lateral decubitus position and the skin was prepared and draped for administration of the spinal anesthetic at the L3-4 interspace through a paramedian approach.¹ A 25-gauge 3½-inch disposable spinal needle (Becton Dickinson) and a 20-gauge 1¼-inch disposable introducer (Becton Dickinson) were selected for use. The initial insertion of the introducer led to placement of the tip of the 25-gauge needle at the L3 lamina. The introducer was gently withdrawn to the subcutaneous level to select a pathway with a slightly more obtuse angle. The spinal needle then slipped into the intervertebral space and the introducer and needle were advanced to the maximum depth possible before the

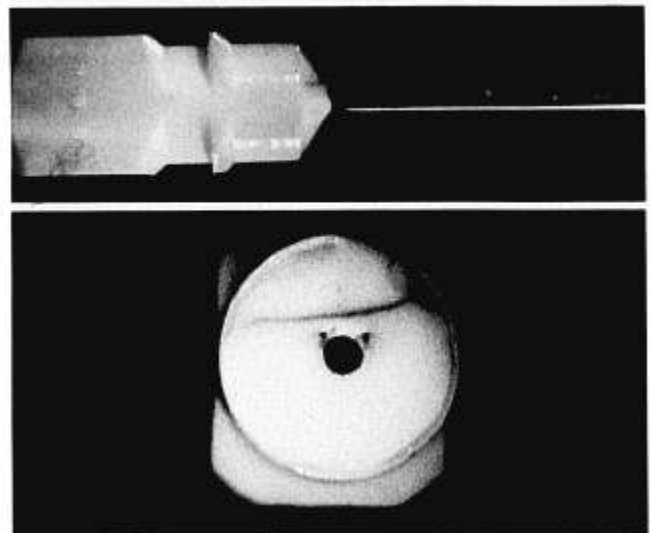


FIG. 1 (above). Hub separated from needle shaft. A small fragment of the hub remains attached to the shaft. The point where the piece was originally positioned can be seen at the tip of the hub taper.

FIG. 2 (below). End view of needle hub, showing crack (fine dark line running from right to left) and position of plastic fragment that remained attached to the needle shaft.

* Associate Professor of Anesthesiology. Present address: Department of Anesthesiology, University of Texas Medical School at Houston, 6400 West Cullen, Houston, Texas 77025.

† Resident in Anesthesiology.

Received from the Department of Anesthesiology and the Anesthesia Research Center, University of Washington School of Medicine, Seattle, Washington 98195. Accepted for publication September 20, 1976.

Address reprint requests to Dr. Eng.

subarachnoid space was identified. The local anesthetic was injected and the needles were withdrawn by grasping the hub of the introducer and removing both introducer and spinal needle with one motion. On close inspection of the removed needles the metal needle shaft of the spinal introducer was found missing. The free needle shaft was palpable immediately under the patient's skin; however, probing with a hemostat through a small incision in the skin made the needle