

3. Locke W, Schally AV: The Hypothalamus and Pituitary in Health and Disease. Springfield, Ill, Charles C Thomas, 1972, pp 290-347
4. Myles AB, Daly JB: Corticosteroid and ACTH treatment. Baltimore, Williams and Wilkins, 1974, pp 162-167
5. Pearson OH: Endocrine consequences of hypophysectomy. *ANESTHESIOLOGY* 24:563-567, 1963
6. Meyers EF, Wilson S: Vitrectomy: A new challenge for the anesthesiologist. *Anesth Analg (Cleve)* 54:58-64, 1975
7. Wilson AM: Anesthesia for Sheehan's syndrome: A case report. *Br J Anaesth* 40:996-998, 1968
8. Vandam LD, Moore FD: Adrenocortical mechanisms related to anesthesia. *ANESTHESIOLOGY* 21:531-552, 1960
9. Vio M, Fiaschi A, Ferrari G: Neuromuscular complications in the course of panhypopituitarism. *Acta Neurol (Napoli)* 28:425-432, 1973
10. Woodbury DM: Relation between the adrenal cortex and the central nervous system. *Pharmacol Rev* 10:275-357, 1958
11. Stewart AG, Sprunt JG: Hypopituitarism and flexor muscle spasm. *Acta Endocrinol (Kbh)* 53:489-498, 1966

Anesthesiology
46:150-151, 1977

Modification of Nitrous Oxide-induced Intracranial Hypertension by Prior Induction of Anesthesia

JOHN R. PHIRMAN, M.D.,* AND HARVEY M. SHAPIRO, M.D.†

Reports have documented intracranial pressure (ICP) elevations in neurosurgical patients associated with the induction of anesthesia with nitrous oxide.^{1,2} Our recent observations of ICP changes in a deeply comatose patient confirm the ability of nitrous oxide to elevate ICP and indicate that prior induction of anesthesia with diazepam and thiopental can block intracranial hypertension due to nitrous oxide.

REPORT OF A CASE

A previously healthy, 90-kg, 22-year-old man was admitted to the University of California Medical Center in San Diego with a history of the abrupt onset of headache followed by deepening coma. Cerebral angiography revealed an arteriovenous malformation of the upper brainstem.

Following performance of a ventriculostomy (opening CSF pressure 19 mm Hg), the patient was admitted to the neurologic intensive care unit. Five days after admission, a tracheostomy was performed under local anesthesia. Continuous cerebrospinal fluid drainage was necessary to maintain ICP below 20-25 mm Hg. Three days later the patient was scheduled for a ventriculo-peritoneal cerebrospinal fluid shunt. At the time of the shunt procedure his neurologic status had stabilized. He remained comatose, with a bilateral decerebration response to painful stimuli. His pupils were pinpoint and non-reactive to light, corneal reflexes were intact, and there was no response to caloric testing.

* Resident.

† Associate Professor of Anesthesia/Neurosurgery.

Received from the Departments of Anesthesia and Surgery (Neurosurgery), University of California, San Diego, California. Accepted for publication September 20, 1976. Supported in part by the Medical Research Service of the Veterans Administration.

Address reprint requests to Dr. Shapiro: Anesthesia Research—151, Veterans Administration Hospital, 3550 La Jolla Village Drive, San Diego, California 92161.

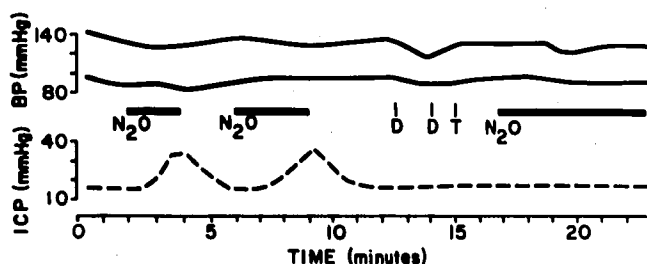


FIG. 1. Blood pressure (BP) and intracranial pressure (ICP) responses to repeated administration of 70 per cent nitrous oxide (N₂O). The patient was paralyzed and ventilated with 100 per cent oxygen prior to and between administrations of N₂O. Diazepam (D) was administered in divided doses of 15 and 5 mg, respectively. Thiopental (T), 150 mg, was given once.

In the operating room, following placement of a brachial blood pressure cuff and attachment of the tracheostomy tube to a semiclosed circuit of an anesthesia machine, the patient's ICP was measured by connecting the ventriculostomy tubing to an electronic pressure transducer. End-tidal CO₂ was continuously determined by a Beckman LBII CO₂ analyzer through a 100-cm length of low-deadspace tubing inserted into the tracheostomy tube.

The patient was then given 10 mg of pancuronium bromide and ventilated with 100 per cent oxygen at a constant frequency of 12 with a tidal volume of 1,100 ml. Following 10 minutes of stabilization ICP was 15 mm Hg, blood pressure 139/96 mm Hg, and end-tidal CO₂ 31 mm Hg. Figure 1 depicts the changes in ICP and blood pressure that occurred thereafter. Within 60 seconds following the introduction of nitrous oxide in oxygen into the breathing circuit (7 l N₂O + 3 l O₂), ICP increased. When ICP had risen to about 35 mm Hg, the breathing gas was abruptly switched to 100 per cent oxygen. Shortly thereafter, ICP returned to its baseline value of 15 mm Hg. This cycle was repeated on a second exposure to nitrous oxide.

Diazepam (20 mg) and thiopental (150 mg) were

administered iv to induce anesthesia and followed by nitrous oxide administration. The expected nitrous oxide-induced increase in ICP did not occur over the next 6 minutes of observation. At that time the ventriculostomy was removed and the operation proceeded. During the observation illustrated in figure 1, no change in the end-tidal CO₂ occurred.

DISCUSSION

The qualitative effects of anesthetic drugs on intracranial pressure can be predicted from knowledge of the particular drugs' effects on cerebral blood flow (CBF) and cerebrovascular resistance.³ Drugs such as halothane, which reduce cerebrovascular resistance and elevate CBF, will tend to increase ICP in patients who have reduced intracranial compliance due to space-occupying lesions. Agents with an opposite action on the cerebral vasculature, e.g., thiopental, have the potential for reducing already elevated ICP.

Although the data describing the effects of nitrous oxide on cerebral blood flow in man and animals are contradictory,⁴ the reproducibility and rapid reversal of the intracranial hypertension due to nitrous oxide in our patient suggest that the ICP increase was the result of cerebral vasodilation and augmentation of cerebral blood volume.

While the potency and direction of the CBF effects of certain anesthetic drugs are known, there are few data describing the interactions of these drugs in the same patient. Clinical studies of ICP changes in neurosurgical patients indicate that thiopental can reduce intracranial hypertension caused by halothane or ketamine.^{5,6} Our observations in the present patient indicate that prior administration of diazepam and thiopental can block the effect of nitrous oxide on ICP. These findings parallel those obtained in cerebral blood flow studies in volunteers in whom anesthetic induction with thiopental resulted in lower CBF during nitrous oxide anesthesia than that found in persons not receiving the barbiturate.⁴ Because diazepam and thiopental both reduce cerebral blood flow and increase cerebrovascular resistance,^{7,8} it is possible that they synergistically oppose the action of nitrous oxide on intracranial hemodynamics. However, diazepam premedication (10 mg) given an hour prior to anesthesia in a series of neurosurgical patients did not prevent increases in ICP due to subsequent exposure to nitrous oxide.² While the respective contributions of diazepam and thiopental in modifying the ICP response to nitrous oxide in our patient remain speculative, it is clear that interaction of drugs with opposing effects on cerebrovascular resistance occurs. This is similar to the recognized ability of hypocapnia to counteract the ICP, and presumably the cerebral blood flow, effects of halothane and nitrous oxide.^{2,9}

Our findings in this case indicate need for a better understanding of the interactive effects of various combinations of drugs on cerebral blood flow and metabolism. Additionally, they confirm that the sequence in which drugs are administered to neurosurgical patients is important.^{2,9} Nitrous oxide should not be administered to patients who have the potential for developing intracranial hypertension unless hyperventilation has been established and/or anesthesia already induced with drugs known to increase cerebrovascular resistance. However, the effectiveness of drugs or hyperventilation in modifying an ICP response to a cerebral vasodilatory stimulus in an individual patient remains largely unpredictable. This is due to a set of complex, largely unknown, and often antagonistic pathologic and pharmacologic influences on cerebral vessel tone. For instance, in our patient, modest hyperventilation to an end-expired P_{CO₂} of 31 mm Hg did not block an increase in ICP caused by nitrous oxide. More profound hyperventilation might have been potent enough to prevent the increase. Despite these theoretical problems, hyperventilation and other attempts to reduce ICP prior to exposure of the patient to cerebral vasodilator stimuli remain sound neuro-anesthetic practice. Finally, we emphasize that the administration of "light" nitrous oxide anesthesia to an already comatose patient can increase ICP.

REFERENCES

1. Laitinen LV, Johansson GG, Tarkkanen L: The effect of nitrous oxide on pulsatile cerebral impedance and cerebral blood flow. *Br J Anaesth* 39:781-785, 1967
2. Henriksen HT, Jorgensen PB: The effect of nitrous oxide on intracranial pressure in patients with intracranial disorders. *Br J Anaesth* 45:486-492, 1973
3. Shapiro HM: Intracranial hypertension: Therapeutic and anesthetic considerations. *ANESTHESIOLOGY* 43:445-471, 1975
4. Smith AL, Wollman H: Cerebral blood flow and metabolism. *ANESTHESIOLOGY* 36:378-400, 1972
5. Shapiro HM, Galindo A, Wyte SR, et al: Rapid intraoperative reduction of intracranial pressure with thiopentone. *Br J Anaesth* 45:1057-1062, 1973
6. Shapiro HM, Wyte SR, Harris AB: Ketamine anesthesia in patients with intracranial pathology. *Br J Anaesth* 44:1200-1204, 1972
7. Maekawa T, Sakabe T, Takeshita H: Diazepam blocks cerebral metabolic and circulatory responses to local anesthetic-induced seizures. *ANESTHESIOLOGY* 41:389-391, 1974
8. Pierce EC Jr, Lambertsen CJ, Deutsch S, et al: Cerebral circulation and metabolism during thiopental anesthesia and hyperventilation in man. *J Clin Invest* 41:1664-1671, 1962
9. Adams RW, Gronert GA, Sundt TM, et al: Halothane, hypocapnia, and cerebrospinal fluid pressure in neurosurgery. *ANESTHESIOLOGY* 37:510-517, 1972