

Anesthesiology
46:155-157, 1977

Hemodynamic Alterations and Rapid Diagnosis in a Case of Amniotic-fluid Embolus

RAYMOND H. M. SCHAEFER, M.D.,* TERUEL DE CAMPO, M.D.,† JOSEPH M. CIVETTA, M.D.‡

Amniotic-fluid embolus (AFE), first reported by Meyer in 1926,¹ continues to be a significant cause of postpartum morbidity and mortality. A report

* Chief Resident, Department of General Surgery, Jackson Memorial Hospital and Veterans Administration Hospital.

† Fellow, Intensive Care Unit, Jackson Memorial Hospital.

‡ Associate Professor of Surgery, Anesthesiology and Medicine, University of Miami School of Medicine; Director, Intensive Care Center, Jackson Memorial Hospital—University of Miami Medical Center.

Received from the Departments of Surgery, Anesthesiology and Medicine, University of Miami School of Medicine; and Departments of Surgery and Anesthesiology, Veterans Administration Hospital, Miami, Florida. Accepted for publication August 29, 1976.

Address reprint requests to Dr. Civetta: University of Miami School of Medicine, Department of Surgery, P.O. Box 520875, Miami, Florida 33152.

listed this disease as the cause of 10 per cent of 1,400 maternal deaths.² The definitive diagnosis is usually made only at postmortem examination.³⁻⁹ The diagnosis is usually made on clinical grounds. Amniotic-fluid embolus must be differentiated from other syndromes (Mendelson's syndrome, pulmonary embolus secondary to venous thrombosis, air embolus from the uterus, allergic reaction to local anesthetics).^{5-7,10-16,22-26}

Mortality has been attributed to development of disseminated intravascular coagulation in 40 per cent of cases.^{5,10,14-20} Other causes of death are anaphylaxis with circulatory collapse and right heart failure with pulmonary hypertension secondary to massive tamponade blockade.^{5,6,13,15,18,19,21-23}

This case illustrates a rapid and unequivocal method for making the diagnosis of AFE.

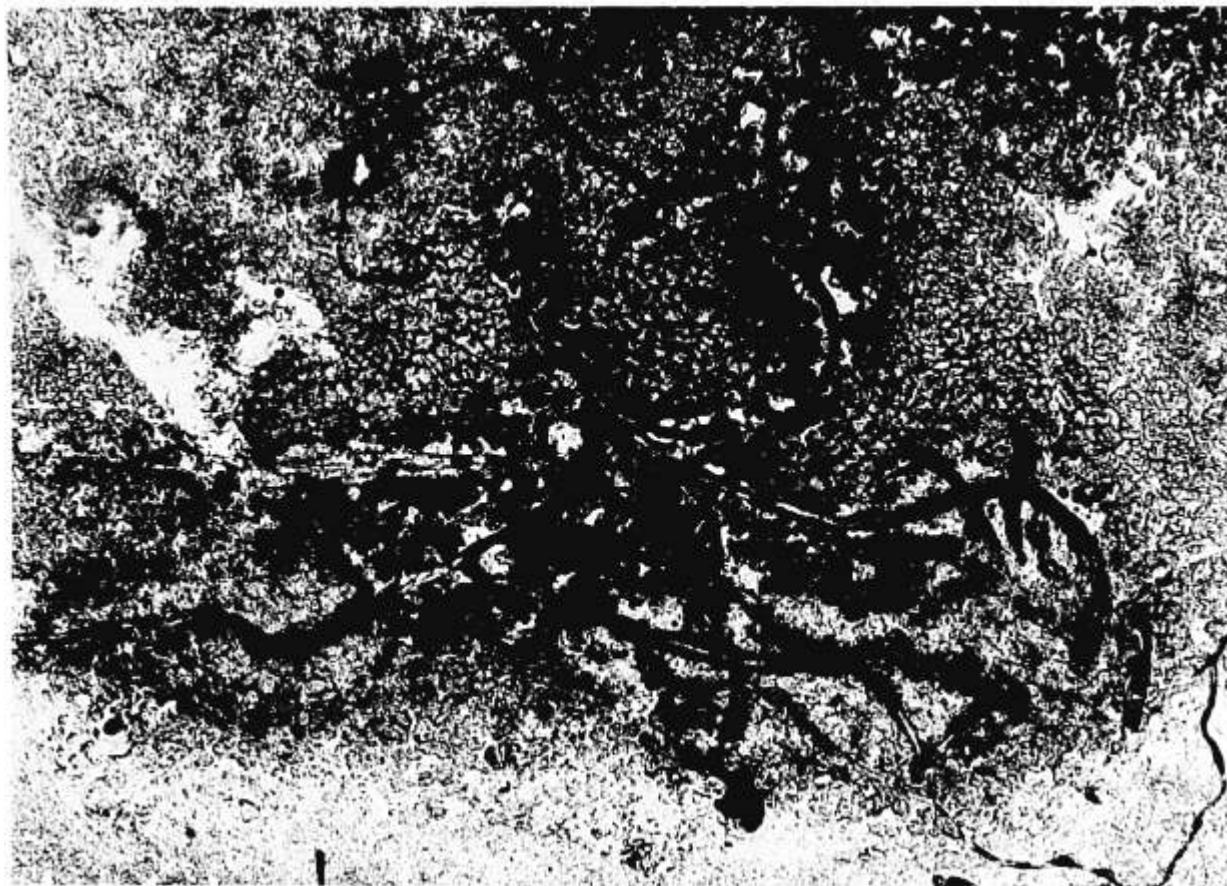


FIG. 1. Direct smear of blood aspirated from right atrium via percutaneously placed central venous catheter. Note lanugo. Fetal squamae were also demonstrated in thinner smears.

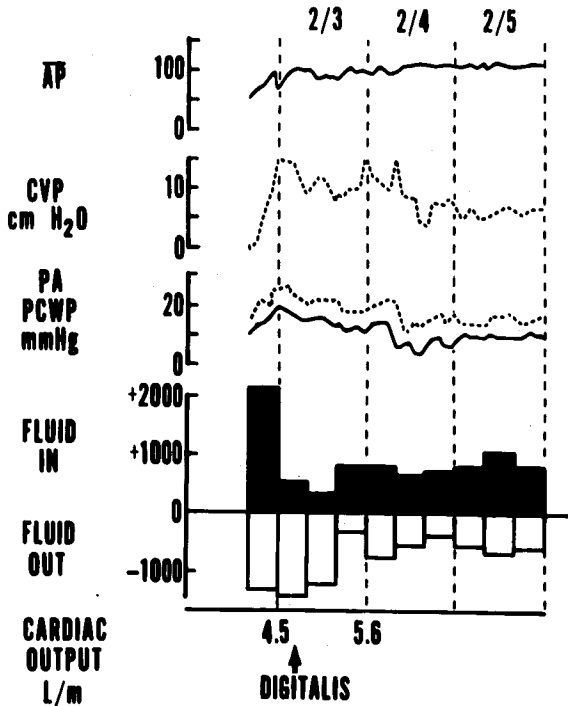


FIG. 2. Summary of initial course in the intensive care unit. Note rapid development of increasing pulmonary capillary wedge pressure despite modest positive fluid balance. The response to diuretic and cardiac glycoside caused a decline in PCWP, an increase in cardiac output, and negative fluid balance.

REPORT OF A CASE

The patient, a 22-year-old primigravida, presented to the Emergency Room of Jackson Memorial Hospital with onset of labor. Fetal age was estimated to be 44 weeks. Fetal heart sounds were not audible, and fetal death was suspected.

Amniotomy produced thick, meconium-stained fluid. Complete blood count and fibrinogen screen (more than 100 mg/100 ml) disclosed no abnormality. A specimen of blood clotted in 3 min. Oxytocin (Pitocin) infusion was started, but contractions were poor. Shortly thereafter, the patient accidentally removed her uterine pressure catheter. Because the patient was uncomfortable, a paracervical block with bupivacaine, 0.25 per cent, 10 ml, was performed, and the amniotic-fluid pressure catheter was reinserted. Immediately after this the patient experienced sudden flushing, a temperature of 38.7°C with shaking chills, and shortness of breath. The systolic blood pressure fell from 110 to 60 torr and pulse rate increased to 160/min. Two diagnoses were considered: an anaphylactic reaction to the local anesthetic, or an episode of amniotic-fluid embolus. The patient received two iv injections of 0.3 mg epinephrine, without clinical improvement. Concomitantly, a central venous pressure catheter was inserted via the right subclavian vein and a smear of aspirated right heart blood revealed lanugo and fetal squamatae (fig. 1), confirming a diagnosis of amniotic-fluid embolus. The patient was given 10,000 U heparin, iv, and intravenous fluids, and was taken to the operating room.

Preanesthetic blood pressure was 160/80 torr. The trachea was intubated and anesthesia was induced (after administration of 3 mg *d*-tubocurarine, iv, and antacids and cricoid pressure) with thiopental, 250 mg, and succinylcholine, 100 mg. Anesthesia was maintained with N₂O, 60 per cent and fentanyl, 0.1 mg. Muscle relaxation was accomplished with a succinylcholine infusion (150 mg). Induction was eventful, but systolic blood pressure fell to 65 torr 10 min later. After ephedrine, 5 mg, iv, blood pressure returned to 120/70 torr. A cesarean section was performed and a stillborn fetus delivered. Total anesthesia time was 35 minutes. After operation, the patient was ventilated with a respirator equipped for intermittent mandatory ventilation (IMV) and positive end-expiratory pressure (PEEP) because of the severity of the clinical picture and anticipated development of primary pulmonary complications. A pulmonary-artery catheter was inserted. Results of fibrinogen screening were normal (>100 mg/100 ml) and protamine sulfate and ethanol gelation tests were negative. No further heparin was administered. Three blood transfusions were necessary due to continued bleeding from an atonic uterus.

The patient's initial course in the intensive care unit is summarized in figure 2. On the evening after operation, central venous pressure (CVP) was 9 cm H₂O, mean pulmonary arterial pressure (PAP) 20 torr, pulmonary capillary wedge pressure (PCW), 14 torr, and cardiac output (CO), 5.8 l/min; roentgenograms of the chest were normal, with no rales. Eight hours later, recorded values were CVP 15 cm H₂O, PAP 27 torr, PCW 19 torr, and CO 4.5 l/min. Urinary output was reduced, and examination of wedge pressure tracings revealed a pattern consistent with mitral regurgitation (fig. 3). The diagnosis of left heart failure was made and rapid digitalization was undertaken (1.5 mg digoxin administered iv in 8 hours). A small dose (10 mg) of furosemide was also administered. Two hours after the last dose of digoxin, CVP was 13 cm H₂O, PAP 17 torr, PCW 5 torr, and CO 5.6 l/min. The pattern of mitral regurgitation disappeared

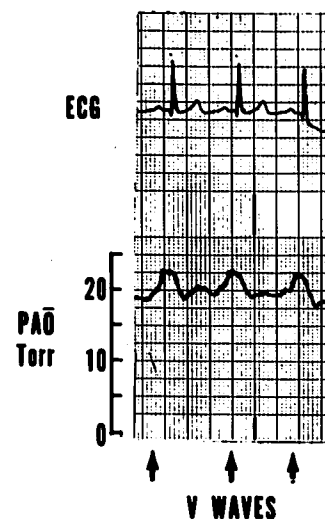


FIG. 3. Simultaneous electrocardiographic and pulmonary arterial pressure tracing. With the balloon inflated, V-waves consistent with mitral regurgitation were seen.

from the wedge tracing. The patient was kept on maintenance digitalis and made an uneventful recovery. She was discharged from the hospital on the tenth postoperative day.

DISCUSSION

The diagnosis of amniotic-fluid embolus in the living patient is rarely made on the basis of anything but presumptive evidence.^{5-7,10-16,22-26} Fetal squame have been recovered in the maternal sputum,^{21,22} but this has been infrequent. Definitive diagnosis has been confined to postmortem examination.⁵⁻⁹

The ability to make a rapid, unequivocal diagnosis of amniotic-fluid embolus in the living patient allows institution of appropriate therapy. Examination of an aspirate of blood from the right heart has been used to establish a diagnosis as an alternative to autopsy.¹² In the present case, aspiration of blood from a central venous pressure catheter permitted demonstration of lanugo and fetal squamae. This made the diagnosis apparent and facilitated early therapy.

Heparin was administered as soon as the diagnosis was made¹⁵ because disseminated intravascular coagulation is present in 40-50 per cent of the patients who survive the first hour following amniotic-fluid embolus.²⁰

A normal chest x-ray has been observed previously^{14,15} despite a clinically severe picture. A possible explanation could be the absence of macroscopic pulmonary lesions, demonstrated at autopsy.⁸

Although the studies of hemodynamic alterations in amniotic-fluid embolus are few,¹³ those reported include evidence of right-heart strain, pulmonary hypertension, and right heart failure.^{5,6,13,15,16,19,21-23} Use of a pulmonary-artery catheter in this patient differentiated theoretical right heart failure secondary to pulmonary capillary mechanical blockade and the actual development of left heart failure that responded to digitalization and diuresis. No underlying cardiac disease was found. The ability to make a rapid, unequivocal diagnosis of amniotic-fluid along with aggressive hemodynamic monitoring and appropriate therapy allowed this patient to make a quick, uneventful recovery.

REFERENCES

1. Meyer JR: Embolia pulmonar amino-caseosa. *Brasil Med* 2:301-303, 1926
2. Peterson EP, Taylor HB: Amniotic fluid embolism: An analysis of 40 cases. *Obstet Gynecol* 35:787-793, 1970

3. Huaman A, Nice W, Young I: Cryostat test for fat embolism. *Lab Med* 2:37-42, 1971
4. Huaman A, Nice W, Merkel RL, et al: Amniotic fat embolism. New laboratory diagnosis and a case presentation. *J Kans Med Soc* 73:441-443, 1972
5. Roche WD Jr, Norris HJ: Detection and significance of maternal pulmonary amniotic fluid embolism. *Obstet Gynecol* 43:729-731, 1974
6. Schmid J, Stadelmann U: Zur Fruchtwasserembolie. *Geburtshilfe Frauenheilk* 33:130-132, 1973
7. Mandelli P: L'embolia amniotica: Studio di cinque casi. *Folio Hered Pathol (Milano)* 19:11-28, 1970
8. Attwood HD: Amniotic fluid embolism. *Pathol Annu* 7:145-172, 1972
9. Attwood HD: Fatal pulmonary embolism by amniotic fluid. *J Clin Pathol* 9:38-46, 1956
10. Cornu P, Morin P, Engleman P, et al: L'embolie amniotique. *Sem Hop Paris* 49:1441-1448, 1973
11. Aquilini E, Fiorentino F: Sulla diagnosi precoce di embolia di liquido amniotico. *Minerva Ginecol* 23:891-894, 1971
12. Gross P, Benz EJ: Pulmonary embolism by amniotic fluid, report of 3 cases with new diagnostic procedure. *Surg Gynecol Obstet* 85:315-320, 1947
13. Scott MM: Cardiopulmonary consideration in nonfatal amniotic fluid embolism. *JAMA* 183:989-993, 1963
14. Gregory MC, Clayton EM Jr: Amniotic fluid embolism. *Obstet Gynecol* 42:236-244, 1973
15. Chung AF, Merkatz IR: Survival following amniotic fluid embolism with early heparinization. *Obstet Gynecol* 42:809-814, 1973
16. Slunsky R: Untersuchungen uber die Hemmung der thromboplastischen Wirkung des Fruchtwassers mit Trasylol. *Gynaekol Rundsch* 13:147-152, 1973
17. Dagasso D: L'embolia amniotica. Attuali conceetti fisiopatogenetici e clinico-terapeutici. *Minerva Ginecol* 26:282-288, 1974
18. Spence MR, Mason KG: Experimental amniotic fluid embolism in rabbits. *Am J Obstet Gynecol* 119:1073-1078, 1974
19. Monsallier JF, Hayat JC: L'embolie amniotique. *Poumon Coeur* 28:545-552, 1972
20. Andersen DG: Amniotic fluid embolism: A re-evaluation. *Am J Obstet Gynecol* 98:336-348, 1967
21. Tuck CS: Amniotic fluid embolus. *Proc R Soc Med* 65:94-95, 1972
22. Zipser G: Amniotic fluid embolism. *Med J Aust* 2:953-956, 1971
23. Abouleish E: Amniotic fluid embolism: Report of a fatal case. *Anesth Analg (Cleve)* 53:549-553, 1974
24. Harbison RG: Amniotic fluid embolism. *Med J Aust* 2: 687-688, 1973
25. Hewitt SR: Maternal mortality—Amniotic fluid embolism successfully treated. *J Ir Med Assoc* 66:50, 1973
26. Lucas WE, Jackson ND: Maternal mortality in U.S. Naval hospitals. *Obstet Gynecol* 32:60-69, 1968