

Clinical Reports

BURNELL R. BROWN, JR., M.D., Ph.D., *Editor*

Anesthesiology
46:290-291, 1977

Speaking Tracheostomy Tube Modified for Swallowing Dysfunction and Chronic Aspiration

MOHAMMAD B. G. SHAHVARI, M.D.,* COLLEEN M. KIGIN, R.P.T.,† JACK E. ZIMMERMAN, M.D.‡

Patients who have had tracheostomy, surgical operations on the head and neck, or cranial nerve damage often manifest swallowing dysfunction and continual laryngeal aspiration.¹⁻³

Treatment includes a cuffed tracheostomy tube, tube feeding, and physical therapy, but recovery is often delayed by excessive secretions and recurrent aspiration pneumonia. We have modified the speaking tracheostomy tube§ developed by Safar and Grenvik⁴ and report here its usefulness as an adjunct in the management of such patients.

METHODS

The speaking tracheostomy tube has been described elsewhere.⁴ It is unique by virtue of a rigid, narrow-gauge pilot tube ending above the cuff. A short plastic apron protects its interior opening, while the outside end is normally connected via a Y piece to a gas-flow meter. When the open port of the Y is manually occluded, the device is intended to divert 4-6 l/min gas flow above the cuff and through the larynx, allowing the patient to speak with a hoarse whisper.

We have modified the speaking tracheostomy tube (fig. 1) by cutting the protective apron from the interior opening. The outside end is attached to strong intermittent or moderate (60-100 torr) constant suction. The nursing staff is instructed to irrigate the pilot tube with 5 ml sterile saline solution if obstruction occurs.

When swallowing results in laryngeal aspiration, secretions are immediately removed by the pilot

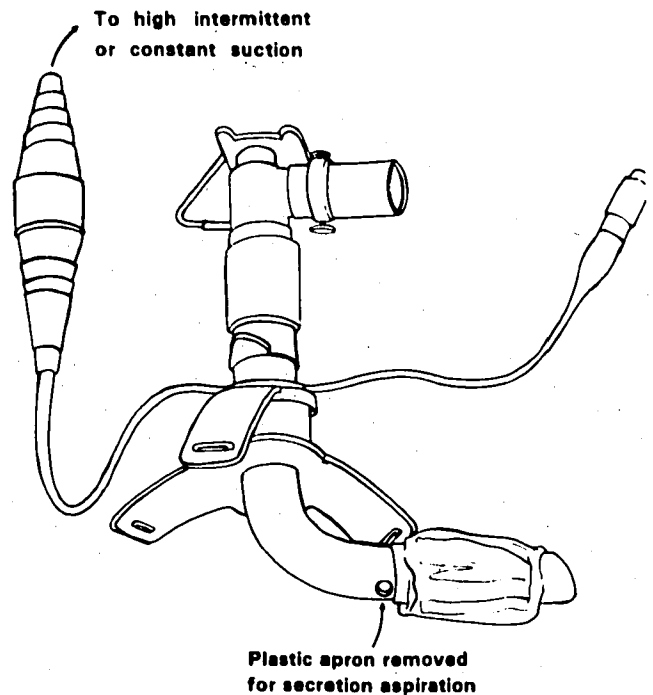


FIG. 1. Speaking tracheostomy tube modified by removing protective apron and attaching pilot tube to suction.

tube. During physical rehabilitation, the therapist utilizes the pilot tube to evaluate the extent of aspiration of food and liquids.

RESULTS

We have used our modification of the speaking tracheostomy tube in six patients who had swallowing dysfunction. Three patients had dysfunction from neurologic disorders, two following surgical operations on the head and neck, and one patient appeared to have dysfunction related to tracheostomy. Despite the presence of a cuffed tracheostomy tube, five patients had copious tracheobronchial secretions and two had recurrent atelectasis, pulmonary infiltrates, and fever. Methylene blue-stained water placed in the oropharynx immediately appeared at the tracheostomy stoma in all patients, and often appeared in tracheal secre-

* Assistant Professor of Anesthesiology and Pharmacology and Associate Director, Intensive Care Unit.

† Chest Physiotherapist.

‡ Associate Professor of Medicine and Director, Intensive Care Unit.

Received from the Departments of Medicine and Anesthesiology, Division of Intensive Care Medicine, The George Washington University School of Medicine, Washington, D. C. Accepted for publication November 8, 1976.

Address reprint requests to Dr. Shahvari: The George Washington University Medical Center, 901 23rd Street, N.W., Washington, D. C. 20037.

§ National Catheter Corporation, Catalog Number 39702-39700.

tions from below the inflated cuff. Excessive and often purulent secretions surrounded the tracheostomy stoma, and the amount frequently increased during swallowing. These findings persisted despite antibiotic therapy and adequate oropharyngeal and tracheobronchial toilet.

When the cuffed tracheostomy tube was replaced by the modified speaking tracheostomy tube, methylene blue-stained water was immediately recovered via the pilot tube after swallowing. Constant or intermittent suction removed 200–600 ml of secretions via the pilot tube per day. Removed secretions progressively diminished in amount and purulence. Within 72 hours of placement, there were reductions in body temperature, volume of tracheal secretions, and clearing of infiltrates in most patients.

Two patients died during their hospitalization; the others gradually recovered their ability to swallow. The speaking tracheostomy tube served as a guide during physical rehabilitation, since the severity of swallowing dysfunction and aspiration were immediately apparent. We encountered no apparent adverse effect from the applied suction in these patients.

DISCUSSION

In patients who have incompetent laryngeal function, saliva or anything that is swallowed is aspirated into the larynx and trachea. Such a patient needs a cuffed tracheostomy tube, tube feeding, and prolonged nursing care. Permanent deficits may necessitate surgical closure or diversion of the larynx,⁵⁻⁷ but the dysfunction is often temporary, and functional rehabilitation is possible in many patients.^{2,8}

A cuffed tracheostomy tube offers a less-than-adequate solution to the problem of laryngeal aspiration. The tube itself anchors the normally mobile trachea and larynx, diminishing excursion. This effect can cause or aggravate swallowing dysfunction.³ Although they clearly protect the patient from massive lethal aspiration, cuffed tracheostomy tubes offer incomplete protection from lesser extents of

aspiration. Cameron *et al.*⁹ detected aspiration in 69 per cent of patients who had tracheostomies, and suggested that this might result in pulmonary complications. We attribute our patients' considerable morbidity from recurrent bronchopneumonia, atelectasis, bronchitis, and upper-airway infection to repeated aspiration.

The improvement of our patients' conditions following use of the modified speaking tracheostomy tube suggests that removal of secretions immediately after laryngeal aspiration has a favorable effect on pulmonary complications. In most of our patients the swallowing dysfunction eventually was resolved despite the continued presence of the tracheostomy tube. The ability to detect and quantify laryngeal aspiration was useful during rehabilitation and in determining when extubation was possible.

REFERENCES

1. Conley JJ: Swallowing dysfunctions associated with radical surgery of the head and neck. *Arch Surg* 80:92–102, 1960
2. Larsen GL: Conservative management for incomplete dysphagia paralytica. *Arch Phys Med Rehabil* 54:180–185, 1973
3. Bonanno PC: Swallowing dysfunction after tracheostomy. *Ann Surg* 174:29–33, 1971
4. Safar P, Grenvik A: Speaking cuffed tracheostomy tube. *Crit Care Med* 3:23–26, 1975
5. Montgomery WW: Surgical laryngeal closure to eliminate chronic aspiration. *N Engl J Med* 292:1390–1391, 1975
6. Lindeman RC: Diverting the paralyzed larynx: A reversible procedure for intractable aspiration. *Laryngoscope* 85:157–180, 1975
7. Habal MB, Murray JE: Surgical treatment of life-endangering chronic aspiration pneumonia: Use of an epiglottic flap to the arytenoids. *Plast Reconstruct Surg* 49:305–311, 1972
8. Tribble WM: The rehabilitation of deglutition following head and neck surgery. *Laryngoscope* 77:518–523, 1967
9. Cameron JL, Reynolds J, Zuidema GD: Aspiration in patients with tracheostomies. *Surg Gynecol Obstet* 136:68–70, 1973