

## Prinzmetal's Variant Angina in the Immediate Postanesthetic State

REUBEN C. BALAGOT, M.D.,\* HENRY SELIM, M.D.,† VALERIE R. BANDELIN, M.D.,‡  
BING K. KWAN, M.D.,† BERNARD ECANOW, PH.D.§

Variant angina pectoris, which was first described as a clinical entity by Prinzmetal *et al.*,<sup>1</sup> may be diagnosed only electrocardiographically by the presence of an ST-segment elevation in an area supplied by a major coronary artery. There may not be an associated history of chest pain. The probable cause of the syndrome is coronary spasm.<sup>2,3</sup> This case report deals with such a syndrome, which to the best of our knowledge has never been reported to occur in association with the anesthetic state.

## REPORT OF A CASE

A 45-year-old white, male patient was scheduled for hemorrhoidectomy with spinal anesthesia. Past history included: 1) a non-psychotic organic brain syndrome from alcoholism, in remission; 2) angina pectoris with left chest and sternal pain involving the left upper arm at times, but without evidence of myocardial infarction, treated with nitroglycerin; 3) rheumatic fever during childhood, with no sequelae; 4) hemorrhoids.

Physical findings and laboratory examinations disclosed no abnormality.

On the day of operation, the patient was given 2 ml nalbuphine as premedication, and an hour later, hyperbaric spinal anesthesia employing 8 mg tetracaine was administered. The patient was then placed in the jack-knife position and tested for extent of analgesia. Analgesia was found to extend to S2, with hypalgesia demonstrable to L3.

Anal dilatation, however, produced pain. The anesthesiologist administered 50 mg ketamine, 5 mg diazepam, and 0.4 mg atropine, iv. Incision of the skin provoked more pain, and additional ketamine was given in increments of 50 mg until the patient was asleep. The total dose of ketamine was 200 mg, and spontaneous respiration was supplemented with a gaseous anesthetic mixture of N<sub>2</sub>O, 3 l/min, and O<sub>2</sub>, 2 l/min.

The course of the anesthesia during the surgical procedure was uneventful except for slight tachycardia observed on the oscilloscopic monitor with incision of the skin, just before ketamine administration. At the end of the surgical procedure, O<sub>2</sub>, 5 l/min was given for 5 minutes. The anesthesiologist believed that respiration had been adequate throughout the course of anesthesia.

The patient was taken to the recovery room and re-attached to an EKG monitor. The ST segment was noticeably elevated, and a direct-writing EKG was hooked in tandem to the oscilloscope to record all 12 leads (fig. 1). The Cardiology Service was called for consultation. The significant EKG findings were ST segment elevations in leads I, II, III, AVF, and V6. The initial impression was antero-inferior ischemia. Closer scrutiny also revealed a small Q wave in AVL, but it was barely noticeable in lead I, which made lateral involvement a possibility.

Arterial blood gases determined at the time of the episode showed slight metabolic acidosis: pH 7.285, P<sub>CO<sub>2</sub></sub> 41.7 torr, P<sub>O<sub>2</sub></sub> 383.3 torr, HCO<sub>3</sub> 19.3 mEq, and base excess -6.9 mEq. This was corrected with iv bicarbonate. The next blood-gas determination, 30 minutes later, showed no abnormality.

The patient was transferred to the coronary care unit and another EKG, 30 minutes after the initial episode, was almost within normal limits, except for a barely discernible Q wave in leads I and V6, and a questionable ST elevation in lead II. Results of enzyme studies (SGOT, LDH, CPK) were normal, indicating absence of myocardial infarction. Follow-up EKG's on the fourth and sixth days after the attack indicated resolving acute infero-lateral-wall myocardial injury with ischemia. Enzymes continued to remain normal. The patient was discharged from the hospital 21 days after the episode, and was treated with isosorbide dinitrate for occasional anginal attacks.

## DISCUSSION

Classic angina pectoris is usually associated with emotional stress or exercise, whereas Prinzmetal's variant occurs at rest and causes transient ST segment elevation.<sup>4</sup> It has been known to occur during the light (rapid eye movement) phase of sleep.<sup>5</sup> This case is unique in that the attack occurred during a phase of anesthesia that corresponds to the period of recovery from general anesthesia.

The most frequent EKG findings, ST segment elevations in leads II, III, and AVF, usually signify antero-inferior-wall ischemia. Ischemia in this area is associated with spasm or stenosis with

\* Chairman and Professor.

† Assistant Professor.

‡ Vice Chairman and Associate Professor.

§ Professor, University of Illinois, College of Pharmacy, Chicago, Illinois.

Received from the Departments of Anesthesiology, North Chicago Veterans Administration Hospital and the Chicago Medical School, Chicago, Illinois 60612. Accepted for publication December 8, 1976.

Opinions expressed in this paper do not represent the Veterans Administration policy and are strictly those of the authors.

Address reprint requests to Dr. Balagot: Department of Anesthesiology, Chicago Medical School, 2020 West Ogden Avenue, Chicago, Illinois 60612.

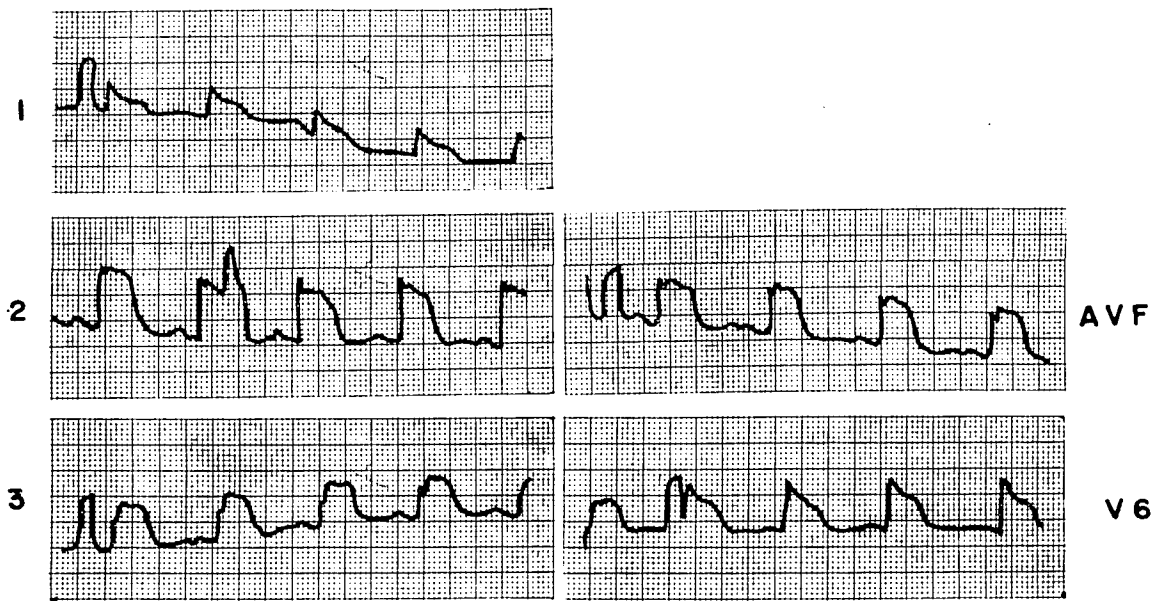


FIG. 1. Marked ST segment elevations in leads I, II, III, AVF, and V6 (see text for explanation).

spasm of the right coronary artery. Other frequent EKG findings are elevated ST segments in leads I, AVL, and V4-6. This relates to spasm or stenosis of the left circumflex artery or left anterior descending coronary artery.<sup>6</sup> In this report, a Q wave in leads I, AVL, and V6 represented lateral-wall involvement. Coronary spasm is the main precipitating factor, and has since been demonstrated in angiographic studies of the coronary arteries in patients who have this condition.<sup>3</sup> There is usually a history of angina in these cases, but the angina is not related to stress or exertion.

Coronary angiography frequently demonstrates normal right and left coronary arteries. When stenosis is seen, the right coronary artery is usually involved, although it is also observed in the circumflex and the left anterior descending arteries—not necessarily in that order. Although cyclic pain in the chest unrelated to effort is one of the classic features of Prinzmetal's description of the syndrome, there have recently been reports of patients who have ST segment elevation without such pain—a notable dissociation between EKG findings and symptoms.<sup>7</sup>

In three of ten patients studied by Yasue *et al.*<sup>6</sup> who manifested EKG and angiographic signs of the disease, subcutaneous administration of methacholine provoked EKG changes within 6-14 minutes after injection. Epinephrine and propranolol also induced attacks in these patients, whereas phenoxybenzamine and atropine prevented attacks. Isoproterenol and Master's triple two-step test failed to precipitate an attack despite marked tachycardia, and eliminated oxygen demand as a factor.

Innervation of the coronary arteries is both sympathetic and parasympathetic. Vagal stimulation or intracoronary acetylcholine injection causes coron-

ary dilatation by direct action on the vessel wall.<sup>8,9</sup> The large coronary arteries are, however, supplied with alpha-adrenergic receptors,<sup>10</sup> and there is evidence that acetylcholine provokes the release of norepinephrine from the postganglionic sympathetic nerve terminals in the coronary vessels. Although this is not normally a dominant effect, and may be demonstrated experimentally only after beta-adrenergic receptor blockade,<sup>11</sup> its occurrence under certain circumstances is highly probable. Present knowledge of coronary-artery pharmacology suggests that Prinzmetal's variant angina is provoked by predominantly cholinergic and related alpha-adrenergic receptor mechanisms.

In the management of angina, one of the more useful drugs is nitroglycerin. The patient reported has had occasional anginal attacks that were treated with nitroglycerin. The most probable reasons for Prinzmetal's variant angina in the immediate post-operative period, when the patient was still in the immediate post-anesthetic recovery state, were: 1) failure to take nitroglycerin at any time before the operation; 2) omission of atropine as part of the preoperative medication; 3) inadequate spinal anesthesia.

For preanesthetic management of patients who have Prinzmetal's variant angina, it is suggested that nitroglycerin or similar drugs be continued. It is further recommended that larger doses of atropine be given for premedication. In prolonged surgical procedures, atropine may have to be repeated.

The greatest danger of Prinzmetal's variant angina during anesthesia or operation is the frequent possibility of imminent, fatal myocardial infarction.<sup>12</sup> Cardiac monitoring should be routine in these situations no matter how brief the exposure of the patient to anesthesia.

REFERENCES

1. Prinzmetal M, Kennamer R, Merliss R, et al: Angina pectoris: I. A variant form of angina pectoris. *Am J Med* 27:375-388, 1959
2. Prinzmetal M, Ekmekci A, Kennamer R, et al: Variant form of angina pectoris. Previously undelineated syndrome. *JAMA* 174:1794-1800, 1960
3. Oliva PB, Potts DE, Pluss RG: Coronary arterial spasm in Prinzmetal angina. Documentation by coronary arteriography. *N Engl J Med* 288:745-751, 1973
4. Epstein SE, Redwood DR, Goldstein RE, et al: Angina pectoris: Pathophysiology, evaluation and treatment. *Ann Intern Med* 75:263-296, 1971
5. Nowlin JB, Troyer WG Jr, Collens WS, et al: The association of nocturnal angina pectoris with dreaming. *Ann Intern Med* 63:1040-1046, 1965
6. Yasue H, Touyama M, Shimamoto M, et al: Role of autonomic nervous system in the pathogenesis of Prinzmetal's variant form of angina. *Circulation* 50:534-539, 1974
7. Kossowsky WA, Mohr BD, Summers DM, et al: Further variant patterns within Prinzmetal angina pectoris. *Chest* 66:622-627, 1974
8. Blumenthal MR, Wang HH, Markee S, et al: Effects of acetylcholine on the heart. *Am J Physiol* 214:1280-1287, 1968
9. Levy MN, Zieske H: Comparison of the cardiac effects of vagus nerve stimulation and of acetylcholine infusions. *Am J Physiol* 216:890-897, 1969
10. Bohr DF: Adrenergic receptors in coronary arteries. *Ann NY Acad Sci* 139:799-807, 1967
11. MacRaven DR, Mark AL, Abboud FM, et al: Responses of coronary vessels to adrenergic stimuli. *J Clin Invest* 50:773-778, 1971
12. Silverman ME, Flamm MD Jr: Variant angina pectoris: Anatomic findings and prognostic implications. *Ann Intern Med* 75:339-343, 1971

Anesthesiology  
46:357-359, 1977

## Catheterization after Long- and Short-acting Local Anesthetics for Continuous Caudal Block for Vaginal Delivery

L. DONALD BRIDENBAUGH, M.D.\*

Bupivacaine (Marcaine®) has been advocated for continuous caudal obstetrical anesthesia because its long duration of action (3-4 hours or more) necessitates few, if any, "refills." Avoidance of subsequent doses decreases potentials for complications such as total spinal block, inadvertent intravascular injection, tachyphylaxis, or a systemic toxic reaction from high blood levels of local anesthetic drug.<sup>1</sup> However, obstetricians and nurses attending these patients after they left the post-delivery room criticized its use because "the patients *all* have to be catheterized post-delivery." A review of the hospital records of the last 100 obstetric patients was conducted to determine the incidence of catheterization. All had continuous (fractional dose) caudal anesthesia with 0.5 per cent bupivacaine. Of these 100 patients, 74 had been catheterized at least once. This was markedly higher than the 32 per cent reported in studies<sup>2</sup> using shorter-acting local anesthetic drugs. Therefore, a prospective study was conducted comparing the incidences of post-delivery bladder catheterizations when a short-acting drug, 2 per cent 2-chloroprocaine (Nesacaine®), and a long-acting drug, 0.5 per cent bupivacaine, were used as the local anesthetic drugs for continuous caudal anesthesia. The two variables to be compared were the in-

cidences of catheterizations and/or urinary tract infections.

### METHOD OF STUDY

Two hundred consecutive patients scheduled for routine vaginal delivery under continuous caudal anesthesia were studied. All were classified as ASA physical status I. To eliminate bias during the period of study, selection of patients was randomized. Postpartum nursing personnel were unaware which local anesthetic drug had been used. One hundred patients received 2-chloroprocaine and 100 received bupivacaine utilizing a standard caudal technique.<sup>1</sup> Because there was no way to anticipate which patient would deliver within the time afforded by a single-dose technique, caudal catheters were inserted in all patients. All patients received 1,000 ml 5 per cent dextrose in lactated Ringer's solution iv during labor and were catheterized at the time of delivery. One hundred seventy-four infants were delivered by forceps.

### RESULTS

Postpartum care nurses catheterized 22 of the 100 patients receiving 2-chloroprocaine once, and four twice. Sixty-three bupivacaine patients were catheterized one time and 15, two or more times. Three patients who received bupivacaine and two who received 2-chloroprocaine had urinary tract infections and positive urine cultures after de-

\* Staff Anesthesiologist, The Mason Clinic, 1100 Ninth Avenue, Seattle, Washington 98101.

Accepted for publication December 12, 1976.

Address reprint requests to Dr. Bridenbaugh.