

Anesthesiology
46:362-364, 1977

A New Approach to Percutaneous Catheterization of the Internal Jugular Vein

TADIKONDA L. K. RAO, M.D.,* ALFONSO Y. WONG, M.D.,† M. R. SALEM, M.D.‡

Central venous catheterization is a commonly employed technique. Because of disadvantages of cut-downs and inaccessibility of certain veins, various percutaneous approaches utilizing antecubital,¹ external jugular,² and subclavian veins have been described.³⁻⁴ The high failure rate with antecubital¹ or external jugular⁵ approaches and the high complication rate with subclavian-vein puncture made cannulation of the percutaneous internal jugular vein an attractive alternative, especially in management of pediatric patients.

Three approaches for percutaneous IJV cannulation have been described, all utilizing the sternocleidomastoid muscle as a landmark.⁶ In this report, a new approach is described, based on the consistent finding in children and adults of an easily identifiable notch located just above the medial end of the clavicle (fig. 1).

The notch is bounded medially by the upward-curving projection of the sternal end of the clavicle and inferiorly by its superior surface. From studies of 12 fresh cadavers, we found that a needle introduced into this notch, just above the clavicle, .25 to 1 cm lateral to its sternal end, and advanced caudally parallel to the sagittal plane, at 30 to 40 degrees with the coronal plane, punctured the internal jugular vein as it passes under the medial end of the clavicle, being separated from it by the sternohyoid muscle, before it joins the subclavian vein (fig. 2).

TECHNIQUE

Catheterization of the internal jugular vein using this approach has been attempted in a total of 316 anesthetized patients, including 192 pediatric patients between the ages of 21 days and 12 years. The procedure was performed by either senior residents rotating in cardiovascular and thoracic anesthesia or the attending physicians. All patients were undergoing cardiothoracic operations. Depending upon the age of the patient, and 8-inch Deseret Intracath of appropriate gauge was selected.

* Associate Director, Adult Anesthesiology.

† Director, Pediatric Anesthesiology.

‡ Associate Chairman, Department of Anesthesiology, Cook County Hospital, and Professor of Anesthesiology, Loyola University Stritch School of Medicine, Maywood, Illinois.

Received from the Department of Anesthesiology, Cook County Hospital, 1825 West Harrison Street, Chicago, Illinois 60612. Accepted for publication December 18, 1976. Presented at the annual meeting of the American Society of Anesthesiologists, Chicago, May 1975.

Address reprint requests to Dr. Rao.

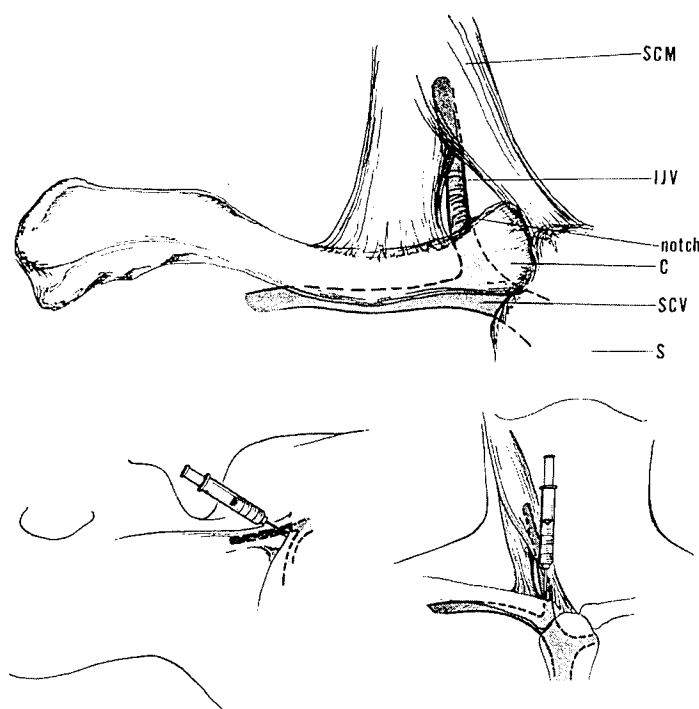


FIG. 1(above). Location of bony landmark "notch." C = clavicle; IJV = internal jugular vein; S = sternum; SCM = sternocleidomastoid; SCV = superior vena cava.

FIG. 2(below). Angle of the needle; 30-40 degrees to the coronal plane (left) and parallel to the sagittal plane (right).

For infants three months old or less, a 22-gauge catheter with a 19-gauge needle was used; for patients 4 months to 6 years old, a 19-gauge catheter with a 17-gauge needle was used; for patients more than 6 years old, a 16-gauge catheter with a 14-gauge needle was preferred.

Using general endotracheal anesthesia, with both arms to the sides, each patient was placed in the 25-degree Trendelenburg position. The neck was slightly extended by placing a small rolled towel under the shoulders while the head was turned away from the site of puncture. The Intracath needle was disconnected from the unit and connected to a 5-ml syringe. The patient was ventilated manually by an assistant to avoid hyperinflation of lungs during the puncture. Under sterile conditions, after the notch was identified with the left thumb, the skin was pierced just above the notch with the bevel of the needle facing medially. The needle was advanced caudally parallel to the sagittal plane but at a 30-40-degree angle to the

coronal plane. Puncture of the internal jugular vein at a depth of 2 to 4 cm was signaled by a click. An initial click, due to piercing of the well-developed cervical fascia, was usually felt in adult patients. Puncture of the internal jugular vein was confirmed by aspiration of blood.

When blood could not be aspirated, the needle was redirected at the same angle to the coronal plane but in a slightly lateral direction to the sagittal plane. Once blood was aspirated, the needle was carefully stabilized while disconnecting the syringe and the catheter was threaded through the needle, which was finally withdrawn. After the stylet was removed and the intravenous line connected, the catheter was withdrawn so that the tip was at the level of the second sternocostal junction, which corresponded to the junction of the superior vena cava and right atrium. This was done by measuring the catheter with the stylet placed externally. The patient was then placed in the supine horizontal position and the accuracy of the catheter's position was confirmed by oscillations of the water level in the manometer with respiratory and cardiac cycles.⁷ The catheter was finally fixed to the skin with silk sutures. Successful placement of the catheter was also verified by the surgeon during thoracotomy and by a chest x-ray postoperatively in every patient.

RESULTS

The age distribution of the patients and sites of catheterization are shown in table 1. In the pediatric age group, successful catheterization on the first attempt was obtained in 180 patients (94 per cent), while a second attempt on the same side resulted in success in eight additional patients (4 per cent) (total success rate 97 per cent). Catheterization was successful in 117 of 124 adult patients (94 per cent) on the first attempt, and the second attempt resulted in success in six more patients (5 per cent) (total success rate 99 per cent).

Six complications were encountered in this series. Pneumothorax developed in one patient. The thoracic duct was punctured in two patients when catheterization of the left internal jugular vein was attempted. Accidental arterial puncture occurred in three patients.

DISCUSSION

Despite the multiplicity of techniques that have been described for catheterization of the internal jugular vein, they fall into three basic approaches in relation to the sternocleidomastoid muscle, namely, posterior, central, and anterior routes. With all these techniques, the anatomic landmark is the sternocleidomastoid muscle and its two heads. With this new approach utilizing the notch as a landmark, there is no need to rely on the anatomy of

TABLE 1. Age Distribution and Sites of Catheterizations

Age	Site		Total
	Right	Left	
1-30 days	6	0	6
1 month-1 year	39	3	42
2-5 years	61	6	67
6-11 years	75	2	77
12 years old or older	112	12	124
Total	293	23	376

the sternocleidomastoid muscle, which may not be easily identified in anesthetized small children and obese patients.

The failure rate in this series was 1 per cent. In a series of 100 cases using the central approach, Daily *et al.*⁸ encountered a failure rate of 9 per cent. English⁸ devised a technique where the internal jugular vein was palpated prior to cannulation. However, in his series of 352 cases, the vein could not be palpated in 130 patients, and the failure rate was 20 per cent. Failure to cannulate the internal jugular vein in four pediatric patients in our series could have been related to severe kyphoscoliosis in two and the presence of total anomalous venous drainage in the other two patients. In one adult patient, the presence of a retrosternal mass might have contributed to the failure of cannulation.

The complication rate in our series was 2 per cent. Puncture of the thoracic duct in two patients could have been avoided if the right internal jugular vein had been cannulated instead of the left. Right-sided cannulation is preferable because of the absence of the thoracic duct, the short straight course of internal jugular vein to the right atrium, and the low level of the cupula of the pleura. Arterial puncture in three patients resulted in the formation of small hematomas, with no serious sequelae. The incidence of accidental arterial punctures was higher in children in Daily's series.⁸ Pneumothorax and hydrothorax have been also reported to occur.⁹

It appears that with this new approach to catheterization of the internal jugular vein, both failure and complication rates are less than with other techniques. This may be due to the ease and reliability of identifying a constant bony landmark in relation to the course of the internal jugular vein. Although pneumothorax was encountered in one instance, it is our belief that this could be eliminated by strict adherence to the technique. It is concluded that, utilizing the approach described, cannulation of the internal jugular vein could be successfully carried out in a higher proportion of cases, especially in children, than is achieved with other available techniques.

REFERENCES

1. Webre DR, Arens JF: Use of cephalic and basilic veins for introduction of central venous catheters. *ANESTHESIOLOGY* 38:389-392, 1973.
2. Blitt CD: Central venous catheterization via the external jugular vein: A technique employing the J wire. *JAMA* 229:817-818, 1974
3. Aubaniac R: L' injection intraveineuse sans claviculaire: Avantages du technique. *Presse Med* 60:1456, 1952
4. Borja AR: Current status of infraclavicular subclavian vein catheterization. *Ann Thorac Surg* 13:615, 1972
5. Jemigan WR, Gardner WC, Mahr MM, et al: Use of the internal jugular vein for placement of central venous catheter. *Surg Gynecol Obstet* 130:520-524, 1970
6. Defalque RJ: Percutaneous catheterization of the internal jugular vein. *Anesth Analg (Cleve)* 53:116-121, 1974
7. Salem MR, Yacoub MH, Holaday DA: Interpretation of central venous pressure measurements. Common and uncommon problems in Anesthesiology. *Clinical Anesthesia Series*, 1969
8. Daily PO, Griep RB, Shumway NE: Percutaneous internal jugular vein cannulation. *Arch Surg* 100:534-536, 1970
9. English DCW, Frew RM, Pigott JJ: Percutaneous catheterization of the internal jugular vein. *Anaesthesia* 24:521-531, 1969

Anesthesiology
46:364-365, 1977

Physostigmine Reversal of Benzquinamide-induced Delirium

JAMES W. CHAPIN, M.D.,* AND DANIEL W. WINGARD, M.D.†

There have been numerous reports recently concerning the use of physostigmine in reversal of central anticholinergic syndromes produced by drugs with anticholinergic properties. Benzquinamide, first introduced as a tranquilizer (Quantril®) and now used as an antiemetic agent (Emete-con®), has anticholinergic properties.¹ This is a case report demonstrating the successful reversal of benzquinamide-induced delirium by physostigmine.

REPORT OF A CASE

A healthy, 61-kg, 18-year-old girl was scheduled for diagnostic laparoscopy for evaluation of intermittent abdominal pain. She was taking no medication and had no allergies. Laboratory and x-ray findings were all within normal limits. At 0745 she was premedicated with diazepam, 5 mg, meperidine, 100 mg, and atropine 0.4 mg, iv. At 0800 anesthesia was induced and maintained for one hour with a total of 440 mg thiopental, 15 mg meperidine, and N₂O:O₂, 4:2 l. A 0.2 per cent succinylcholine drip was used for tracheal intubation and muscle relaxation during the procedure. The patient was awake, coherent, and cooperative in the recovery room. At 0915 she complained of nausea without vomiting and received 25 mg benzquinamide as a single dose, iv. Within minutes, the patient complained of "feeling funny," became progressively delirious, and developed involuntary jerking movements of the head and arms. Although the muscular activity appeared similar to an acute dystonic extrapyramidal reaction, the delirium suggested a central anticholinergic syndrome rather than an extrapyramidal reaction. A single dose of physostigmine, 1 mg, was given iv over 1 minute, with clearing of the symptoms in 1-2 minutes. The symptoms did not recur, and the patient had an uneventful recovery.

* Assistant Professor, Department of Anesthesiology, University of Nebraska Medical Center, Omaha, Nebraska 68105.

† Professor and Chairman, Department of Anesthesiology, University of Nebraska Medical Center, Omaha, Nebraska 68105.

Accepted for publication December 18, 1976.

Address reprint requests to Dr. Wingard.

DISCUSSION

Benzquinamide is a benzoquinolizine derivative that is chemically unrelated to the phenothiazines or to other antiemetics. It was originally introduced as an anti-anxiety drug in the early 1960's and more recently has been used as an antiemetic agent. Side-effects of the drug include antihistaminic,¹ anticholinergic,¹ bronchodilating,¹ pressor,² respiratory stimulant,³ and extrapyramidal effects.⁵

This case report represents a central nervous system reaction to benzquinamide that was successfully reversed by physostigmine. Since physostigmine is a tertiary amine that readily crosses the blood-brain barrier, it is useful to reverse the central anticholinergic syndrome. It is thought to do this because of its anticholinesterase properties, although it has been suggested that physostigmine reversal of coma and sedation by tranquilizers may be due to a more generalized analeptic phenomenon.⁴ Since benzquinamide has anticholinergic properties and the phenomenon that was seen in this patient was reversed by physostigmine, it is likely that the problem in this patient was the central anticholinergic syndrome.

Benzquinamide has been reported to cause dystonic extrapyramidal reactions reversible by diphenhydramine.⁵ Patients who have this syndrome improve when given anticholinergic drugs and become worse when given an anticholinesterase such as physostigmine.

Thus, benzquinamide, in common with many other tranquilizers, may have two different CNS side-effects upon the patient. The circumstances that cause the central anticholinergic response to a tranquilizer in one patient and the dystonic extrapyramidal reaction in another are not clear. Normal central nervous system control appears to involve a balance between cholinergic and dopaminergic systems. When a drug depresses the dopaminergic