

itself, produce reflex cardiovascular stimulation.<sup>9</sup> Thus, the use of moderate levels of anesthesia with meticulous airway management and good muscle relaxation to facilitate intubation is a reasonable approach to the anesthetic management of these patients. The choice of relaxant, however, must also be appropriate for the patient.

Pancuronium bromide has vagolytic properties and is reported to produce 20–50 per cent increases in heart rate when administered during halothane anesthesia.<sup>11</sup> These findings are consistent with our observations. Pancuronium did not produce a significant increase in blood pressure. However, in our study the reported preintubation blood pressures were purposely maintained at comparable levels in the two groups by the use of halothane. The vagolytic properties of pancuronium seem to exaggerate the sympathetic response to intubation, which increases myocardial oxygen demand.

Metocurine iodide in intubated patients during halothane–N<sub>2</sub>O anesthesia has been found to be without significant cardiovascular effects when administered iv in doses of 0.2 mg/kg.<sup>4</sup> This study demonstrates that metocurine iodide, compared with pancuronium in the clinical setting described, is also associated with less increase in myocardial oxygen demand. For this reason we believe metocurine is especially useful for management of patients who have minimal cardiac reserves, in whom increases in heart rate and blood pressure should be minimized. Additional study of the effects of anesthetic techniques on myocardial TTI (oxygen demand) should point toward further improvements in management of the high-risk patient who has coronary-artery disease.

Anesthesiology  
46:368–370, 1977

## Anesthesia for Repair of a Pulmonary-artery Sling in an Infant with Severe Tracheal Stenosis

CHARLES H. MCLESKEY, M.D.,\* AND WAYNE E. MARTIN, M.D.†

The combination of pulmonary-artery sling and severe tracheal stenosis has been reported three times previously. This paper reports the only known survivor to date with this combination of congenital defects.

\* Resident.

† Associate Professor.

Received from the Department of Anesthesiology and the Anesthesia Research Center, University of Washington School of Medicine, Seattle, Washington 98195. Accepted for publication January 5, 1977.

Address reprint requests to Dr. McLeskey: Department of Anesthesiology, Naval Regional Medical Center, Oakland, California 94627.

## REFERENCES

1. Bland JHL, Lowenstein E: Halothane-induced decrease in experimental myocardial ischemia in the non-failing canine heart. *ANESTHESIOLOGY* 45:287–293, 1976
2. Sarnoff SJ, Braunwald E, Welch GH, et al: Hemodynamic determinants of the oxygen consumption of the heart with special reference to the tension–time index, *Work and the Heart*. Edited by FF Rosenbaum, EL Belknap. New York, Paul B. Hoeber, Inc., 1959, pp 18–33
3. Stoelting RK: The hemodynamic effects of pancuronium and *d*-tubocurarine in anesthetized patients. *ANESTHESIOLOGY* 36:612–615, 1972
4. Stoelting RK: Hemodynamic effects of dimethyltubocurarine during nitrous oxide–halothane anesthesia. *Anesth Analg (Cleve)* 53:513–515, 1974
5. Bonchek LI, Rahimtoola SH, Anderson RP, et al: Late results following emergency saphenous vein bypass grafting for unstable angina. *Circulation* 50:972–977, 1974
6. Miller DC, Cannon DS, Fogarty TJ, et al: Saphenous vein coronary artery bypass in patients with “preinfarction angina.” *Circulation* 47:234–241, 1973
7. Vatner SF, Smith NT: Effects of halothane on left ventricular function and distribution of regional blood flow in dogs and primates. *Circ Res* 34:155–167, 1974
8. King BD, Harris LC, Greifenstein FE, et al: Reflex circulatory responses to direct laryngoscopy and tracheal intubation performed during general anesthesia. *ANESTHESIOLOGY* 12:556–566, 1951
9. Wycoff C: Endotracheal intubation: Effects on blood pressure and pulse rate. *ANESTHESIOLOGY* 21:153–158, 1960.
10. Dewling JK, Ellison N, Ominsky AJ: Effects of intratracheal lidocaine on circulatory responses to tracheal intubation. *ANESTHESIOLOGY* 41:409–412, 1974
11. Miller RD, Eger EI, Stevens WC, et al: Pancuronium-induced tachycardia in relation to alveolar halothane, dose of pancuronium, and prior atropine. *ANESTHESIOLOGY* 42:352–355, 1975

The infant's marked obstructive airway problem was thought to be due to both severe tracheal stenosis and a pulmonary-artery sling. It was decided to attempt definitive repair of the pulmonary-artery sling, since results of surgical correction of stenotic tracheas in infants are universally poor. A solution to the difficult problem of intraoperative and postoperative airway management utilizing a Cole‡ tube with amputated tip, positive end-expiratory pressure (PEEP), and systemic and topical steroids is described in this report.

‡ Cole endotracheal tube manufactured by Foregger Labs, Division of Air Products, Inc., Allentown, Pa. 18105.

REPORT OF A CASE

A 4-month-old black female infant was admitted for repair of a pulmonary-artery sling using general anesthesia. Immediately following birth of the infant, signs of respiratory distress, including tachypnea and noisy respiration, occurred, and these continued to the time of admission. Bronchoscopy and chest x-ray revealed severe tracheal stenosis extending from 1 cm below the vocal cords to the carina. On fluoroscopy this stenotic segment collapsed almost entirely during late exhalation and opened to its maximum diameter of 1 mm during inspiration. An anterior filling defect of the esophagus 1 cm above the carina was seen on barium esophagram. Cineangiography demonstrated this defect to be due to an anomalous left pulmonary artery, or pulmonary-artery sling (fig. 1).

Physical examination on the evening before operation revealed the patient to be small for her age, weighing 4.0 kg (<third percentile). Loud, coarse inspiratory and expiratory rhonchi were audible from across the room, with a resting respiratory rate of 35/min. Marked subcostal and suprasternal inspiratory retractions were present, as were bilateral, basilar râles and wheezes. Cardiac rhythm was regular at approximately 120/min, without murmur or gallop rhythm.

Laboratory values included hematocrit, 32 per cent, and heel-stick capillary blood-gas values of  $pH$  7.40,  $PO_2$  58 torr,  $PCO_2$  36 torr, and  $HCO_3^-$  27 mEq/l during breathing of room air.

The patient received atropine, 0.1 mg, im, 30 min prior to arrival in the operating suite. Anesthesia was induced with ether in oxygen by mask. Catheters were inserted in the left femoral artery and vein, permitting continuous measurement of arterial and inferior vena caval pressures. Other monitors included an EKG, precordial and esophageal stethoscopes, and a rectal thermistor probe. After administration of succinylcholine, 10 mg, iv, the trachea was intubated without difficulty with a #12 Cole tube coated with cortisone cream. The distal narrow portion of the Cole tube had previously been amputated, allowing it to extend only 3 mm beyond the tapered shoulder section of the tube. The tapered portion of the tube was gently wedged at the vocal cords; movement of the tube was prevented by packing the pharynx with wet gauze and by taping. The endotracheal tube was connected to a Bloomquist semiclosed circle absorber system and ventilation was manually controlled, with application of 5 to 10 torr PEEP for the entire operative procedure. Ventilation was easy despite a prolonged expiratory phase, with  $PCO_2$  maintained at 25–35 torr throughout the operation. Anesthesia was maintained with ether, 5–8 per cent, in oxygen. Following administration of pancuronium, 0.05 mg/kg, iv, to prevent shivering, the patient was cooled by immersion to a temperature of 21 C (rectal).

Surgical correction of the left pulmonary-artery sling was accomplished during a 24-minute period of cardiac arrest. Dexamethasone, 1 mg, iv, was given intraoperatively. Respiratory alkalosis,  $pH$  7.45–7.60, was main-

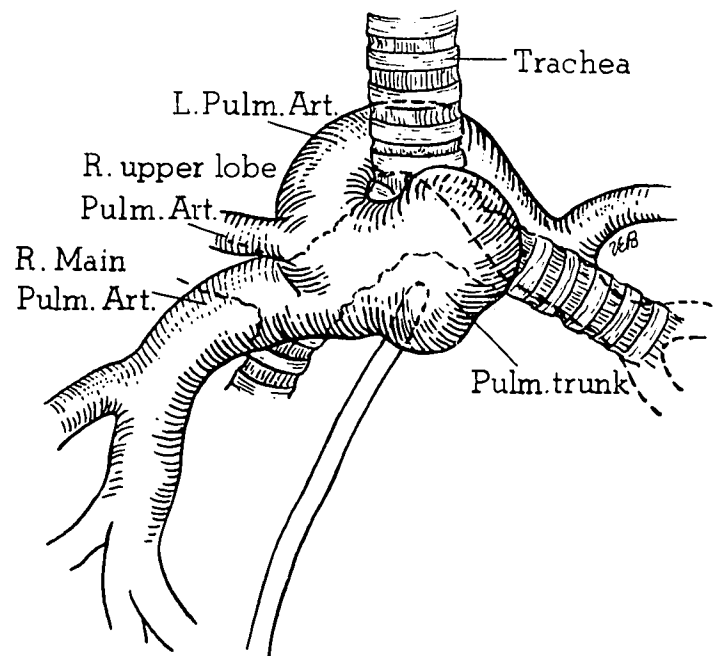


FIG. 1. Diagrammatic illustration and explanation of the pulmonary arterial bed as seen on cineangiography. The tip of the catheter for injection of radiographic dye was placed in the trunk of the pulmonary artery after traversing the right atrium and right ventricle. The left pulmonary artery arises from the posterior aspect of the right main pulmonary artery, traverses the right mainstem bronchus, turns posteriorly, and travels between the trachea and the esophagus, eventually terminating at the region of the left hilus. Note: Also, in this infant, the right-upper-lobe pulmonary artery originates aberrantly from the trunk of the left pulmonary-artery sling.

tained throughout the operation except for a short period of acidosis during cardiac arrest.

Following completion of the surgical procedure the patient was rewarmed by immersion to 35 C (rectal) and was taken to the intensive care unit. The endotracheal tube was left in place and the patient was ventilated with humidified 50 per cent oxygen at a corrected tidal volume of 25–35 ml and a rate of 25/min with 5 torr PEEP applied. Dexamethasone, 1 mg, iv, was given every six hours for four doses. The trachea was extubated 18 hours postoperatively; spontaneous respiration remained adequate despite the continued persistence of coarse inspiratory and expiratory rhonchi, which were slightly less obvious than preoperatively. The only postoperative complication was transient atelectasis of the right upper lobe. The patient was discharged from the intensive care unit three days postoperatively and sent home nine days later.

DISCUSSION

The anomalous left pulmonary artery was first described by Glaevecke and Doehle in 1897<sup>1</sup> and called a pulmonary vascular "sling" by Contro in 1958.<sup>2</sup> It arises from the posterior aspect of the right pulmonary artery, traverses the right mainstem

bronchus, turns posteriorly, and then travels between the trachea and the esophagus, eventually terminating at the region of the left hilus (fig. 1). The sling may cause obstruction of the right mainstem bronchus, the distal trachea, or rarely, the left mainstem bronchus. Symptomatic esophageal obstruction is rare. Previously, 70 cases of left pulmonary sling have been reported.<sup>1-10</sup> Mortality associated with the surgical repair has been approximately 50 per cent because of a high incidence of associated obstructive abnormalities of the tracheo-bronchial tree.

The surgical correction performed in this patient was transection and proximal ligation of the anomalous left pulmonary artery at its origin with distal reanastomosis to the main pulmonary artery anterior to the trachea.<sup>8</sup> The general anesthetic technique of deep hypothermia, ether, and respiratory alkalosis, as described by Mohri *et al.*,<sup>11</sup> was selected. This technique has been shown to provide cardiac stability with few arrhythmias while achieving profound hypothermia. Hypothermia to 21°C safely permits 45-60 minutes of cardiac arrest for delicate surgical repairs in infants too small to undergo cardiopulmonary bypass.

The stenotic segment of the trachea originated approximately 1 cm below the vocal cords, with the lumen thought to be too small to accommodate either an endotracheal tube or a tracheostomy tube. In order to minimize intraoperative and postoperative tracheal edema, especially in the stenotic region, an endotracheal tube that avoided any contact between it and the stenotic trachea was selected. Use of a relatively large truncated Cole tube provided an ample upper airway and permitted gentle wedging of the shoulder portion of the tube on the vocal cords. Since the distal narrow portion was amputated, allowing it to extend only 3 mm beyond the shoulder portion of the tube, no contact between the endotracheal tube and the stenotic trachea beyond was possible when the shoulder portion of the tube rested at the vocal cords. One hazard with the use of the Cole tube, however, is laryngeal edema resulting from pressure of the shoulder of the tube against the vocal cords. In this case, we accepted the risk in order to insure tube location.

Fluoroscopy showed that the tracheal lumen enlarged during inspiration and collapsed almost completely during late expiration. We therefore maintained 5-10 torr PEEP throughout the operative procedure and 5 torr PEEP during the early postoperative period while controlled ventilation of the patient was continued. Extubation was delayed postoperatively for 18 hours in the hope that surgically

induced tracheal edema would be somewhat decreased by that time.

Cortisone cream was applied to the outside of the endotracheal tube prior to its insertion, and dexamethasone was given intravenously during the operative period and for the first 24 hours postoperatively in an attempt to prevent laryngeal or tracheal edema. Otherson *et al.*<sup>12</sup> have shown that systemically administered corticosteroids are effective in reducing tracheal edema resulting from endotracheal intubation; however, the efficacy of topical steroids applied to endotracheal tubes has not been demonstrated.

This paper reports the only known survivor to date with the combination of pulmonary-artery sling and severe tracheal stenosis. One technique for the difficult anesthetic management of an individual with these or similar conditions is presented.

The authors thank Thomas F. Hombein, M.D., for critical review of the manuscript.

#### REFERENCES

1. Glaevecke H, Doehle T: Ueber eine seltene angeborene anomalie der pulmonalarterie. *Munchen Med Wochenschr* 44:950-960, 1897
2. Contro S, Miller RA, White H, et al: Bronchial obstruction due to pulmonary artery anomalies. *Circulation* 17: 418-423, 1958
3. Grover FL, Norton JB, Webb GE, et al: Pulmonary sling. *J Thorac Cardiovasc Surg* 69:295-300, 1975
4. Jue KL, Raghil G, Mapatz K, et al: Anomalous origin of left pulmonary artery from the right pulmonary artery. *Am J Roentgenol Radium Ther Nucl Med* 95:598-610, 1965
5. Koopot R, Nikaidoh H, Idriss FS: Surgical management of an anomalous left pulmonary artery causing tracheo-bronchial obstruction. *J Thorac Cardiovasc Surg* 69: 239-246, 1975
6. Nikaidoh H, Riker WL, Idriss FS: Surgical management of "vascular rings." *Arch Surg* 105:327-333, 1972
7. Niwayama G: Unusual vascular ring formed by the anomalous left pulmonary artery with tracheal compression. *Am Heart J* 59:454-461, 1960.
8. Potts WJ, Holinger DH, Rosenblum AH: Anomalous left pulmonary artery causing obstruction to right main bronchus: Report of a case. *JAMA* 155:1409, 1954
9. Sade RM, Rosenthal A, Fellows K, et al: Pulmonary artery sling. *J Thorac Cardiovasc Surg* 69:333-346, 1975
10. Tesler UF, Balsava RH, Niguidula FN: Aberrant left pulmonary artery: Report of five cases. *Chest* 66:402-407, 1974
11. Mohri H, Dillard DH, Crawford EW, et al: Method of surface induced deep hypothermia for open heart surgery in infants. *J Thorac Cardiovasc Surg* 58:262-270, 1969
12. Otherson HB Jr: The technique of intraluminal stenting and steroid administration in the treatment of tracheal stenosis in children. *J Pediatr Surg* 9:683-690, 1974