

### DISCUSSION

This scavenging system consists of Dupaco<sup>§</sup> valve (C), a disc valve (D) and a scavenging bag (B) connected to suction through a variable port or tap (E). The system is mounted on the expiratory limb of the anesthetic circuit.

Frequent adjustment of the valves (C and D) and the suction tap (E) is required. The disc valve (D) and the scavenging bag (B) are incorporated to act as a safety measure against excessive suction from the anesthetic circuit: the valve (D) is designed to open to room air should the pressure in the bag (B) fall.

In this case, valve D stuck in the closed position, admitting excessive negative pressure to the breathing system.

In such a situation, providing adequate minute volume depends upon equilibrium between the fresh gas inflow (FGI) and the suction. A slight change in any of the three components of this balance (increased uptake, reduced FGI, increased suction) could have affected the equilibrium. Closing the exhaust valve (C) or the suction tap (E) would have been equally illogical, preventing the collapse of the bag (B), but creating back-pressure in the circuit instead.

Disconnecting the bag (B) opened an alternative passage from the room to the suction, sparing the anesthetic circuit.

In this case the rebreathing bag (A) did not stay collapsed long enough to asphyxiate the patient, but this, however, is a possible hazard of the system.

The incorporation of this scavenging system into the anesthetic circuit, despite its potential benefits to the

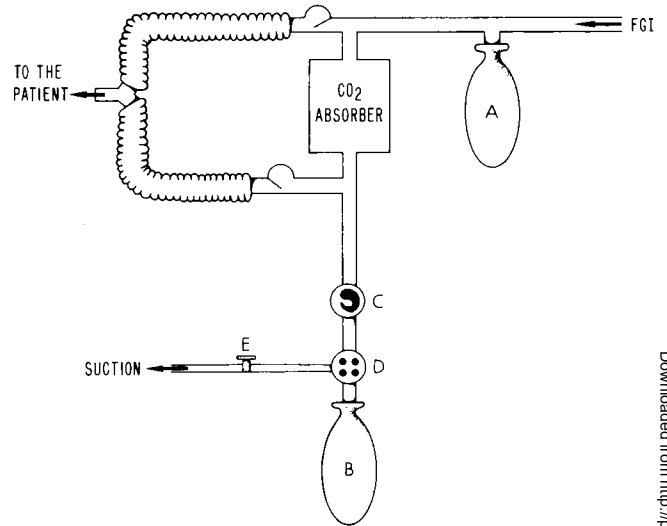


FIG. 1. Diagram of the circle-absorber anesthetic circuit, with a Dupaco Clean OR scavenging system mounted on the expiratory limb. A, rebreathing bag; B, scavenging reservoir bag; C, exhaust valve; D, disc valve (negative pressure relief, flexible flap type valve). FGI = fresh gas inflow.

personnel involved in caring for the patient, adds two additional hazards to the patient himself should gas flow and suction not be evenly matched: one is overdistention of the rebreathing bag, with ensuing increase of intrathoracic pressure and potential pulmonary rupture; the other is total collapse of the bag with the possibility of asphyxiation. It is clear that the use of such a system mandates increased vigilance on the part of the responsible anesthesiologist.

## Anesthesia for Ligation of the Hepatic Artery in a Patient with Carcinoid Syndrome

ARVIND U. PATEL, M.D.,\* RAYMOND MILLER, M.D.,† RICHARD R. P. WARNER, M.D.‡

Ligation of the hepatic artery, a well-recognized though controversial procedure, has been used for treatment of primary and secondary tumors of the liver. That this procedure might be useful as a palliative measure was first suggested by Markowitz in 1952.<sup>1</sup> Two years later, Breedis and Young demonstrated that the blood supply of malignant tumors

of the liver was derived almost exclusively from the hepatic artery.<sup>2</sup> Nilsson, in 1966, found that hepatic dearterialization led to necrosis of tumor cells in both animals and man.<sup>3</sup> More recently, the effects of ligation of the hepatic artery and its therapeutic value have been confirmed in an extensive study of the hepatic circulation by Madding and Kennedy.<sup>4</sup> Patients with carcinoid syndrome whose symptoms are severe and unresponsive to current medical therapy may benefit from hepatic dearterialization, and good results have been reported following the procedure.<sup>5</sup> The anesthetic management of such cases may be complex due to the high incidence of complications in carcinoid patients undergoing anesthesia and the inevitable severe hepatic dysfunction of the early post-

\* Resident in Anesthesiology.

† Associate Clinical Professor of Anesthesiology.

‡ Associate Clinical Professor of Medicine.

Received from the Departments of Anesthesiology and Medicine, Mount Sinai Medical Center of the City University of New York, Fifth Avenue and 100th St., New York, New York 10029. Accepted for publication April 12, 1977.

Address reprint requests to Dr. Miller.

TABLE 1. Laboratory Data, Ligation of the Hepatic Artery for the Carcinoid Syndrome

	Bilirubin, mg/100 ml (Normal 0.1-1)	SGPT, mu/ml (Normal 6-53)	SGOT, mu/ml (Normal 15-50)	Serum Serotonin, µg/ml (Normal 0.08-0.31)	Urinary 5-Hydroxyindole- acetic Acid, mg/24 hr Urine (Normal 2-8)
Preoperative	0.6	27	33	0.45	128
Postoperative					
Day 1	0.6	1,250	1,530		292
Day 2	0.7	2,170	1,480		
Day 3	1.5	1,965	775		
Day 4	0.7	965	287		
Day 5	0.8	835	185		
Day 6	0.8	603	106	0.30	
Day 7	0.8	410	62		
Day 8	0.9	369	57		
Day 9	0.8	303	89		210
Day 10	0.8	282	53	0.26	192
Day 11	0.8	188	53		
Day 12	0.8	193	49		

operative period. The paucity of information concerning anesthesia in the surgical literature pertaining to ligation of the hepatic artery for the carcinoid patient prompted the following case report.

#### REPORT OF A CASE

A 54-year-old white woman who had a four-year history of carcinoid syndrome was hospitalized in 1974 because of severe facial flushing, episodes of wheezing, chronic diarrhea, and weight loss. She had undergone uneventful appendectomy, oophorectomy and vaginal repair at the ages of 13, 34, and 45 years, respectively. A complete work-up to determine the primary site of the carcinoid tumor was unsuccessful. A liver scan was abnormal, but liver biopsy was noncontributory. The biopsy precipitated a carcinoid crisis; blood serotonin levels increased, and subsequent urinary 5-hydroxyindoleacetic acid (5-HIAA), indoleacetic acid, and histamine levels were all markedly elevated. Treatment with an intrahepatic arterial injection of yttrium administered via percutaneous hepatic-artery catheterization produced some clinical improvement, and the patient was discharged. For 18 months she was maintained on phentolamine, diphenoxylate hydrochloride, methysergide maleate, and nicotinic acid, but her condition gradually deteriorated. Chronic diarrhea and flushing were of such severity that she was readmitted for ligation of the hepatic artery. For three days immediately prior to operation the patient received a continuous intravenous infusion of fructose (10 per cent) to enhance glycogen storage in the liver; neomycin was administered orally for the same period.

Preoperatively, the patient weighed 96 pounds and had a marked purplish facial flush. The blood pressure was 120/80 torr; pulse rate was 80/min and regular. A grade II midsystolic murmur was audible over the left sternal border. The liver extended 6 cm below the right costal margin and was hard, nodular, and slightly tender.

EKG and chest x-ray were normal. Routine laboratory data were within normal limits, with the exception of the serum alkaline phosphatase, which was moderately elevated. Serum serotonin and urinary 5-HIAA levels were elevated (table 1).

Premedication consisted of secobarbital, 100 mg, and atropine, 0.4 mg, im, an hour before operation. In addition to routine monitoring aids, a no.-20 Teflon catheter was inserted into the right radial artery. Methotrimeprazine, a protonin and angiotensin amide were available in the operating room. Induction of anesthesia was

achieved with thiopental, 150 mg, and pancuronium, 6 mg. The larynx was sprayed with 4 ml of 4 per cent lidocaine, and endotracheal intubation was uneventful. Thereafter, anesthesia was maintained with nitrous oxide-oxygen (5:1:2 l) with increments of pancuronium (5 mg). The patient was mechanically ventilated throughout the two-hour procedure and moderate respiratory alkalosis was maintained.

Approximately 15 minutes after intubation, bronchospasm developed. Hydrocortisone, 200 mg, and aprotinin, 20,000 units were administered iv, with some improvement, but bronchospasm persisted. Aprotinin, 100,000 units, and hydrocortisone, 100 mg, were given iv during the next hour. During this period  $P_{aO_2}$  was well maintained, but moderate metabolic acidosis developed; this was corrected with sodium bicarbonate. The bronchospasm gradually diminished, and at the conclusion of the operation the chest was clear. Mean blood pressure was stable throughout in the range of 90-100 torr. Spontaneous respiration was easily re-established after reversal of neuromuscular blockade with atropine and prostigmine, but the patient easily tolerated the endotracheal tube. Despite responding to auditory stimuli, she appeared drowsy, and was transferred to the recovery room with the endotracheal tube in place. An hour later she was fully awake, her chest was clear on auscultation, and the endotracheal tube was removed. For the first two postoperative days she was given a continuous glucagon infusion to increase portal blood flow. Cephalothin was also administered for the same period.

During the first postoperative week the patient was psychotic for several days, and for three weeks she had severe postural hypotension. Bilirubin, SGOT and SGPT levels rose for a few days, but by the tenth postoperative day only SGPT remained elevated.

Urinary 5-HIAA remained elevated, but serum serotonin had returned to normal. Postoperative laboratory data are summarized in table 1.

Overall, the patient made a good recovery. She had severe fatigue for the first postoperative month, but this has gradually abated. Two months after operation she no longer flushes or wheezes and has normal bowel activity.

#### DISCUSSION

Complications during anesthesia in patients with the carcinoid syndrome occur frequently.<sup>6</sup> In a recent review, Mason and Steane found that hypotension,

bronchospasm, flushing, and hyperkinetic states of hypertension and tachycardia were common.<sup>6</sup> Carcinoid tissue may produce a variety of hormonal agents, including serotonin, bradykinins, lysyl bradykinins, histamine, ACTH, melanocyte-stimulating hormone, and insulin. Bronchospasm and hypotension are considered primarily due to the release of bradykinins.<sup>7</sup> Aprotinin, and possibly steroids, may be helpful both prophylactically and for the treatment of bradykinetic crises.<sup>7,8</sup> Should hypotension be severe and not respond to routine measures, angiotensin or methoxamine is the vasopressor of choice.<sup>9</sup> The hypertension associated with excessive serotonin release may be alleviated with methotrimeprazine, a potent antiserotonin agent.<sup>6</sup> Agents known to be associated with serotonin release, such as morphine, or histamine release, such as *d*-tubocurarine, should be avoided in carcinoid patients. The increase in intra-abdominal pressure occurring after succinylcholine may precipitate a crisis.<sup>10</sup> Hypotension alone may lead to a crisis, so regional anesthesia is not without problems.<sup>7</sup> Delayed recovery from anesthesia is associated with the carcinoid syndrome, possibly due to deranged serotonin metabolism<sup>11</sup>; drugs that have long durations of action should therefore be avoided. Cyproheptidine and droperidol have useful antiserotonin effects, but may lead to prolonged sedation. Following ligation of the hepatic artery, hepatic function is compromised, and it would seem desirable to avoid all agents known or suspected to have hepatotoxic effects. An anesthetic technique excluding all agents that may be associated with hypotension, tachycardia, serotonin or histamine release, disturbances of hepatic blood flow, or post-operative hepatic dysfunction is difficult to conceive. A barbiturate-pancuronium-nitrous oxide sequence, though not ideal, would seem the least provocative choice. Instances of histamine release following thiopental and pancuronium have been reported, but they are rare.<sup>12,13</sup>

The rapidity with which hepatic function recovers

following dearterialization is of interest, and may be related to the prompt development of collateral vessels via the phrenico-abdominal and intercostal arteries.<sup>14</sup> Chronic effects of hepatic dearterialization have not yet been fully investigated.

A thiopental-pancuronium-nitrous oxide sequence with moderate hyperventilation, avoiding the use of other agents, would seem to provide satisfactory anesthesia for carcinoid patients undergoing ligation of the hepatic artery.

#### REFERENCES

1. Markowitz J: The hepatic artery. *Surg Gynecol Obstet* 95:644-646, 1952
2. Breedis C, Young G: The blood supply of neoplasms in the liver. *Am J Pathol* 30:969-985, 1954
3. Nilsson LAV: Therapeutic hepatic artery ligation in patients with secondary liver tumors. *Rev Surg* 23:374-376, 1966
4. Madding GF, Kennedy PA: Hepatic artery ligation. *Surg Clin North Am* 52:179-727, 1972
5. Aune S, Schistad G: Carcinoid liver metastases treated with hepatic dearterialization. *Am J Surg* 123:715-717, 1972
6. Mason RA, Steane PA: Carcinoid syndrome: Its relevance to the anaesthetist. *Anaesthesia* 31:228-242, 1976
7. Déry R: Theoretical and clinical considerations in anesthesia for secreting carcinoid tumors. *Can Anaesth Soc J* 18:245-263, 1971
8. Cline MJ, Melmon KL: Plasma kinins and cortisol: A possible explanation of the anti-inflammatory action of cortisol. *Science* 153:1135-1137, 1966
9. Oates JA: The carcinoid syndrome. *Harrison's Principles of Internal Medicine*. Eighth edition. New York, McGraw Hill, 1977, pp 639-642
10. Anderson N: Changes in intragastric pressure following administration of suxamethonium. *Br J Anaesth* 34:363-366, 1962
11. Jouvet M: Biogenic amines and the states of sleep. *Science* 163:32-40, 1969
12. Brown TP: Thiopentone anaphylaxis—case report. *Anaesth Intens Care* 3:257-259, 1975
13. Buckland RW, Avery RF: Histamine release following pancuronium: A case report. *Br J Anaesth* 45:518-521, 1973
14. Bengmark S, Fredlund P, Hafström LO, et al: Present experiences with hepatic dearterialization in liver neoplasm. *Progr Surg* 13:141-166, 1974