

Anesthesiology
47:526, 1977

A Complication of Oropharyngeal Airway Placement

MICHAEL W. MOORE, LT., MC, USNR,* AND L. ANDREW RAUSCHER, M.B.B.S., F.F.A.R.C.S.†

Oropharyngeal airways are frequently used as airway adjuncts, both alone and in combination with tracheal intubation. We present a serious, yet previously undescribed, complication from an oropharyngeal airway in a small child.

REPORT OF A CASE

A 2-year-old 12-kg Mexican boy was admitted to the university hospital from a community hospital, semicomatose, with a diagnosis of tuberculous meningitis. Intracranial pressure rose progressively to 30 mm Hg despite continuous drainage of cerebrospinal fluid, osmotic diuresis, and steroid therapy. Twelve hours after admission tracheal intubation was accomplished with a 4.0-mm internal diameter uncuffed Portex tube, and mechanical hyperventilation was initiated. No sign of damage to the tongue was noticed at this time. Following endotracheal tube placement a lubricated #2 Berman oropharyngeal airway (manufactured from pure virgin polyethylene by Emergency Kit Corporation, New York) was inserted without trauma. The tube was secured with adhesive tape, which covered the mouth in such a way as to prevent the oropharyngeal airway from coming out. The airway was placed to prevent orotracheal tube occlusion and to protect the tongue during biting or seizure activity.

After eight days the patient was successfully weaned from mechanical support by progressive reduction of intermittent mandatory ventilation. On the tenth day after admission, the trachea was extubated without difficulty, but when the oropharyngeal airway was removed, brisk bleeding from the tongue was noticed. On examination there was an area of bleeding necrotic tissue in the midline of the tongue, 3 cm wide at its widest point, tapering to 1 cm, with a through-and-through 2 cm by 1 cm erosion in the midline of the tongue 1 cm from the tip (fig. 1). In three days the anterior 1 cm of the tongue sloughed, leaving the child with a well-healed but bifid tongue (fig. 2). The remainder of the tongue healed without residual disfigurement. Surgical repair of the bifid tip may be considered after further follow-up.

DISCUSSION

Fixation of an oropharyngeal airway in the mouth of a child for ten days during mechanical ventilation was associated with the development of pressure necrosis of the tongue and sloughing of the tip due to sustained pressure on the lingual mucosa by the airway and "trapping" of the anterior portion of the tongue between the teeth and the airway.

Such airways are used commonly in the operating room by anesthesiologists without significant sequelae.

* Resident, Department of Anesthesiology, Naval Regional Medical Center, San Diego, California 92134.

† Assistant Clinical Professor, Department of Anesthesiology, University of California Medical Center, 225 W. Dickinson Street, San Diego, California 92103.

Accepted for publication June 20, 1977.

Address reprint requests to Dr. Rauscher.

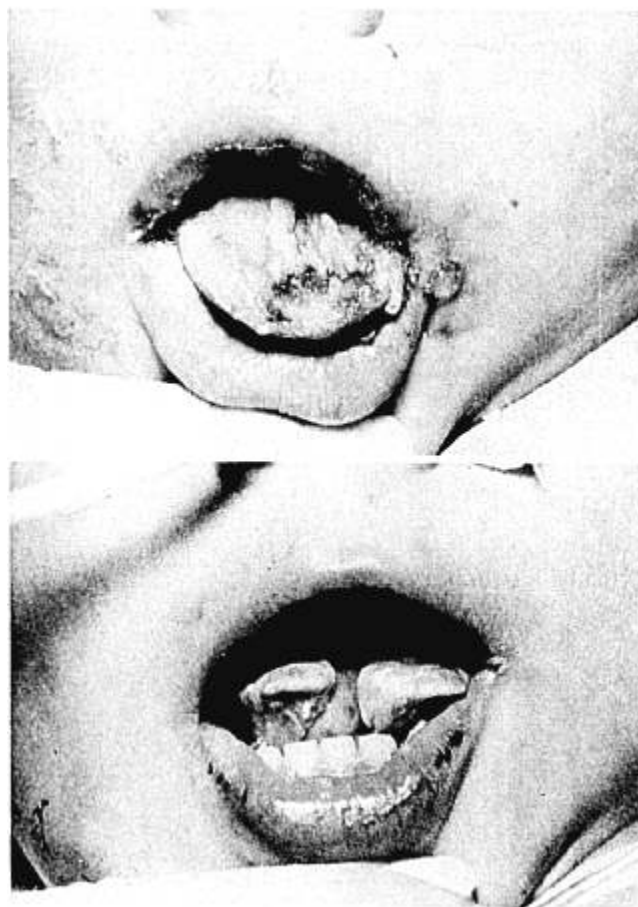


FIG. 1 (above). Necrotic area on the tongue.

FIG. 2 (below). Tongue after healing.

In the intensive care unit, however, prolonged oropharyngeal airway placement requires meticulous medical and nursing care if complications are to be avoided. In this case a bifid tongue, with the possibility of future reconstructive plastic surgery, might have been avoided if the oropharyngeal airway had been removed intermittently for routine mouth care. The airway was difficult, if not impossible, to remove, since it was held in place by the same strapping that secured the orotracheal tube. Additional strapping had been added by the nursing staff to help prevent the airway from being expressed during seizure activity.

Nasotracheal rather than orotracheal intubation would have removed the possibility of occlusion of the tube during seizures, but the problem of tongue protection would remain. In this case, nasotracheal intubation and an infant-sized dental bite block would have avoided the complication.