

## Clinical Reports

BURNELL R. BROWN, JR., M.D., Ph.D., *Editor*

Anesthesiology  
48:213-214, 1978

### An Unusual Complication of Brachial Plexus Block and Heparin Therapy

M. MANI, M.D.,\* N. RAMAMURTHY, M.D.,† T. L. K. RAO, M.D.,‡ A. P. WINNIE, M.D.§  
V. J. COLLINS, M.D.¶

The following is a report of an unusual complication of brachial plexus block and heparin therapy.

#### REPORT OF A CASE

A 33-year-old man was admitted to the hospital because of crush injury to the left index, middle and ring fingers. His past medical history was unremarkable.

Physical examination revealed no abnormality except the crush injury. The patient weighed 68 kg and his height was 168 cm. Laboratory studies revealed that the urine was essentially normal; hematocrit was 42 per cent. Chest x-ray was normal; ECG revealed a regular sinus rhythm.

No premedication was ordered. Brachial block was performed using the subclavian perivascular technique. Paresthesias were elicited during the second needle insertion, and bupivacaine, 0.6 per cent, 35 ml, was injected. No blood was detected on repeated attempts at aspiration while performing the block.

Satisfactory anesthesia was established in 15 minutes. The operation was uneventful and lasted 4½ hours. It consisted of reimplantation of the middle finger, amputation of the ring finger, and repair of the lacerations.

The patient received 2,000 ml crystalloid solution, 10 mg diazepam, and 0.05 mg fentanyl during the procedure. He was given 2,500 units of heparin 30 min before the end of the operation, heparin administration was then continued, 5,000 units every six hours, iv, as part of the postoperative surgical management to keep the anastomosed vessels patent.

On the third postoperative day the patient suddenly complained of pain in the left chest and difficulty in breathing. Blood pressure was 130/50 torr, pulse rate was 110/min, and respiratory rate, 30/min. He was sweating profusely. The trachea appeared to be shifted to the right and there was dullness to percussion and decreased air entry on auscultation of the left lower chest. Arterial blood-gas studies while the patient was breathing room air revealed

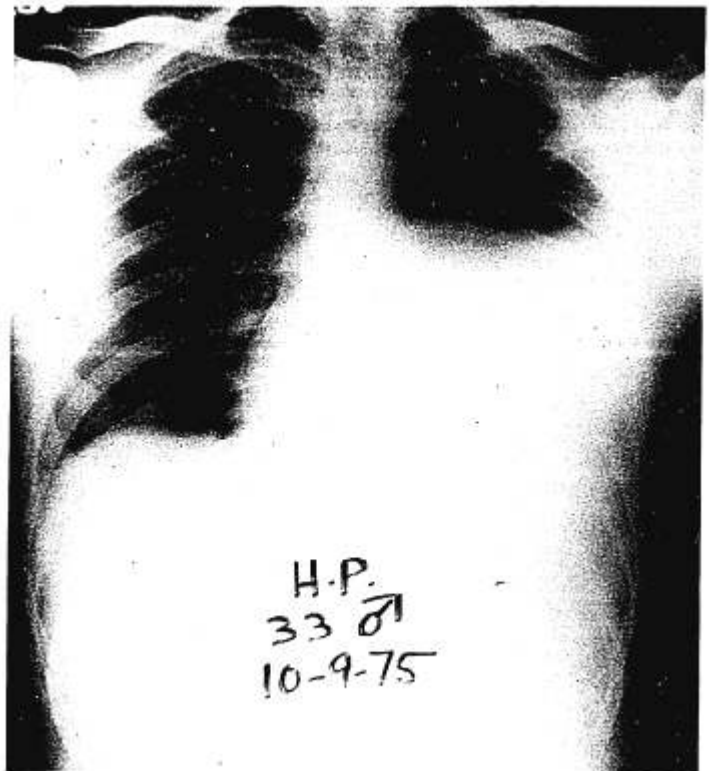


FIG. 1. Chest x-ray taken on the third postoperative day (before chest tube insertion) showing massive hemopneumothorax on the left.

pH 7.45,  $P_{CO_2}$  51 torr, and  $Pa_{O_2}$  60 torr. A clinical diagnosis of either hydro- or hemopneumothorax on the left was made and confirmed by the x-ray of the chest (fig. 1). A chest tube placed on the left drained 1,700 ml of blood-stained fluid. Heparin was discontinued. Coagulation studies revealed a prolonged partial thromboplastin time (100 sec with a control of 34 sec) and the platelet count was 213,000/cu mm. Partial thromboplastin time had been normal in the immediate postoperative period. After insertion of the chest tube, the patient felt comfortable, and vital signs reverted to normal. He recovered completely approximately a week later.

#### DISCUSSION

Pneumothorax following supraclavicular brachial plexus block is a recognized complication. Incidences vary depending upon the type of approach, number of

\* Chairman, Clinical Anesthesiology, Cook County Hospital (CCH).

† Resident, Department of Anesthesiology (CCH).

‡ Associate Chairman, Adult Anesthesiology (CCH).

§ Chairman and Professor, Department of Anesthesiology, University of Illinois Medical Center, Chicago, Illinois.

¶ Chairman, Department of Anesthesiology (CCH); Professor, Northwestern University Medical School, Chicago, Illinois.

Received from Cook County Hospital, 1825 W. Harrison St., Chicago, Illinois 60612. Accepted for publication August 30, 1977.

Address reprint requests to Dr. Mani.

punctures, use of positive-pressure breathing following an attempted block, and familiarity with the anatomic landmarks (such as the interscalene groove). While Moore<sup>1</sup> stated an incidence of 0.5 to 4 per cent, Brand<sup>2</sup> reported an incidence of 6.1 per cent. It has been claimed that the classic interscalene approach of Winnie<sup>3,4</sup> offers the least chance of producing pneumothorax. The single-injection subclavian perivascular approach can produce pneumothorax, though the incidence is very low.

To our knowledge, hemopneumothorax following brachial block in heparinized patients has not been reported. Spontaneous hemopneumothorax in patients undergoing heparin therapy for thromboembolic disease has been reported.<sup>5-7</sup> In most of these cases the primary disease was pulmonary infarction. The presumed mechanism in these instances was either rupture of the hemorrhagic infarction into the pleural cavity or spontaneous bleeding from the pleural membrane. In these cases the onset was delayed, and all had hemothorax that was not associated with pneumothorax. In the case presented, the onset was relatively acute following brachial block and heparin therapy. The clinical manifestations occurring on the third day indicated either slow leakage of blood into the pleural cavity or dislodgement of clot and sudden hemorrhage subsequent to the puncture of lung tissue and the continued heparin therapy, respectively. Though it could have been a spontaneous hemopneumothorax following anticoagulant therapy, the fact that it occurred on the same side as the brachial block, and the retrospective review of the routine immediate postoperative chest x-ray showing a 10 per cent pneumothorax, substantiate the cause of the hemopneumothorax in this patient as injury to the lung during brachial block. Anatomically, injury to the pleura and lung on the left

side is less likely because the left pleural dome is at a lower level in the neck compared with that on the right.

The normal platelet count in the postoperative period rules out the possibility that this bleeding was due to either idiopathic thrombocytopenia or heparin-induced immune thrombocytopenia.<sup>8</sup> The prolonged partial thromboplastin time indicates that the bleeding was due to the anticoagulant therapy. Most patients who have had hemothorax subsequent to pulmonary embolism have had some permanent sequelae. Many of these patients have had to undergo further surgical procedures such as decortication, whereas our patient did not.

The purpose of reporting this case is not to discourage the relatively safe technique of brachial block. It is to alert anesthesiologists to the rare possibility of development of this complication in patients heparinized during or after operation.

#### REFERENCES

1. Moore DC: Regional Block. Springfield, Ill., Charles C Thomas, 1969, pp 237-240
2. Brand L, Papper EM: A comparison of supraclavicular and axillary techniques for brachial plexus blocks. *ANESTHESIOLOGY* 22:226-229, 1961
3. Winnie AP, Collins VJ: The subclavian perivascular technique of brachial plexus anesthesia. *ANESTHESIOLOGY* 25:353-363, 1964
4. Winnie AP: Interscalene brachial plexus block. *Anesth Analg (Cleve)* 49:455-466, 1970
5. Millard CE: Massive hemothorax complicating heparin therapy for pulmonary infarction. *Chest* 59:235-237, 1971
6. Hamaker WR, Buchman RJ: Hemothorax—a complication of anticoagulant therapy. *Ann Thorac Surg* 8:564-569, 1969
7. Diamond MT, Fell SC: Anticoagulant-induced massive hemothorax. *NY State J Med* 73:691-692, 1973
8. Babcock RB, Dumper CW, Scharfman WB: Heparin-induced immune thrombocytopenia. *N Eng J Med* 295:237-241, 1976

Anesthesiology  
48:214-219, 1978

## Cerebrospinal Fluid Pressure and Subarachnoid Gas Composition during Nitrous Oxide Anesthesia for Gas Myelography

YUPADI PRASERTWANITCH, M.D.,\* AND RONALD A. GABEL, M.D.†

During gas myelography, a bubble of O<sub>2</sub> is introduced into the subarachnoid space to outline

\* Clinical Fellow in Anaesthesia, Harvard Medical School. Present address: St. Joseph Hospital, 215 West 4th Street, Mishawaka, Indiana 46544.

† Assistant Professor of Anaesthesia, Harvard Medical School.

Received from the Departments of Anesthesia, Peter Bent Brigham Hospital and Harvard Medical School, Boston, Massachusetts 02115. Accepted for publication August 31, 1977.

Address reprint requests to Dr. Gabel: Department of Anesthesia, Peter Bent Brigham Hospital, 721 Huntington Avenue, Boston, Massachusetts 02115.

abnormalities such as atrophy or edema of the spinal cord or obstruction of cerebrospinal fluid pathways. When air is used as a contrast medium during pneumoencephalography in man, the introduction of 70-75 per cent N<sub>2</sub>O into the inspired anesthetic mixture can lead to more than a doubling of the subarachnoid pressure.<sup>1</sup> However, data on the behavior of air introduced into the cerebral ventricles cannot be assumed to apply to O<sub>2</sub> confined to the spinal subarachnoid space. Therefore, we have examined some aspects of the transfer of N<sub>2</sub>O from blood into