

protruding about 5 cm beyond the distal end of the suction tubing. The stylet and the tubing are then bent into the desired configuration for intubation. The Carden tube is slid over the protruding distal end of the stylet to abut the plastic tubing. Care is taken so that the distal tip of the stylet comes no closer than 2 cm from the distal tip of the Carden tube to prevent tracheal injury (fig. 1). This configuration closely resembles a standard oral endotracheal tube. Laryngoscopy is then performed, and the Carden tube is inserted into the trachea with the tube placed immediately distal to the vocal cords. The stylet is removed while the plastic suction tubing remains in place against the Carden tube to prevent dislodgement of

the Carden tube. The cuff on the Carden tube is inflated, and the plastic suction tubing is removed.

We find this an easy, safe method of Carden tube insertion, which varies little from routine endotracheal intubation.

#### REFERENCES

1. Carden E, Crutchfield W: Anesthesia for microsurgery of the larynx (a new method). *Can Anaesth Soc J* 20:378-389, 1973
2. El-Naggar M, Keh M, Stemmers A, et al: Jet ventilation for microlaryngoscopic procedures: A further simplified technique. *Anesth Analg (Cleve)* 53:797-804, 1974
3. Cooke J, Hood J, Thomas J: A method for inserting the Carden tube. *Anesth Analg (Cleve)* 55:882-883, 1976

Anesthesiology  
49:221-223, 1978

### Conversion of Nasal to Oral Intubation

RAUL O. FERNANDEZ, M.D.,\* MARTIN F. MCCARTHY, M.B.,† MARTIN I. GOLD, M.D.‡

There are rare instances when nasal intubation must be followed by oral intubation in the same patient during maxillofacial or ear, nose, and throat surgery.<sup>1,2</sup> We describe here a technique to avoid dual intubation by using the same endotracheal tube.

A 55-year-old man with severe trismus secondary to facial trauma was scheduled for extensive elective surgery. The preoperative roentgenogram (fig. 1) demonstrates the fractured sites. Preoperative physical status was ASA 2. Atropine, 0.5 mg, and hydroxyzine, 125 mg, im, were administered for premedication. The patient was adequately sedated, 4 per cent lidocaine sprayed through both nostrils, and the nasopharynx and oropharynx similarly anesthetized; trans-laryngeal injection of 4 per cent lidocaine was accomplished.<sup>3</sup> A total of 6 ml of lidocaine was utilized. Awake blind nasotracheal intubation was accomplished with a 7.5-mm (ID) red rubber tube; anesthesia was induced with methohexital, 150 mg, iv, ventilation assisted, and anesthesia maintained with enflurane and nitrous oxide-oxygen, 50:50.

Following repair of the maxillary fractures, the intraoral part of the procedure was completed. To facilitate working on the infraorbital and nasal-

ethmoidal complex area, the endotracheal tube had to be repositioned. Figure 2 demonstrates the nasotracheal site of the endotracheal tube. Trismus was no longer present, and the oropharynx was suctioned. The cuff of the nasal tube was deflated, the metal

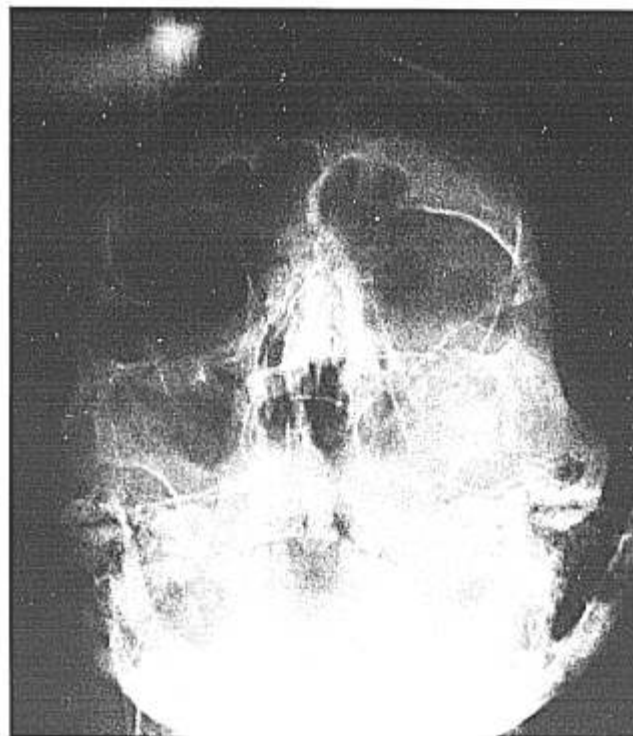

Fig. 1. Preoperative roentgenogram, demonstrating the fractured sites: 1) bilateral ethmoidal fractures; 2) nasal-bone fractures; 3) right maxillary bone fractures.

\* Resident.

† Resident.

‡ Professor, Department of Anesthesiology, University of Miami, School of Medicine; Chief, Anesthesia Service, Veteran's Administration Hospital, Miami, Florida 33125.

Accepted for publication February 6, 1978.

Address reprint requests to Dr. Gold: Miami Veteran's Administration Hospital, Department of Anesthesia, 1201 N. W. 16th Street, Miami, Florida 33125.

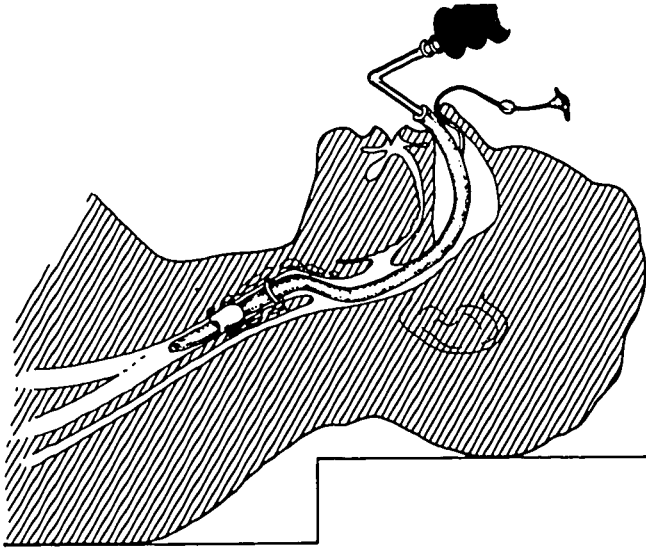


FIG. 2. The nasal tube in place, cuff inflated and bevel midway between carina and vocal cords.

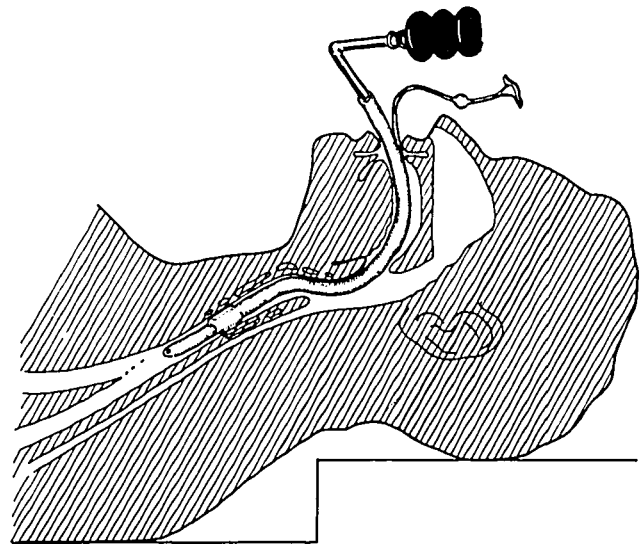


FIG. 4. The nasal intubation is now converted to an oral intubation, the cuff inflated, and the tube bevel is again midway between the carina and cords.

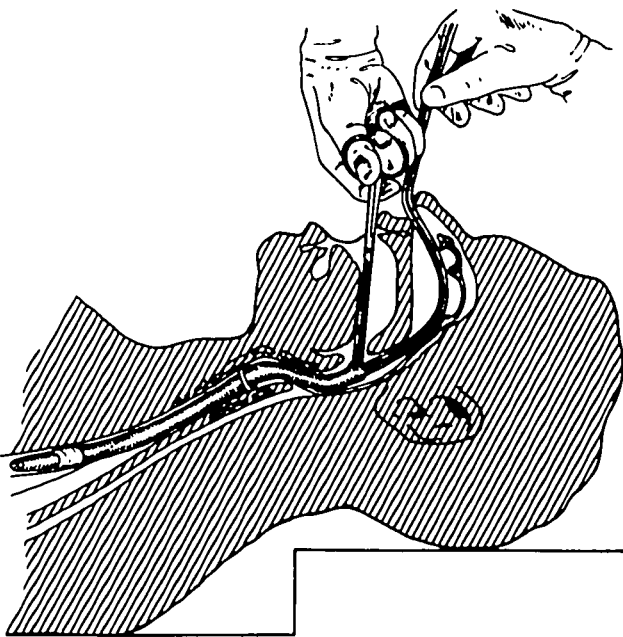


FIG. 3. The suction catheters wedged in the deflated endotracheal tube have allowed the advancement of the tube into the right main bronchus. The pilot tube with inflating balloon was also advanced with the endotracheal tube. A large hemostat grasps the proximal end of the tube and enables the withdrawal of the endotracheal tube along with the pilot tube.

adaptor was removed, and two suction catheters were wedged tightly in the proximal end of the tube for the purpose of moving it into the oropharynx. The tube was advanced, along with the pilot tube and inflating balloon, such that the distal end of the tube was now in the right main bronchus. With direct vision into the

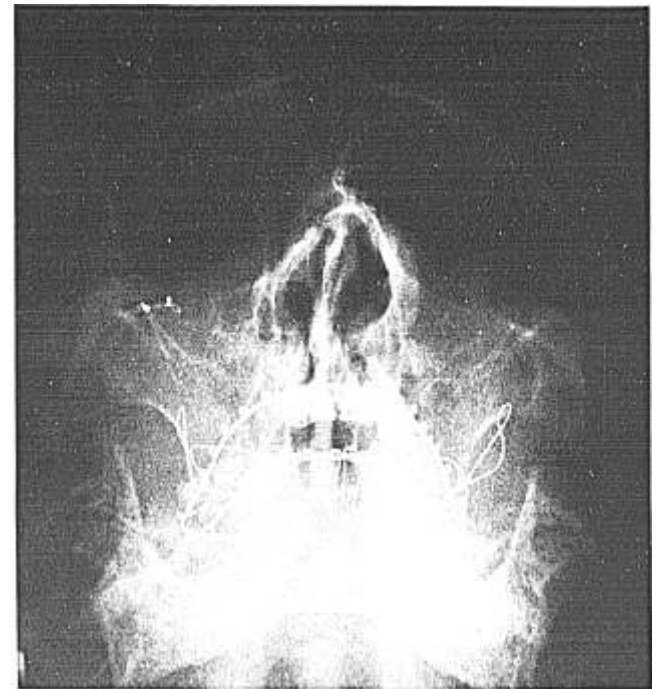


FIG. 5. Postoperative roentgenogram, demonstrating: 1) arch bars *in situ*; 2) repair of the fractured sites.

chest was auscultated and the cuff inflated after it was determined that the tube was above the carina. The operation proceeded without incident. The post-operative roentgenogram (fig. 5) demonstrates the repair of fractures and the arch bars in place.

The nasotracheal tube had been safely converted to an "oral" tube within 3 minutes. Oral reintubation with laryngoscopy was avoided. During this maneuver there was no retraction or airway obstruction, and the patient breathed spontaneously through and around the endotracheal tube and catheters. This appears to be a safe and simple technique for converting nasal to oral tracheal intubation when extensive maxillofacial procedures necessitate both airway routes to be used in sequence.

The authors thank Stuart N. Kline, D.D.S., Professor of Oral and Maxillofacial Surgery, for cooperation and advice.

#### ADDENDUM

Two subsequent dual intubations, identical to that described above, have been performed with facility, with no sequelae.

#### REFERENCES

1. Harang HL: Anesthesia for head and neck surgery with high frequency electro-surgical unit. *Anesth Analg (Cleve)* 24: 119-123, 1945
2. Makel HP, Pou LH, Chipps JE: Anesthesia in maxillofacial surgery. *ANESTHESIOLOGY* 14:498-500, 1953
3. Gold MI, Buechel DR: A method of blind nasal intubation for the conscious patient. *Anesth Analg (Cleve)* 39:257-263, 1960

*The appearance of the code at the bottom of the first page of an article in this journal indicates the copyright owner's consent that copies of the article may be made for personal or internal use, or for personal or internal use of specific clients. This consent is given on the condition, however, that the copier pay the stated per-copy fee through the Copyright Clearance Center, Inc., P.O. Box 765, Schenectady, New York 12301, for copying beyond that permitted by Sections 107 or 108 of the U.S. Copyright Law. This consent does not extend to other kinds of copying, such as copying for general distribution, for advertising or promotional purposes, for creating new collective works, or for resale.*