

## Clinical Reports

BURNELL R. BROWN, JR., M.D., PH.D., *Editor*

Anesthesiology  
49:285-286, 1978

### Catheter Embolization Due to Faulty Bonding of Catheter Shaft to Hub

DAVID H. SPRAGUE, M.D.,\* AND HASAN SARWAR, M.D.†

Embolization of fragments of intravenous catheters has been recognized as a potentially life-threatening complication of intravenous therapy.<sup>1,2</sup> Reported causes of catheter embolization include severance of the tubing on the sharp beveled needle used to introduce the catheter, breakage of the tubing from repeated flexion of the catheter across a joint, accidentally cutting off the catheter, and detachment of the catheter from a connecting piece of tubing or from an attachable intravenous adapter.<sup>1,2</sup> In this report, we describe a situation in which catheter embolization occurred as a result of separation of the catheter shaft from its permanently attached hub. Also, we report the results of tests performed to measure the strength of the bond between shaft and hub in a number of commonly used catheters.

#### REPORT OF A CASE

A 65-year-old woman was brought to the operating room for a coronary-artery bypass graft. During the procedure, a 12-gauge 3-inch radiopaque Teflon catheter (Deseret Angiocath, Deseret Pharmaceutical Co., Inc.) was placed in the left internal jugular vein. Approximately 48 hours after insertion, the bedding near the patient's head was observed to be damp. Upon inspection it was found that, although the intravenous tubing was still attached to the hub of the catheter, the hub of the catheter was no longer attached to the shaft.

Roentgenography revealed that the shaft had embolized and was lodged at the junction of the left internal jugular and subclavian veins. Therefore, the patient was taken to the cardiac catheterization laboratory, where an attempt was made to remove the catheter with a wire snare inserted percutaneously into the femoral vein. When this attempt proved unsuccessful, the snare was inserted percutaneously into the left internal jugular vein; however, because of its rigidity and length, the catheter was unable to be retrieved by snaring. Subsequent dissection in the supraclavicular area was

necessary for catheter removal. Examination of the retrieved shaft and separated hub revealed that embolization resulted from failure of the bond between shaft and hub (fig. 1).

#### METHODS

The bond between shaft and hub of various intravenous catheters was studied by observing the effects on the bond of catheter incubation in a constant-temperature water bath. Twelve-, 14-, 16-, 18-, 20-, and 22-gauge Deseret Angiocaths (Deseret Pharmaceuticals Co., Inc.); 14-, 16-, 18-, 20-, and 22-gauge Quik-Caths (Travenol Laboratories, Inc.); 14-, 16-, 18-, and 20-gauge Cathlon IV (Jelco Laboratories); and 20-gauge A-Caths (C. R. Bard, Inc.) were studied. Three groups containing six catheters of each type formed the study sample. Each group of catheters was incubated at one of three temperatures (20, 37, and 42 C) for seven days. The catheters were inspected daily, and the occurrence of separation of shaft from hub was recorded.

#### RESULTS

Separation of catheter shaft from hub did not occur when catheters were incubated at 20 C, but did occur

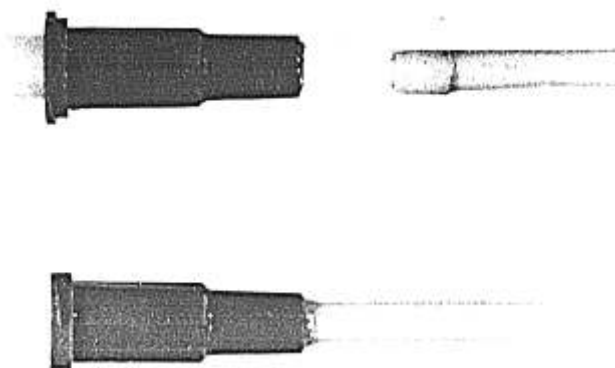


FIG. 1. The retrieved shaft embolus and separated hub with attached intravenous tubing are compared with an intact catheter.

\* Assistant Professor of Anesthesiology, Department of Anesthesiology, University of Kentucky School of Medicine, Lexington, Kentucky 40506.

† Staff Anesthesiologist, Department of Anesthesiology, St. Vincent's Medical Center, Bridgeport, Connecticut 06606.

Accepted for publication February 17, 1978.

Address reprint requests to Dr. Sprague: Department of Anesthesiology, The University of North Carolina School of Medicine, Chapel Hill, North Carolina 27514.

in four of each group of 96 catheters that were incubated at 37 and 42 C. Three of the 16 different catheters accounted for all eight instances of separation. During incubation at 37 C, one 12-gauge Deseret Angiocath separated on the fourth day, two 16-gauge Quik-Caths separated on the fifth day, and one 14-gauge Quik-Cath separated on the sixth day. Incubation at 42 C resulted in separation of one 12-gauge Deseret Angiocath on the second day, one 16-gauge Quik-Cath on the fifth day, one 12-gauge Deseret Angiocath on the sixth day, and one 14-gauge Quik-Cath on the seventh day.

#### DISCUSSION

The results of our study support the hypothesis that catheter embolization can result from faulty factory bonding of shaft to hub. The data also indicate that separation of shaft from hub is dependent on the type of catheter, the temperature of the catheter, and the length of time that the catheter is subjected to a given temperature. In the incident described in this case report, all these factors probably contributed to catheter embolization. The catheter at fault in the case report was one of the types found to be susceptible to shaft-hub separation after a number of days at 37 C. Held in place by a dressing over an area of high blood flow, the catheter presumably assumed a temperature at or near body temperature for approximately 48 hours. Other factors that might have contributed to the dissolution of the bond include the actions of bacteria and enzymes at the insertion site; the importance of these factors has not been investigated.

Anesthesiology  
49:286-288, 1978

## Blood Warmers as a Source of Solution-conducted Leakage Currents

DAVID G. BJORAKER, M.D.\*

Intracardiac electrodes and catheters are recognized as possible conductive pathways of microshock fibrillatory currents. Although careful design and scrupulous maintenance of equipment associated with invasive catheters will minimize risk of an electrical mishap, equipment not meeting leakage standards

In view of the seriousness of catheter embolization, to prevent its occurrence measures have been proposed. These measures include modifications of the needle used to insert the catheter, use of bevel covers to protect the needle point, immobilization of a joint crossed by the catheter, use of tubing in which the exposed end is larger than the lumen of the vessel, use of collodion over the exposed catheter, and taping or suturing the catheter shaft as well as the hub.<sup>1,2</sup> However, when a sterile dressing of antibiotic ointment and gauze is applied, the use of collodion, tape, or suture may not be entirely effective or practical. When such a dressing is used over a short catheter, sterility is violated by the use of nonsterile tape and slipping of the catheter out of the anchoring suture is predisposed to by the use of ointment. Therefore, it appears that use of a one-piece catheter with an exposed portion larger than the lumen of the vessel would be less likely to cause catheter embolization than catheters of bonded hub-shaft construction.

In summary, the data presented here indicate that the shaft-hub bond of some catheters is not reliable. When such catheters are used, secure fastening of the catheter shaft with tape or suture, although not ideal, should be used to reduce the risk of embolization.

#### REFERENCES

1. Wellmann KF, Reinhard A, Salazar EP: Polyethylene catheter embolism: Review of the literature and report of a case with associated fatal tricuspid and systemic candidiasis. *Circulation* 37:380-392, 1968
2. Doering RB, Stemmer EA, Connolly JE: Complications of indwelling venous catheters: With particular reference to catheter embolus. *Am J Surg* 114:259-266, 1967

may inadvertently be used. The purpose of this paper is to present data, obtained in investigation of a clinical situation, regarding commercial blood warmers as a source of potentially dangerous leakage currents from a fluid pathway.

#### REPORT OF A CASE

A 14-year-old girl, ASA physical status II, was admitted to the neurosurgical service with the diagnosis of cauda equina tumor for lumbar laminectomy. Neuroleptanesthesia was maintained with droperidol, fentanyl, nitrous oxide, oxygen, and *d*-tubocurarine with controlled ventilation and an endotracheal tube. Shortly after the anesthetist began whole-blood replacement, a 60-cycle signal as seen on a previously noise-free ECG display.

\* Instructor in Anesthesia, Department of Anesthesiology, University of Michigan Medical Center, Ann Arbor, Michigan 48109. Accepted for publication February 18, 1978.

Address reprint requests to Dr. Bjoraker: Department of Anesthesiology, S6344, University of Michigan Hospital, Ann Arbor, Michigan 48109.