

thermolabile plastic. However, we feel that a "venous tourniquet" effect could occur if slight twisting of the uvula resulted from the airway placement.

In retrospect, we wonder whether such occurrences are not more common than has been supposed but go unrecognized because they are regarded simply to be postintubation sore throat.

T. D. SEIGNE, M.D., F.F.A.R.C.S.I.  
A. FELSKE, C.R.N.A.

Anesthesiology  
49:376-377, 1978

### Ketamine in Acute Intermittent Porphyrinemia—Dangerous or Safe?

*To the Editor:*—Rizk *et al.* report the use of ketamine in a patient with acute intermittent porphyria without complication, and conclude that ketamine appears to be safe in patients with this disease.<sup>1</sup>

Porphyrinogenic activity of drugs may be assessed by examining their effects on the activity of delta-aminolevulinic acid synthetase (ALA-S) in liver homogenates of 17-day-old chicken embryos.

Eight hours after the injection of ketamine (Ketalar®, Parke-Davis), the activity of ALA-S in the liver increased (fig. 1). The increases were highly significant ( $P < 0.001$ ) at doses of 2 mg ketamine/egg or more as compared with the saline control. Keta-

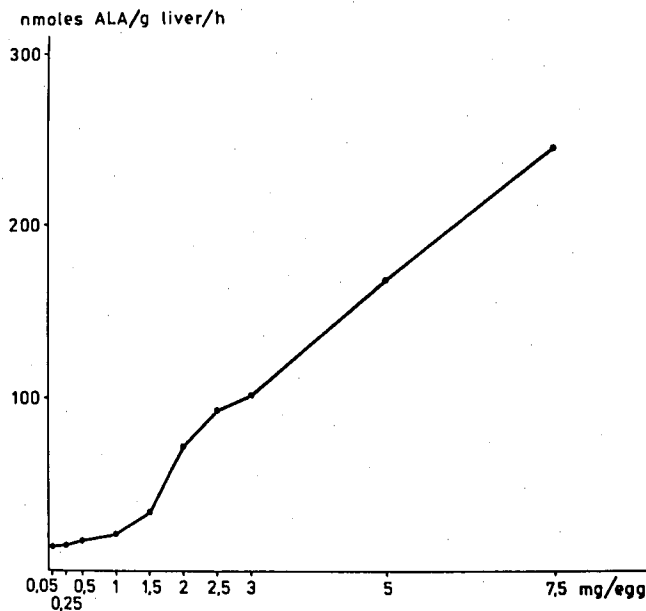


FIG. 1. Activities of ALA-S eight hours after different doses of ketamine. Each point represents the mean from ten examinations.

P. A. DELGIUDICE, M.D.  
Heritage Hospital  
24775 Haig Road  
Taylor, Michigan 48180

#### REFERENCE

1. Ravindran R, Priddy S: Uvular edema, a rare complication of endotracheal intubation. *ANESTHESIOLOGY* 48:374, 1978

(Accepted for publication June 22, 1978.)

mine, 0.5, 2, and 5 mg/egg, induced highly significant ( $P < 0.001$ ) increases in the activity of ALA-S four to eight hours after injection (fig. 2).

From our experiments we conclude that ketamine has porphyrinogenic effect and should not be given to patients with acute intermittent porphyria.

The discrepancy between our results and the clinical

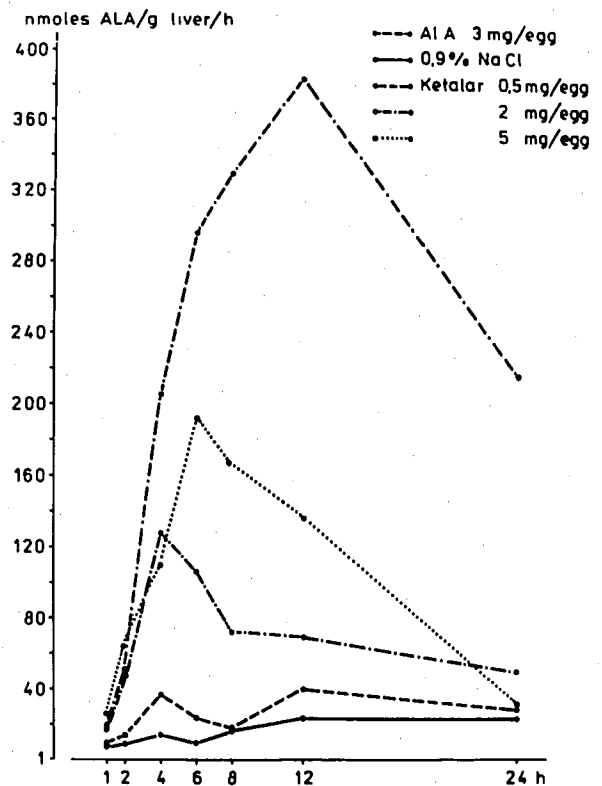


FIG. 2. Activities of ALA-S over a 24-hour period after injection of three doses of ketamine, 0.9 per cent NaCl, and AIA (allyliso-propylacetamid)—a strong porphyrinogenic material. Each point represents the mean values from ten examinations.

experience of Rizk *et al.* may be explained in at least two ways. First, even known porphyrinogenic drugs such as the barbiturates do not always induce the clinical manifestations in asymptomatic patients who have acute intermittent porphyria. Second, the authors assume the diagnosis from the history of the patient. There was no biochemical or enzymatic confirmation of the diagnosis prior to or after the operation. It could be that the patient did not have acute intermittent porphyria but rather another form of porphyria, less sensitive to drugs.

EWA KOSTRZEWSKA, M.D.  
ANITA GREGOR, PH.D.

DANUTA LIPINSKA, M.D.  
*Research Laboratory and  
Department of Anesthesiology  
Institute of Haematology  
Warsaw, Poland*

REFERENCE

1. Rizk SF, Jacobson JH, Silvey G: Ketamine as an induction agent for acute intermittent porphyria. *ANESTHESIOLOGY* 46:305-306, 1977

(Accepted for publication June 26, 1978.)

Anesthesiology  
49:377-378, 1978

### Hot Flashes in the Operating Room

*To the Editor:*—Vasomotor instability occurs in a large portion of the population. As many as 85 per cent of menopausal women may experience brief, periodic feelings of warmth in the face, neck, and upper thorax ("hot flushes") or more severe, sudden surges of heat involving the whole body with drenching sweats, often associated with feelings of weakness, anxiety, vertigo and nausea ("hot flashes").<sup>1</sup> Episodes commonly occur after meals, during exercise, or with emotional stress, but also develop during sleep. They may be as frequent as 20 times a day and can last for decades.<sup>2</sup> We observed a 52-year-old woman in whom a paroxysmal episode of facial flushing, profound sweating, tachycardia and hypotension developed during anesthesia and suddenly and spontaneously resolved after 8 min. There was no apparent precipitating factor. Postoperatively, the patient vividly described "hot flashes." Attempts to document vital signs during such episodes while the patient was awake were unsuccessful.

Unfortunately, there are few studies in the literature concerning the pathophysiology of "hot flashes." Temperature monitoring has documented that the digits and cheeks (where the flush occurs) warm as vasodilation occurs, while the remainder of the body that responds with marked sweating cools with evaporation. Internal body temperature decreases.<sup>3</sup> Heart rate increases, occasionally with arrhythmias.<sup>3,4</sup> Blood pressure increases are thought to occur, but probably the blood pressure responses are characterized by variability and instability.<sup>2</sup> No diagnostic, physiologic change that characterizes a "hot flash" results; the only

way to know one has occurred is the subjective description given by an awake patient. Thus, despite the resemblance of the intraoperative changes seen to the patient's menopausal symptoms, the occurrence of a "hot flash" during anesthesia must be purely speculative. Perhaps differential skin temperature monitoring would be useful.

The etiology of these episodes is obscure. Estrogen levels decrease and pituitary gonadotropin levels increase during the menopause. Yet other clinical conditions with similar hormonal changes are not associated with vasomotor instability.<sup>5</sup> Furthermore, not all women have vasomotor symptoms after oophorectomy, and there is no difference between hormone levels in groups with and those without attacks.<sup>6</sup> Although estrogens abolish symptoms of the menopause, so do other drugs and placebos.<sup>7</sup> Because of the similarity to attacks seen with the carcinoid syndrome, serotonin levels and 5-hydroxyindoleacetic acid excretion have been measured, but have not revealed any abnormality.<sup>8</sup> Evidence linking dopamine, norepinephrine and prostaglandins to the regulation of pituitary gonadotropins is accumulating, and the formation of catecholestrogens may modulate neuronal activity through specific binding sites in the brain.<sup>9</sup>

With the large number of menopausal women undergoing surgical procedures, it is unclear why intraoperative "hot flashes" have not been reported previously. Perhaps anesthetics influence the occurrence or manifestations, although it is more likely that cases have been attributed to "light" anesthesia, unknown "reflexes," or other causes. A preoperative assessment