

are not effective after the reaction has begun, nor will they alter the responses due to other chemical mediators.^{2,10,11} General anesthesia with ether or cyclopropane does not prevent anaphylaxis, although the reaction may be modified by these agents.¹² The prophylactic benefit of corticosteroids has not been well established. Schatz *et al.*¹³ showed that 5 of 42 (11.8 per cent) patients who had histories of anaphylactoid reactions to contrast media had repeat reactions when re-exposed to the media despite antihistaminic pretreatment. Zweiman *et al.*¹⁴ pretreated patients with histories of anaphylactoid reactions to contrast media with high-dose orally administered steroids for 18 hours before re-exposure. Repeat reactions were seen in one of nine (11 per cent) patients. Miller *et al.*⁹ reported a case in which high-dose oral steroid pretreatment for 72 hours was used successfully to prevent anaphylaxis on re-exposure to the contrast medium in a patient with a well-documented previous anaphylactic reaction.

Our patient had had a major anaphylactic reaction eight hours prior to her operation, and had been appropriately and successfully resuscitated. Although methylprednisolone, 100 mg, iv, used to treat the initial rash during catheterization, failed to prevent the subsequent anaphylaxis, a much larger dose of corticosteroid given intraoperatively with an antihistaminic agent prevented all clinical manifestations of a reaction to three injections of contrast material. The results in this case suggest that pretreatment with a large dose of corticosteroid and antihistamines may be beneficial in preventing anaphylaxis in patients known to have idiosyncratic reactions to contrast media. When emergency proce-

dures requiring contrast studies are necessary for these susceptible patients, pretreatment in this fashion should be considered.

REFERENCES

1. Mann MR: The pharmacology of contrast media. *Proc R Soc Med* 54:473-476, 1961
2. Scheffer AL: Therapy of anaphylaxis. *N Engl J Med* 275: 1059-1061, 1966
3. DeNosaquo N: Reactions to contrast media. *Radiology* 91: 92-95, 1968
4. Kelly JF, Patterson R: Anaphylaxis. *JAMA* 227:1431-1436, 1974
5. James LP, Austen KF: Fatal systemic anaphylaxis in man. *N Engl J Med* 270:597-603, 1964
6. Lasser EC, Sovak M, Lang JH: Development of contrast media idiosyncrasy in the dog. *Radiology* 119:91-95, 1976
7. Patterson R, Schatz M: Administration of radiographic contrast medium after a prior adverse reaction. *Ann Intern Med* 83:277, 1975
8. Lasser EC, Walters A, Reuter SR, et al: Histamine release by contrast media. *Radiology* 100:683-686, 1971
9. Miller WL, Doppman JL, Kaplan AP: Renal arteriography following systemic reaction to contrast material. *J Allerg Clin Immunol* 56:291-295, 1975
10. Brocklehurst WE: Slow reacting substance and related compounds. *Prog Allerg* 6:539-558, 1962
11. Morrow DH, Luther RR: Anaphylaxis: Etiology and guidelines for management. *Anesth Analg (Cleve)* 55:493-499, 1976
12. Carron H: Anaphylaxis and anesthesia: A preliminary report. *ANESTHESIOLOGY* 8:625-636, 1947
13. Schatz M, Patterson R, O'Rourke J, et al: The administration of radiographic contrast media to patients with a history of a previous reaction. *J Allerg Clin Immunol* 55:358-366, 1975
14. Zweiman B, Hildreth EA: An approach to the performance of contrast studies in contrast material-reactive persons. *Ann Intern Med* 83:159-162, 1975

Anesthesiology
50:57-59, 1979

Ventricular Tachycardia Terminated by Extubation of the Trachea

SUSAN K. PALMER, M.D.,* AND KITA D. PATEL, M.D.†

Although cardiac control is often explained in terms of intrinsic myogenic mechanisms, there is good experimental and clinical evidence that the sympathetic

and parasympathetic nervous systems exert profound and immediate control over cardiac rate, rhythm, fibrillation threshold and contractility.¹ Arrhythmias are commonly seen in patients with endotracheal tubes in place. Ventricular tachycardia terminated by removal of an endotracheal tube has not yet been reported. We report such a case and discuss possible mechanisms in terms of current theories of airway reflexes and neurogenic cardiac control.

* Assistant Professor, Chief, Section of Obstetric Anesthesia, Department of Anesthesiology, The Medical College of Wisconsin.

† Assistant Professor, Department of Anesthesiology, The Medical College of Wisconsin.

Received from the Department of Anesthesiology, The Medical College of Wisconsin, Milwaukee, Wisconsin, and Veterans Administration Hospital, Wood, Wisconsin 53193. Accepted for publication May 1, 1978.

Address reprint requests to Dr. Palmer: St. Mary's Hospital, Department of Obstetric Anesthesia, Fourth Floor, 2323 North Lake Drive, Milwaukee, Wisconsin 53211.

REPORT OF A CASE

A 45-year-old white man was admitted to the hospital with a history of incapacitating angina. His medications included nitro-

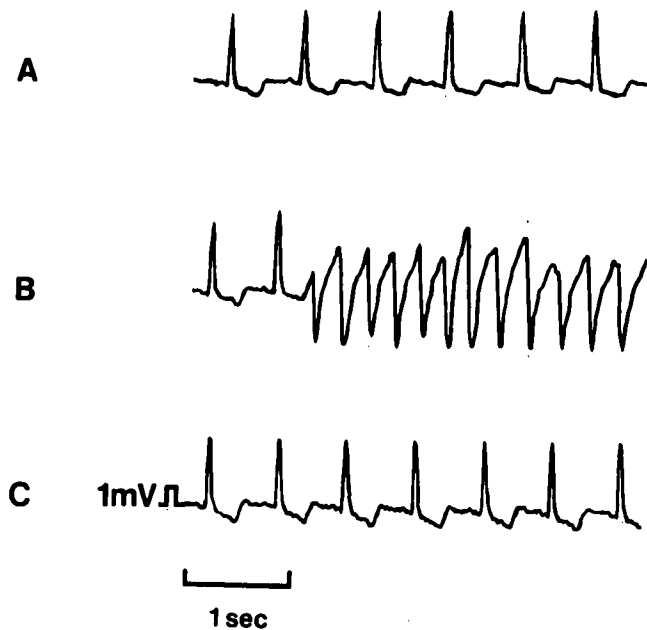


FIG. 1. Lead II ECG tracings obtained in the intensive care unit show A) the sinus rhythm present postoperatively, B) sudden ventricular tachycardia, and C) the reversion to sinus rhythm immediately after extubation of the trachea.

glycerin, propranolol, 80 mg, *t.i.d.*, and isosorbide dinitrate, 5 mg, *t.i.d.* There was no previous history of congestive heart failure, hypertension, diabetes, or previous myocardial infarction. Laboratory data were within normal limits. The ECG showed symmetrical T-wave inversions in leads I, AVL, and V₄ through V₆. The T-waves were flattened in leads II, III and AVF. Cardiac catheterization showed 90 per cent occlusion of the proximal left anterior descending coronary artery, total occlusion of the right coronary artery, and a poorly functioning left ventricle with an ejection fraction of 50 per cent. The patient was scheduled for an aortocoronary bypass grafting procedure.

The ECG, a radial arterial pressure transducer, central venous pressure, and urinary output were monitored. Induction of anesthesia was accomplished with diazepam, pancuronium, and fentanyl. Intubation of the trachea was accomplished with a #38 endotracheal tube after the larynx had been sprayed with 4 ml 4 per cent lidocaine. Anesthesia was maintained with N₂O-O₂, fentanyl, and halothane. The anesthetic and surgical courses were uneventful.

A three-vessel aortocoronary bypass grafting procedure was performed in six and a half hours. The patient was taken to the intensive care unit in satisfactory condition and ventilated with a Servo 900B ventilator. One hour postoperatively, he was awake, with normal arterial blood gases (table 1), stable blood pressure, minimal bleeding, and a good urinary output. Mechanical ventilation was discontinued and the patient maintained stable spontaneous ventilation with 70 per cent O₂ via T-piece with acceptable blood gases. He confirmed by nodding that the endotracheal tube was causing discomfort. He was given diazepam, and 10 mg in increments and morphine, 4 mg, *iv*. However, he became restless, coughed, and indicated by gestures that he wished to have the endotracheal tube removed.

The ECG monitor then showed abrupt ventricular tachycardia (fig. 1). Immediate elective extubation of the trachea by the anes-

thesiologist at the bedside resulted in a prompt conversion to a normal sinus rhythm. Although no antiarrhythmic agent was given, normal sinus rhythm was maintained. Arterial blood gases were stable (table 1), and the rest of the recovery period was uneventful. The patient was discharged from the hospital ten days later.

DISCUSSION

Manipulation of the airways can lead to cardiac arrhythmias.^{2,3} Mechanical stimulation of the nasal airway has been shown to cause reflex bradycardia, inhibition of ventilation, and laryngospasm in dogs.¹⁴ Electrical stimulation of the superior or inferior laryngeal nerve has been reported by many investigators to cause reflex bradycardia or even asystole.⁵

In man, the empirical relationship between endotracheal intubation or extubation, cardiac arrhythmias, and sudden death is well known but poorly understood.^{6,7} Katz and Bigger⁸ have reviewed the subject of cardiac arrhythmias during anesthesia; they suggest that many patients will have at least a transient arrhythmia during airway manipulation.

Central nervous system participation in cardiac rhythm control was indicated by Verrier *et al.*⁹ who demonstrated that stimulation of the posterior hypothalamus in dogs caused a 40 per cent reduction in ventricular fibrillation threshold. In a clinical study, Lown *et al.*¹⁰ documented that mental events such as anxiety and guilt can reproducibly cause ventricular tachycardia. Psychologic stimuli caused and psychiatric treatment controlled cardiac arrhythmias in their patients.

Animal investigations, like those of Kolman *et al.*,¹¹ have confirmed that sympathetic nerve stimulation increases the vulnerability of the canine ventricle to fibrillation. Abildskov¹² reported that electrical stimulation of cardiac sympathetic nerves caused QT-interval changes and associated increases in ventricular vulnerability to arrhythmia. They also documented that increased vagal activity could restore the fibrillation threshold to normal levels. Kolman's work¹¹ con-

TABLE 1. Arterial Blood Gases in the Postoperative Period

	Postoperative Time		
	1 Hour	2.5 Hours	3 Hours
Airway	Intubated	Intubated	15 min after extubation
Ventilation	Assisted	Spontaneous	Spontaneous
F _I O ₂	0.4 torr	0.7 torr	0.7 torr
pH	7.41	7.34	7.34
P _a CO ₂	39 torr	46 torr	45 torr
P _a O ₂	139 torr	124 torr	129 torr
HCO ₃ ⁻	23 mmol/l	24 mmol/l	24 mmol/l
K ⁺	3.9 mmol/l	4.0 mmol/l	4.0 mmol/l

firmed that the balance of autonomic control is more important than the absolute level of sympathetic or parasympathetic activity.

Our patient may have had either psychologically or mechanically induced autonomic nervous system activity that predisposed the ventricle to tachycardia. Pain and anxiety could have caused increased sympathetic activity, which transiently increased vulnerability to cardiac arrhythmia. Extubation of the trachea may have been provided the stimulation necessary for an immediate shift in autonomic balance in control of the heart and terminated the arrhythmia. Removal of the endotracheal tube could have stimulated tracheal, laryngeal, and pharyngeal receptors, producing a burst of parasympathetic afferent activity.¹³ Reflex efferent parasympathetic discharge¹⁴ then might have counteracted the relative sympathetic overactivity and restored normal cardiac rhythm. Besides the burst of parasympathetic activity caused by the removal of the endotracheal tube, the psychologic relief obtained may have reduced the level of sympathetic activity. The ventricular tachycardia was terminated immediately with extubation of the trachea, and normal cardiac rhythm was maintained without the aid of the usual exogenous pharmacologic agents.

REFERENCES

1. Randall WC: Neural Regulation of the Heart. Oxford, Oxford University Press, 1977
2. Converse JG, Landmesser CM, Harmel MH: Electrocardiographic changes during extubation ANESTHESIOLOGY 13: 163-168, 1952.
3. King BD, Elder JD, Proctor DF, et al: Reflex circulatory responses to tracheal intubation performed under typical anesthesia. ANESTHESIOLOGY 15:231-238, 1954
4. Jackson RT: Nasal-cardiopulmonary reflexes: A role of the larynx. Ann Otol Rhinol Laryngol 85:65-70, 1976
5. Iriuchijima J, Kumada M: On the cardioinhibitory reflex originating from the superior laryngeal nerve. Jap J Physiol 18: 453-461, 1968
6. Strong MS, Vaughan CW, Mahler DL, et al: Cardiac complications of microsurgery of the larynx: Etiology, incidence and prevention Laryngoscope 84:908-920, 1974
7. Wycoff CC: Endotracheal intubation: Effects on blood pressure and pulse rate. ANESTHESIOLOGY 21:153-158, 1960
8. Katz PL, Bigger JT: Cardiac arrhythmias during anesthesia and operation. ANESTHESIOLOGY 53:193-213, 1970
9. Verrier RL, Calvert A, Lown B: Effect of posterior hypothalamic stimulation on ventricular fibrillation threshold. Am J Physiol 228:923-927, 1975
10. Lown B, Temte JV, Reich P, et al: Basis for recurring ventricular fibrillation in the absence of coronary heart disease and its management. N Engl J Med 294:623-629, 1976
11. Kolman BS, Verrier RL, Lown B: The effect of vagus nerve stimulation upon vulnerability of the canine ventricle. Circulation 52:578-585, 1975
12. Abildskov JA: Adrenergic effects on the QT interval of the electrocardiogram. Am Heart J 92:210-216, 1976
13. Tomori Z, Widdicombe JG: Muscular, bronchomotor and cardiovascular reflexes elicited by mechanical stimulation of the respiratory tract. J Physiol (Lond) 200:25-49, 1969
14. Paintal AS: Vagal sensory receptors and their reflex effects. Physiol Rev 53:159-227, 1973

Anesthesiology
50:59-61, 1979

End-tidal Enflurane Concentration for Endotracheal Intubation

RONALD W. YAKAITIS, M.D.,* CASEY D. BLITT, M.D.,† JAMES P. ANGIULO, M.D.*

Inhalational induction followed by endotracheal intubation is a technique frequently employed in pediatric anesthesia. In an earlier study¹ we introduced the term MAC_{EI}, defined as the end-tidal concentration of a gas or vapor needed by 50 per cent of the population to prevent all movement both during and immediately after laryngoscopy and endotracheal intubation. MAC_{EI} for halothane was calculated to be 1.33 per cent at sea level. In the present report,

similar methods were employed to determine MAC_{EI} for enflurane in pediatric patients.

METHODS

Twenty-four studies were performed in 22 ASA I surgical patients, aged 2 to 6 years. Informed consent regarding the nature and risks of the study was obtained from the parent or guardian of each participant. Premedication consisted of atropine, 0.015 mg/kg. A precordial stethoscope was used to monitor heart and breath sounds. Blood pressure was measured indirectly, and lead II of the electrocardiogram was continuously displayed. Body temperature was monitored with a rectal thermistor. Induction of anesthesia was accomplished with enflurane, 4-5 per cent, and oxygen (5 l/min) delivered from an Enfluromatic vaporizer through a Jackson-Rees modification of an Ayres

* Assistant Professor.

† Associate Professor.

Received from the Department of Anesthesiology, University of Arizona, Health Sciences Center, Tucson, Arizona 85724. Accepted for publication May 4, 1978. Supported in part by a grant from Ohio Medical Products, Madison, Wisconsin.

Address reprint requests to Dr. Yakaitis at his present address: Department of Anesthesiology, Kino Community Hospital, 2800 East Ajo Way, Tucson, Arizona 85713.