

- bituate poisoning. *Acta Otolaryngol [Suppl] (Stockh)* 5:173, 1962.
10. Tonkin JP, Harrison GA: The effect on the larynx of endotracheal intubation. *Med J Aust* 2:581-587, 1966
  11. Hahn FW, Martin JT, Lillie JC: Vocal cord paralysis with endotracheal intubation. *Arch Otolaryngol* 92:226-229, 1970
  12. Salem MR, Wong AY, Barangan VC, et al: Postoperative vocal cord paralysis in paediatric patients. *Br J Anaesth* 43:696-699, 1971
  13. Ellis PDM, Pallister WK: Recurrent laryngeal nerve palsy and endotracheal intubation. *J Laryngol Otol* 89:823-826, 1975
  14. Jackson C: Contact ulcer granuloma and other laryngeal complications of endotracheal anesthesia. *ANESTHESIOLOGY* 14: 425-436, 1953.
  15. Hedden M, Ersoz CJ, Safar P: Tracheo-esophageal fistula following prolonged artificial ventilation via cuffed tracheostomy tubes. *ANESTHESIOLOGY* 31:281-289, 1969
  16. El-Naggar M, Sadagopan S, Levine H, et al: Factors influencing choice between tracheostomy and prolonged translaryngeal intubation in acute respiratory failure: A prospective study. *Anesth Analg (Cleve)* 55:195-201, 1976

Anesthesiology  
50:239-242, 1979

## Intraoperative Hemodynamic Changes during Total Knee Replacement

KAMRAN SAMII, M.D.,\* EDITH ELMELIK, M.D.,† MOHAMED B. MOURTADA, M.D.,‡  
JEAN DEBEYRE, M.D.,§ MAURICE RAPIN, M.D.¶

The physiologic consequences of intramedullary bone cement insertion during operations for total hip replacement have been subject to extensive study.<sup>1-4</sup> Total knee replacement differs from the hip operation in that during the former, the bone cement is inserted into two long medullary canals (tibial and femoral), and a tourniquet is generally used. Although complications such as hypotension, cardiac arrest, and fat embolism have been observed during the knee replacement operation,<sup>5-7</sup> relevant hemodynamic data have not been available. The present investigation was undertaken to obtain hemodynamic data from five patients who did not have bone cement inserted at operation and five patients who did.

### METHODS

Ten patients with no history or objective evidence of cardiopulmonary disease were studied. Six patients had osteoarthritis and four had rheumatoid arthritis. The patients were divided into two groups. Group I consisted of five patients with a mean age of 69 years (range 51-78 years) who underwent knee replacement without the use of bone cement. Group II consisted of five patients with a mean of 63 years

(range 49-80 years) who underwent knee replacement with use of bone cement.

Central venous pressure (CVP), pulmonary-artery wedge pressure (PWP), and pulmonary arterial pressure (PAP) were measured using a Swan-Ganz triple-lumen catheter, which was inserted from the antecubital fossa. Mean aortic pressure (MAP) was measured through a radial-artery catheter. Catheters were inserted 6-12 hours before operation. Heart rate (HR) was determined from a standard ECG lead. Cardiac output (CO) was measured in triplicate by the thermal dilution method with a computer (Edwards).

Derived variables were:

Cardiac index (CI)

$$= \text{CO/body surface area (l/min/m}^2\text{)}$$

Stroke volume index (SVI) = CI/HR (ml/m<sup>2</sup>)

Systemic vascular resistance (SVR)

$$= (\text{MAP} - \text{CVP})/\text{CI (torr/min/l} \times \text{m}^2\text{)}$$

### ABBREVIATIONS

CVP	= central venous pressure
PWP	= pulmonary wedge pressure
PAP	= pulmonary arterial pressure
MAP	= mean aortic pressure
HR	= heart rate
CO	= cardiac output
CI	= cardiac index
SVI	= stroke volume index
SVR	= systemic vascular resistance
PVR	= pulmonary vascular resistance
LVSWI	= left ventricular stroke work index
RVSWI	= right ventricular stroke work index

\* Chef de Clinique Assistant of Intensive Care Medicine.

† Assistant in Anesthesiology.

‡ Resident in Intensive Care Medicine.

§ Professor of Orthopedic Surgery.

¶ Professor of Intensive Care Medicine.

Received from the Departments of Intensive Care Medicine, Anesthesiology and Orthopedic Surgery of the Henri-Mondor Hospital, 94 010 Creteil-France. Accepted for publication June 17, 1978.

Address reprint requests to Dr. Samii: Département of Réanimation Médicale, Hôpital Henri-Mondor, 51 avenue du Maréchal de Lattre de Tassigny—94 010 Creteil-France.

TABLE 1. Hemodynamic Data prior to Anesthesia (Preoperative) and before (Control) and after Release of the Tourniquet

	Group I: Operation without Bone Cement (n = 5)					Group II: Operation with Bone Cement (n = 5)				
	Preoperative	Control	+3 min	+10 min	+120 min	Preoperative	Control	+3 min	+10 min	+120 min
PAP (torr)	18.0 ± 2.2	18.0 ± 1.3	19.0 ± 0.9	18.6 ± 1.3	19.4 ± 1.4	16.2 ± 2.6	18.4 ± 2.3	25.6 ± 4.0*	26.0 ± 3.6*	22.8 ± 2.5*
PVR (torr/ min/l × m <sup>2</sup> )	3.5 ± 0.3	2.9 ± 0.4	3.3 ± 0.5	3.6 ± 0.3	3.6 ± 0.3	3.4 ± 0.6	2.9 ± 0.3	7.4 ± 1.9*	6.7 ± 1.1*	5.0 ± 0.7*
CVP (torr)	5.4 ± 1.3	6.3 ± 1.3	5.7 ± 1.5	5.2 ± 1.0	7.1 ± 1.1	4.6 ± 0.7	7.8 ± 0.8	10.5 ± 3.0	9.2 ± 2.3	7.2 ± 0.9
PWP (torr)	7.5 ± 1.8	9.8 ± 0.6	9.6 ± 0.7	8.8 ± 1.2	8.6 ± 1.1	7.1 ± 1.2	7.8 ± 1.2	8.4 ± 2.8	7.6 ± 2.6	6.8 ± 0.9
MAP (torr)	96 ± 6	90 ± 3	92 ± 6	96 ± 6	100 ± 4	95 ± 5	88 ± 6	88 ± 8	89 ± 7	88 ± 8
HR (beats/ min)	87 ± 7	80 ± 7	82 ± 9	79 ± 8	81 ± 7	91 ± 5	93 ± 5	98 ± 11	96 ± 11	104 ± 15
CI (l/min/ m <sup>2</sup> )	2.9 ± 0.4	3.0 ± 0.3	3.1 ± 0.4	3.1 ± 0.4	2.9 ± 0.3	3.3 ± 0.1	3.5 ± 0.2	2.8 ± 0.5	3.1 ± 0.6	3.3 ± 0.2
SVI (ml/m <sup>2</sup> )	33 ± 2	37 ± 2	38 ± 2	39 ± 4	36 ± 2	36 ± 2	38 ± 2	29 ± 5*	32 ± 4	32 ± 3
SVR (torr/ min/l × m <sup>2</sup> )	29.8 ± 3.1	28.1 ± 3.2	30.0 ± 4.1	31.0 ± 3.3	31.4 ± 2.7	27.2 ± 2.6	25.8 ± 1.3	33.1 ± 8.8	31.6 ± 6.7	30.4 ± 4.6
RVSWI (g- m/m <sup>2</sup> )	5.7 ± 1.2	5.9 ± 1.0	6.9 ± 1.4	7.1 ± 1.6	6.0 ± 1.2	5.7 ± 0.7	5.5 ± 1.2	6.0 ± 1.4	7.4 ± 2.0	6.8 ± 1.7
LVSWSI (g- m/m <sup>2</sup> )	44 ± 3	45 ± 3	45 ± 5	51 ± 7	49 ± 5	45 ± 5	46 ± 4	32 ± 5*	37 ± 4	36 ± 3

\* Significantly different from control value ( $P < 0.05$ ); mean values ± SEM are shown.

Pulmonary vascular resistance (PVR)

$$= (\text{PAP} - \text{PWP}) / \text{CI} \text{ (torr/min/l} \times \text{m}^2\text{)}$$

Left ventricular stroke work index (LVSWSI)

$$= (\text{MAP} - \text{PWP}) \times 1.36 \times \text{SVI} / 100 \text{ (g} - \text{m/m}^2\text{)}$$

Right ventricular stroke work index (RVSWI)

$$= (\text{PAP} - \text{CVP}) \times 1.36 \times \text{SVI} / 100 \text{ (g} - \text{m/m}^2\text{)}$$

Blood gases were analyzed with standard electrodes at 37 C, and values were corrected to measured body temperature. All patients were subjected to similar anesthetic techniques. Premedication consisted of atropine, 0.5 mg, im, and diazepam, 10 mg, im, an hour before operation. Spinal anesthesia to T<sub>10</sub> was performed 20 min prior to operation with tetracaine. A constant intraoperative iv infusion of diazepam (10 mg diazepam in 500 ml 5 per cent dextrose solution) was maintained at a rate of 0.02 mg/min in either group. The patients, who were drowsy but responsive, breathed ambient air to which oxygen was added at 3l/min through a face mask. Intravascular volume expansion was provided by blood transfusions 5 min before and after release of the tourniquet. Volumes infused averaged 830 ml (700–1,050 ml) in Group I and 860 ml (650–1,000 ml) in Group II.

Group I patients received a so-called "Caviar" prosthesis, which is covered with little grains and is fixed to the bone without the use of bone cement. Group II patients received a so-called "Guepar" prosthesis, which requires insertion with acrylic

bone cement. Mean durations of tourniquet applications and operations were similar in the two groups (85 and 110 min, respectively, in Group I; 85 and 120 min in Group II).

Preoperative measurements were performed an average of two hours before operation. The sequence of hemodynamic measurements and operative events was: control, before release of the tourniquet, and 3, 10, and 120 min after tourniquet release. Blood gases were measured in three patients of Group I and four patients of Group II before and 3 and 10 min after release of the tourniquet.

All statistical analyses were performed using the Student t test for paired and unpaired samples.

## RESULTS

The hemodynamic data obtained prior to spinal anesthesia, before release of the tourniquet, and 3, 10, and 120 min after release of the tourniquet are summarized in table 1. Preoperative hemodynamic values were within normal limits and not different in the two groups. Control measurements performed during spinal anesthesia before release of the tourniquet showed no change from preoperative values. After release of the tourniquet, no hemodynamic change was observed in Group I, whereas patients in Group II had constant and significant ( $P < 0.05$ ) increases in PAP and PVR at 3 (+39 and +155 per cent, respectively), 10 (+41 and +131 per cent), and 120 min (+24 and +72 per cent) (fig. 1). The elevation of CVP at 3 min was not

significant, and RVSWI was not changed. The systemic hemodynamic changes in Group II included a constant ( $P < 0.05$ ) decreases in SVI and LVSWI at 3 min (-24 and -30 per cent, respectively). No change in CI was observed. After release of the tourniquet,  $Pa_{O_2}$  remained  $\geq 86$  torr in the three patients studied in Group I and  $\geq 79$  torr in the four patients studied in the Group II.

One patient in Group II (a 66-year-old woman), whose hemodynamic changes after release of the tourniquet were similar to those of the other patients of Group II, experienced the clinical signs of fat embolism, including mental confusion, dyspnea, and an elevated temperature (39.5 C), 180 min after release of the tourniquet, followed after 24 hours by petechiae on the torso and fluffy roentgenographic densities in both lung fields. These manifestations reverted spontaneously and the patient recovered.

#### DISCUSSION

Patients in Group I, without bone cement, had no significant hemodynamic change after release of the tourniquet, whereas patients of Group II, in whose operations bone cement was used, had pulmonary and systemic hemodynamic changes.

The absence of a significant change in Group I was probably due to the fluid replacement therapy, which prevented hypovolemia induced by the release of the tourniquet. Although the two groups were similar with respect to anesthetic techniques, preoperative and control hemodynamic data, durations of tourniquet application, and volumes of fluid replaced, Group II had significant hemodynamic changes after release of the tourniquet. The consistent, immediate and sustained increases in PAP and PVR without significant decrease in CI or arterial hypoxemia suggest pulmonary vascular obstruction. The unchanged RVSWI despite a decrease in SVI implies greater right ventricular pressure work, and may explain the slightly elevated CVP. The decrease in LVSWI at 3 min suggests a change in left ventricular performance, which may be due to a decreased preload. The unchanged PWP suggests a maintained preload. However, PWP may not reflect true pulmonary venous pressure when obstruction of a pulmonary capillary had occurred.<sup>8</sup> Indeed, such a pressure gradient between PWP and left atrial pressure has been reported to occur in experimental fat embolism.<sup>9</sup> On the other hand, the acute increase in right ventricular afterload may induce dilatation of the right ventricle and movement of septum toward the left ventricle,<sup>10</sup> which would alter the left ventricular pressure-volume relationship.<sup>11</sup> Thus, decreased end-diastolic pressure in the left ventricle may be observed.

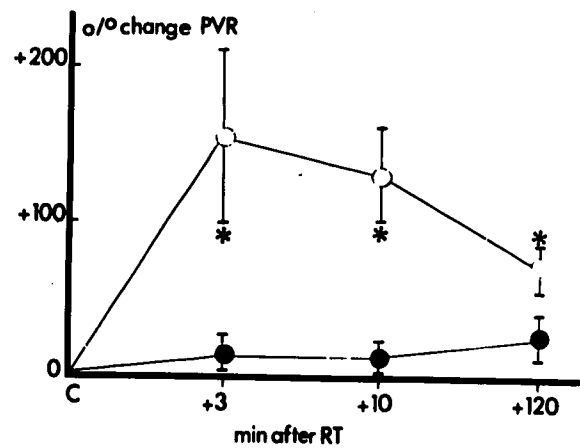


FIG. 1. Changes (per cent  $\pm$  SEM) in pulmonary vascular resistance (PVR) following release of the tourniquet in the two groups of patients. Group I ( $n = 5$ ) is represented by closed circles and Group II ( $n = 5$ ) by open circles. C = prior to release of the tourniquet; +3 min, +10 min, and +120 min = after release of the tourniquet. Changes in Group II were significantly ( $P < 0.05$ ) different from control (\*).

Although the pattern of hemodynamic changes during operations for hip replacement resembles that which we observed in Group II, the changes are not exactly similar. Impaction of the hip prosthesis induces little<sup>4</sup> or no increase<sup>5</sup> in PVR, and a transient reduction in MAP,<sup>1,3,4</sup> without change in CI.<sup>4,5</sup> On the other hand, the differences between the hemodynamic changes observed during the hip operation and in our Group II are probably due to differences in the surgical procedures. During the knee operation the prosthesis is inserted into two long medullary canals (tibial and femoral), and the area of contact between bone cement and bone exceeds that associated with the hip operation (femoral and acetabular). On the other hand, the release of the tourniquet in the knee operation results in hypovolemia and delayed contact between the circulation and the operative area.

The pulmonary vascular obstruction observed in Group II was probably secondary to release of medullary fat into the vascular compartment. Experimental fat embolism increases PVR and reduces CI.<sup>9,12,13</sup> Insertion of a prosthesis with bone cement induces a rise in bone-shaft pressure and increased medullary fat absorption.<sup>14</sup> In addition, typical manifestations of fat embolism occurred in one patient of Group II.

In conclusion, total knee replacement with the use of bone cement to fix the prosthesis induces an immediate, important pulmonary vascular obstruction and decrease in left ventricular performance after release of the tourniquet. Such hemodynamic changes may explain the cardiac arrest

previously reported, particularly when intravascular volume expansion is inadequate to correct the hypovolemia and the increase in right ventricular afterload induced by the release of the tourniquet.

The authors thanks Drs. J. M. Desmonts, M. B. Laver, and G. Vourec'h for encouragement and useful advice.

#### REFERENCES

1. Frost PM: Cardiac arrest and bone cement. *Br Med J* 3:524, 1970
2. Philips H, Cole PV, Lettin AWF: Cardiovascular effects of implanted acrylic bone cement. *Br Med J* 3:460, 1971
3. Schuh FT, Schuh SM, Viguera MG, et al: Circulatory changes following implantation of methylmethacrylate bone cement. *ANESTHESIOLOGY* 39:455-457, 1973
4. Modig J, Malmberg P: Pulmonary and circulatory reactions during total hip replacement surgery. *Acta Anaesthesiol Scand* 19:219-237, 1975
5. Harris NH: Cardiac arrest and bone cement. *Br Med J* 3: 523, 1970
6. Arden G: Total joint replacement of the knee in rheumatoid arthritis. *J Bone Joint Surg* 53:150, 1971
7. Duparc J, Desmonts JM, Olivier H, et al: Accidents graves après mise en place de prothèses totales scellées du genou. *Nouv Presse Med* 4:253-256, 1975
8. Pontoppidan H, Wilson RS, Ric MA, et al: Respiratory intensive care. *ANESTHESIOLOGY* 47:96-116, 1977
9. Parker FB, Wax SD, Kusajima K, et al: Hemodynamic and pathological findings in experimental fat embolism. *Arch Surg* 108:70-74, 1974
10. Wexler LF, Pohost GM: Hemodynamic monitoring: Noninvasive techniques. *ANESTHESIOLOGY* 47:96-116, 1977
11. Khaja F, Parker JO: Right and left ventricular performance in chronic obstructive lung disease. *Am Heart J* 82: 319-324, 1971
12. Bruecke P, Bruke JF, Lam KW, et al: The pathophysiology of pulmonary fat embolism. *J Thorac Cardiovasc Surg* 61:949-955, 1971
13. Sikorski J, Pardy BJ, Bradfield JWB, et al: The pathophysiological changes of experimental fat embolism: Early pre-hypoxaemic changes. *Br J Surg* 64:6-10, 1977
14. Hallin G, Modig J, Nordgreen L, et al: The intramedullary pressure during the bone marrow trauma of total hip replacement. *Surg Upsala J Med Sci* 79:51-55, 1974

Anesthesiology  
50:242-244, 1979

## Comparison of a New Formulation of Etomidate with Thiopental—Side Effects and Awakening Times

ROBERT J. FRAGEN, M.D.,\* AND NANCY CALDWELL, C.R.N.A.†

Etomidate is a pure hypnotic that does not cause significant cardiovascular<sup>1</sup> or respiratory<sup>2</sup> depression or histamine release. However, the side effects of pain on injection and myoclonic movements are frequent.<sup>3-5</sup> A new formulation of etomidate, using 35 per cent propylene glycol as solvent, was studied to determine whether it was associated with a lesser incidence of these side effects.

The pharmacologic properties of etomidate suggest that it would be a good induction agent for outpatient anesthesia, where rapid awakening is desirable. Since there are no previous reports of awakening time tests after etomidate, this measurement was also included in our study. Etomidate and thiopental were compared in hypnotic-narcotic-nitrous oxide anesthesia for minor gynecologic operations.

\* Associate Professor of Clinical Anesthesia.

† Research Assistant in Anesthesia.

Received from the Department of Anesthesia, Northwestern University Medical School and Northwestern Memorial Hospital, Chicago, Illinois 60611. Accepted for publication June 27, 1978. Supported in part by a grant-in-aid from Janssen R & D, Inc.

Address reprint requests to Dr. Fragen.

#### METHODS

Forty women scheduled for minor gynecological operations were admitted to the study after being fully informed of the nature of the study and signing a consent form.‡ All patients were classified as ASA physical status I or II. The unpremedicated patient had an iv infusion of 5 per cent dextrose in lactated Ringer's solution started in an antecubital vein to reduce the possibility of venous irritation. Fentanyl, 0.1 mg, and atropine, 0.6 mg, were administered iv 5-10 min before induction of anesthesia.

The patients were divided into two equal groups by use of a table of random numbers. Group A (n = 20) received etomidate, 0.3 mg/kg, iv, for induction of anesthesia. Anesthesia was continued with nitrous oxide/oxygen, 2:1. Half the induction dose was given subsequently when swallowing, movement, or an abrupt increase in heart rate or blood pressure occurred. At the end of the surgical procedure,

‡ This study was reviewed and approved by the Northwestern University-Northwestern Memorial Hospital Institutional Review Board.