

Milk of Magnesia is an Effective Preinduction Antacid in Obstetric Anesthesia

R. G. Wheatley, M.B., Ch.B., F.F.A.R.C.S.,* F. T. Kallus, M.D., Ph.D.,†
R. C. Reynolds, M.D.,‡ A. H. Giesecke, Jr., M.D.§

The effects on gastric fluid pH of a single dose of milk of magnesia given at various intervals prior to induction of general anesthesia in 115 parturients needing emergency operative delivery with general anesthesia were studied. In addition, the responses of rat lungs to tracheally injected gastric contents from parturients treated with orally administered milk of magnesia and untreated were compared. Stomach contents from parturients were removed by orogastric sump tube as soon as possible after induction of anesthesia. Single doses of milk of magnesia were given at various intervals prior to induction to 99 patients. No patient who received milk of magnesia 10 to 80 min prior to sampling was found to have a gastric-fluid pH of less than 2.5 and volume of more than 25 ml. Five parturients who had taken milk of magnesia and had gastric-fluid pH values of less than 2.5 had received the antacid more than 80 min prior to sampling of gastric contents. Of 16 patients who did not receive an antacid, five had gastric-fluid pH values of less than 2.5 and volumes of more than 25 ml.

Lung-weight-to-body-weight (LW/BW) ratios were significantly different for the three groups of rats studied. The LW/BW ratio was 8.0×10^{-3} for rats that received tracheal instillations of gastric fluid from one parturient who was not treated with milk of magnesia and whose gastric-fluid pH was 1.4. The LW/BW ratio was 6.4×10^{-3} in 20 rats that received intratracheal instillations of gastric fluid from one parturient who was treated with milk of magnesia and whose gastric-fluid pH was 8.7. The LW/BW ratio of sham-injected rats was 5.3×10^{-3} .

The authors conclude that milk of magnesia is an effective preinduction antacid in emergency obstetric anesthesia; that a single dose of 30 ml prior to induction will increase the pH values of gastric contents to more than 2.5 in all patients in the interval from 10 to 80 min after ingestion; and that milk of magnesia-neutralized gastric contents resulted in less severe induced aspiration pneumonitis in rats than did acidic gastric contents. (Key words: Anesthesia, obstetric. Complications, aspiration. Gastrointestinal tract, stomach: antacid. Lung: aspiration.)

Too much emphasis cannot be placed upon the danger from aspiration of vomitus—Guedel, 1937¹

* Consultant Anaesthetist, York District Hospital, York, England, United Kingdom.

† Assistant Professor of Anesthesiology, University of Texas Southwestern Medical School.

‡ Professor of Pathology, University of Texas Southwestern Medical School.

§ Professor and Vice Chairman, Department of Anesthesiology, University of Texas Southwestern Medical School.

Received from the Department of Anesthesiology, University of Texas Southwestern Medical School, Dallas, Texas 75235, and the Obstetrical Suite, Parkland Memorial Hospital, Dallas, Texas. Accepted for publication September 18, 1978. Supported by United States Public Health Service, Pulmonary Score Grant 2P50HL14187-06.

ASPIRATION PNEUMONITIS is an important cause of maternal mortality.² Victims who survive usually have significant residual pulmonary disability. To decrease the hazards of aspiration pneumonitis, obstetric anesthesiologists have encouraged the widespread use of regional and local anesthesia for vaginal delivery; have discouraged oral intake in the laboring woman³; have recommended tracheal intubation where general anesthesia was necessary⁴; recently, have promoted the preinduction use of antacids to neutralize gastric acid and to decrease its damaging effects to the respiratory tract.⁵ Magnesium trisilicate was initially recommended.⁶ However, no American antacid product contains magnesium trisilicate as a major component, and the mixtures containing mostly aluminum hydroxide were shown to be less effective in the prevention of murine aspiration pneumonitis.⁶ Comparative analysis of commercially available antacids has revealed that milk of magnesia mixes with gastric contents rapidly, neutralizes rapidly and completely, and has a relatively short duration of action.⁷

The purpose of this study was twofold: to measure the effects on gastric-fluid pH of a single dose of milk of magnesia given at various intervals prior to induction of general anesthesia in obstetric patients, and to compare the responses of rat lungs to tracheally injected gastric contents from obstetric patients treated with milk of magnesia and untreated.

Methods

One hundred fifteen parturients who needed either emergency cesarean section or operative vaginal delivery with general anesthesia consented to removal of gastric contents by orogastric sump tube after induction of unconsciousness. All patients were in labor, all were in good general health, and all were free of known gastrointestinal disease. The most common indications for operative delivery were fetal distress, cephalopelvic disproportion after a trial of labor, and previous cesarean section in labor. Analgesia during labor was provided with meperidine. The only anticholinergic given was atropine, 0.5 mg, iv, immediately prior to induction of anesthesia. Ninety-nine of these received a single dose of milk of magnesia, 30 ml, orally, at intervals

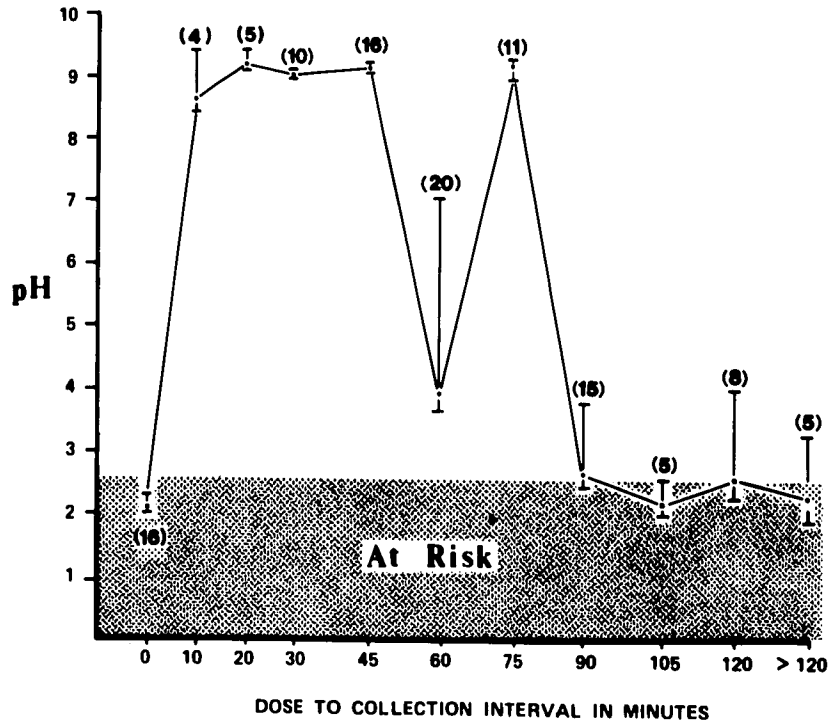


FIG. 1. Hydrogen ion concentration expressed as pH, mean \pm SE. Number of patients in each dose-to-collection interval is expressed in parentheses (n).

prior to induction of anesthesia. Sixteen refused milk of magnesia prior to induction on the basis of allergy, personal preference, or insufficient time due to the urgency of the need for obstetric intervention. Induction of anesthesia was accomplished with intravenous administration of *d*-tubocurarine, 3 mg, thiopental, 3 mg/kg, and succinylcholine, 100 mg. Cricosophageal compression was applied by an assistant, and the trachea was intubated orally under vision. No patient vomited or regurgitated during induction. Anesthesia was maintained with nitrous oxide, oxygen and *d*-tubocurarine, pancuronium, or succinylcholine, 0.2 per cent, by iv infusion. Following endotracheal intubation, an 18-F Salem sump tube was inserted through the mouth into the stomach and all possible gastric contents were removed by repeatedly applying suction with a catheter syringe to the sump tube at several different positions in the stomach. The volume of gastric contents was measured and the total sample immediately frozen. All samples were stored at -10°C until ready for use in the murine pneumonitis response test. After thawing, the pH of the sample was measured with an Orion Model 910200 combination pH electrode attached to an Orion Model 801 electrometer. The measured pH values were converted to hydrogen ion concentrations, grouped according to dose-collection intervals, and the mean and standard error for each group calculated. These values were plotted as pH against the interval that had elapsed from the preinduction dose of milk of magnesia to the

collection of gastric contents (fig. 1). Values for patients who had not received milk of magnesia were plotted at "0" dose-to-collection interval. As defined by Roberts and Shirley,⁵ a patient was considered "at risk" when gastric volume exceeded 25 ml and when pH was less than 2.5.

Seventy Sprague-Dawley rats, free of pre-existing respiratory disease, were supplied by Charles River Laboratories. These rats were unselected as to sex, and all weighed approximately 250 g. The rats were anesthetized with methoxyflurane in a bell jar⁸ and divided into three groups: control, antacid-treated, and acid-treated. In the control group, the glottis was exposed with a bivalve nasal speculum and under illumination with a headlamp a 20-g Teflon[®] cannula was introduced into the trachea.⁹ No injection was made. The rats recovered for four hours and were sacrificed by intraperitoneal injection of thiopental, 50 mg/kg. As soon as the animal lost consciousness, the thorax was opened by a median sternotomy and the lungs were allowed to collapse. The mediastinal organs were removed and the lungs were separated from all mediastinal tissue at the hilum under a self-illuminated magnifier. All blood vessels were left open and allowed to bleed freely. The lungs were blotted to remove bloody residue and weighed on a Mettler type B6 balance to the nearest 0.01 g. A lung-weight/body-weight ratio (LW/BW) was determined. The visceral pleura over each lobe was then incised with a scalpel to expose the parenchyma and the

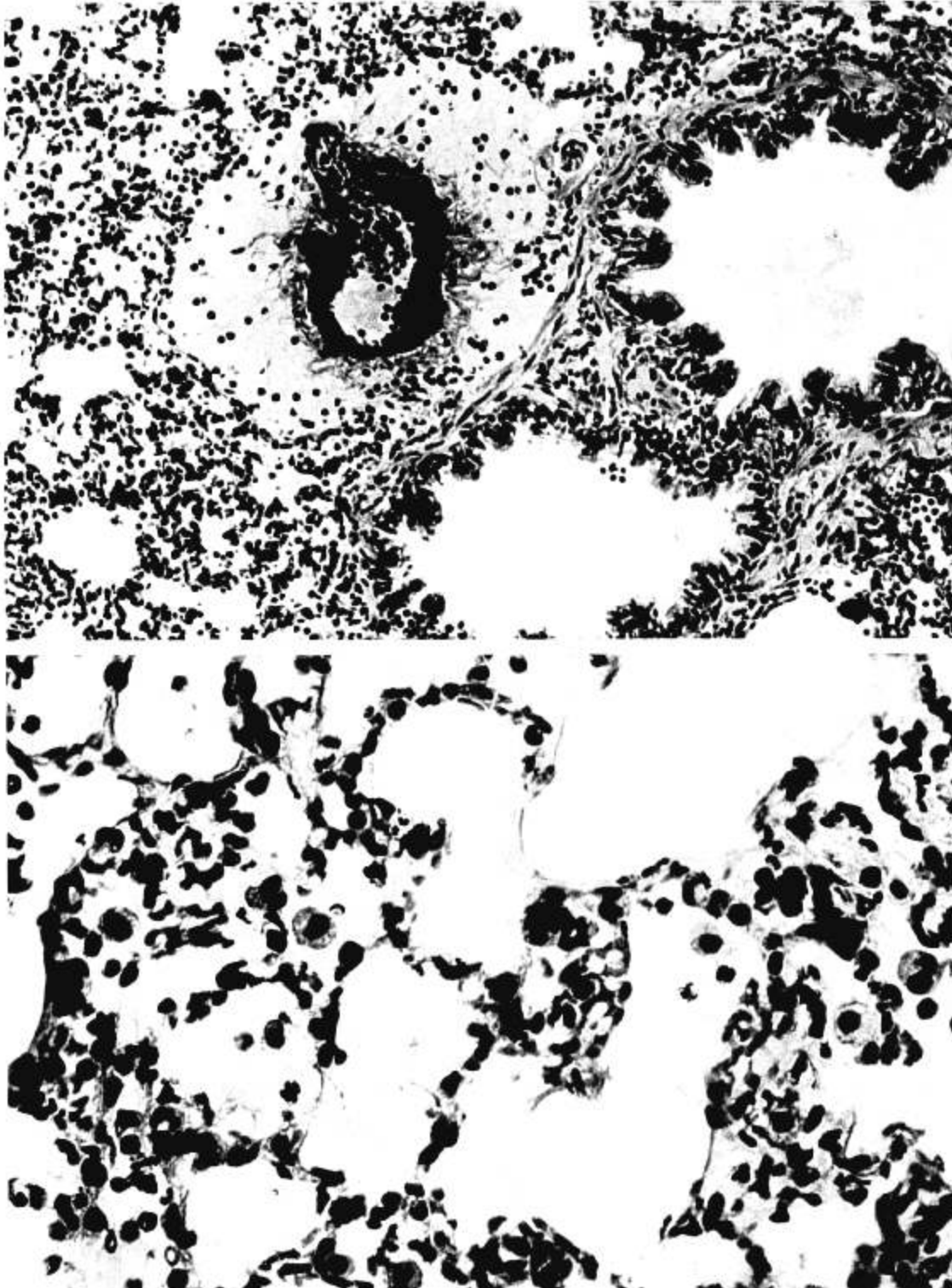


FIG. 2. Section of lung from a rat after aspiration of gastric fluid at pH 1.4. The perivascular interstitial space is edematous. The edema fluid stains a light pink and has a vacuolated or bubbly appearance in fixed tissues. A few inflammatory cells are present. $\times 80$.

FIG. 3. Section of lung from a rat after aspiration of gastric fluid at pH 1.4. Alveolar flooding is massive. Note the bubbly appearance of the faintly stained fluid. $\times 200$.




FIG. 4. Section of control lung showing the absence of edema in alveoli and perivascular interstitial tissue. The perivascular connective tissue around the pulmonary artery and the accompanying bronchiole is barely discernible. $\times 200$.

specimen was immersed in 10 per cent neutral buffered formalin. Histologic sections were prepared with hematoxylin and eosin stains.

Anesthesia and laryngoscopy were carried out in exactly the same way in the other two groups. Samples of gastric fluid were coded so that the persons who injected the tracheas, or prepared the lungs for histologic examination, were not aware of the groups to which the animals had been assigned. In the acid-treated group, a coded unit (2.5 ml/kg) of the gastric contents from *one* of the 16 parturients who had not received milk of magnesia and whose gastric-fluid pH was 1.4 was injected into the trachea of the anesthetized rat through the 20-g cannula at the time of laryngoscopy. In the antacid-treated group, a coded unit (2.5 ml/kg) of the gastric contents from *one* of the patients who had received milk of magnesia and whose gastric-fluid pH was 8.7 was injected into the trachea of the anesthetized rat. The recovery, lung excision, lung weight and histologic preparations proceeded exactly as in the control group. The code was not broken until after the conclusion of the experiment.

Results

Five of the 16 parturients who had not received milk of magnesia had gastric contents in excess

of 25 ml and gastric-fluid pH values of less than 2.5 and could therefore be considered at risk.⁵ Effective neutralization to pH values greater than 2.5 occurred in the first 10 min after ingestion of milk of magnesia and persisted for at least 80 min in 94 of 99 parturients (fig. 1). Five of the parturients who received milk of magnesia had more than 25 ml of gastric fluid with pH values below 2.5. All of these parturients had received the antacid more than 80 min prior to collection of the sample of gastric contents.

The LW/BW ratio of the antacid-treated group was significantly greater than that of the control group (table 1). The LW/BW of the acid-treated group is significantly greater than that of either the control group or the antacid-treated group. Histologic sections of the lungs revealed significant vascular

TABLE 1. Comparative Lung-weight-to-body-weight Ratios (LW/BW) in Control, Antacid-treated and Acid-treated Rats

	LW/BW* (g/g $\times 10^{-3}$)	Student <i>t</i> Test for Unpaired Data
Control (n = 11)	5.3 \pm 0.0	Control vs. acid, 3.6†
Antacid (n = 20)	6.4 \pm 0.1	Control vs. antacid, 4.2†
Acid (n = 39)	8.0 \pm 0.3	Acid vs. antacid, 2.9†

* Mean \pm 1 SEM.

† $P < 0.005$.

congestion, perivascular interstitial edema, alveolar edema, and focal acute inflammation in the acid- and antacid-treated groups, with no apparent difference between the groups (figs. 2 and 3). The control animals showed no acute inflammatory or injury reaction (fig. 4).

Discussion

Mendelson,¹⁰ in his classic description of the acid-aspiration syndrome, suggested using warm antacids as neutralizers. The implementation of this prophylactic measure into clinical practice awaited the work of Taylor and Pryse-Davies,⁶ which appeared 20 years later. They found that 42 per cent of 52 parturients who had not received an antacid had gastric-fluid *pH* values of less than 2.5, and 69 per cent had volumes greater than 40 ml. Antacid ingestion had little effect on volume, but following administration of aluminum hydroxide only 12 per cent had gastric-fluid *pH* values of less than 2.5, and following administration of magnesium trisilicate no patient had gastric-fluid *pH* values of less than 2.5. In addition, they found a lower incidence and a milder form of pneumonitis in rats receiving intratracheal injections of gastric juice from patients treated with magnesium trisilicate.⁶

Roberts and Shirley,⁵ in a study of 100 patients whose infants were delivered by cesarean section, showed that the oral administration of antacids within four hours of induction of anesthesia did not affect the volume of gastric contents, but significantly increased the *pH*. The number of patients at risk for development of acid aspiration was decreased tenfold by the antacid, Wingel®. Since the antacid was completely effective only for the interval from 50 min to three hours, he recommended repeating its administration every three hours during labor in those patients for whom general anesthesia could be anticipated. Parturients who will ultimately need general anesthesia for emergency obstetric operations are frequently impossible to identify as early as 50 min prior to induction; therefore, we sought a quick-acting antacid that could be used in a single dose 10 to 50 min prior to induction of anesthesia. Milk of magnesia and sodium bicarbonate are the most rapid-acting of the commercially available antacids.⁷ Milk of magnesia is insoluble and not absorbed; therefore, it has a longer duration of neutralizing activity within the stomach than does sodium bicarbonate. The only disadvantages of milk of magnesia are its objectionable taste and its tendency to cause diarrhea.

The arbitrary "at risk" criteria of Roberts⁵ are based on the acidity and volume of the aspirate. Teabeaut¹¹ demonstrated that hydrochloric acid solu-

tions and liquid vomitus from human beings must have a *pH* below 2.5 to produce the acid-aspiration syndrome in rabbits. Roberts and Adamsons (personal communication) suggested that 0.4 ml/kg is the maximum volume of gastric juice of *pH* 1.1 that fails to produce significant changes in the lungs of rhesus monkeys. Based on these two studies, Roberts and Shirley⁵ have proposed that any adult patient with a volume of gastric contents greater than 25 ml and gastric-fluid *pH* less than 2.5 is at risk, in that if that gastric fluid were aspirated acid-aspiration syndrome would develop. Although arbitrary, the at-risk criteria provide a valuable basis for the evaluation of preinduction antacids.^{12,13} By use of these criteria, we found that in the absence of preinduction administration of an antacid, 36 per cent of our patients were at risk, in contrast to Taylor's 42 per cent⁶ and Roberts' 46 per cent.⁵ Milk of magnesia was effective in neutralizing the gastric contents during the interval from 10 to 80 min after ingestion. After 80 min, the residual neutralization was ineffective in some patients.

The animal aspiration pneumonitis response has been used extensively in rabbits,^{11,14} dogs,¹⁵ and rats.⁶ A major limitation of animal work has been the difficulty in quantifying the severity of pneumonitis. The increase in total lung fluid that accompanies aspiration pneumonitis can be expected to increase lung weight. This increased lung fluid is probably best measured by a ratio of wet weight to dry weight after desiccation. Desiccation destroys the cellular architecture. We sought a quantitative index of lung weight that would permit us to preserve the lung for histologic examination. The best alternative seemed to be to relate the wet weight of the lung back to the original body weight. Unfortunately, the histologic estimation of the severity of the pneumonitis did not show statistically significant correlation with LW/BW ratio, and the acid and antacid groups could not be distinguished histologically. The magnitude of weight gain by the lungs allowed us to discriminate between the three groups with a high degree of confidence. The lungs of the antacid-treated group were on the average 112 mg heavier than lungs of the control group/kg of body weight. The lungs of the acid-treated group averaged 1570 mg heavier than the lungs of the control group/kg of body weight. The additional lung weight in the acid- and antacid-treated groups was due to congestion, inflammation, and interstitial and alveolar fluid accumulation. Since these features constitute a descriptive histologic definition of aspiration pneumonitis, one can conclude that the pneumonitis was more severe in the antacid-treated group than in the control group, and most severe in the acid-treated group.

The possibility exists that the time course of the development or resolution of aspiration pneumonitis was modified by the presence of the antacid, but the ultimate severity might have been similar. This possibility cannot be resolved from our observations, which were made at four hours and should be considered valid only for four hours. No doubt exists that aspiration of antacid-neutralized gastric contents can result in pneumonitis. This phenomenon has been demonstrated in animals⁶ and in man.¹⁶ Our findings indicate that aspiration of antacid-neutralized gastric contents produce less severe pneumonitis than aspiration of acidic gastric contents. Gibbs *et al.*⁹ in a study of dogs, found that aspiration of hydrochloric acid at pH 1.8 produced effects on PaO₂ and shunt fraction similar to those of aspiration of an antacid saline mixture at pH 8.3. In addition, the most dramatic histologic lesions occurred with aspiration of antacid.

Our observations apply only when milk of magnesia is used as a preinduction antacid. The possibility exists that different antacids have different effects on the lungs when aspirated. Kuchling *et al.*^{**} studied the effect of intratracheally injected antacids in rabbits. Titalac[®] produced mild pneumonitis, Riopan[®] and Maalox[®] produced severe pneumonitis, and Gelusil[®] produced intermediate pneumonitis. Probably anesthesiologists should seek a preinduction antacid that is rapid-acting and nontoxic to respiratory tissue rather than relying on commercially available antacids, which contain additives to improve flavor, to suspend insoluble particles, to prevent loss of potency, and to prolong antacid effect.

We conclude that milk of magnesia is an effective preinduction antacid in emergency obstetrical anes-

thesia; that a single oral dose of 30 ml prior to induction will increase the pH of gastric contents to above 2.5 in all patients in the interval from 10 to 80 min after ingestion; and that milk of magnesia-neutralized gastric contents resulted in a less severe form of induced aspiration pneumonitis in rats than did acidic gastric contents.

References

1. Guedel AE: Inhalation Anesthesia. New York, Macmillan, 1937 pp 172
2. Crawford JS: The anesthetist's contribution to maternal mortality. *Br J Anaesth* 42:70-73, 1970
3. Roberts RB, Shirley M: Aspiration during vaginal delivery. *ANESTHESIOLOGY* 40:317, 1974
4. Giesecke AH: General anesthesia for obstetrics. *Dallas Med J* 53:476-479, 1967
5. Roberts RB, Shirley MA: Reducing the risk of acid aspiration during cesarean section. *Anesth Analg (Cleve)* 53:859-868, 1974
6. Taylor G, Pryse-Davies J: The prophylactic use of antacids in the prevention of the acid pulmonary aspiration syndrome. *Lancet* 1: 288-291, 1966
7. Sleisenger MH, Fordtran JS: *Gastrointestinal Disease*. Philadelphia, W. B. Saunders, 1973, p 724
8. Ben M, Dixon RL, Adamson RH: Anesthesia in the rat. *Fed Proc* 28:1522-1527, 1969
9. Proctor E, Fernando AR: Oro-endotracheal intubation in the rat. *Br J Anaesth* 45:139-142, 1973
10. Mendelson CL: Aspiration of stomach contents into lungs during obstetric anesthesia. *Am J Obstet Gynecol* 52:191-205, 1946
11. Teabeaut JR: Aspiration of gastric contents, an experimental study. *Am J Pathol* 28:51-62, 1952
12. Hutchinson BR, Newson AJ: Preoperative neutralization of gastric acidity. *Anaesth Intens Care* 3:198-202, 1975
13. White FA, Clark RB, Thompson DS: Preoperative oral antacid therapy for patients requiring emergency surgery. *South Med J* 71:177-179, 1978
14. Dudley WR, Marshall BE: Steroid treatment for acid aspiration pneumonitis. *ANESTHESIOLOGY* 40:136-141, 1974
15. Downs JB, Chapman RL, Modell JH, et al: An evaluation of steroid therapy in aspiration pneumonitis. *ANESTHESIOLOGY* 40:129-135, 1974
16. Taylor G: Acid pulmonary aspiration syndrome after antacids. *Br J Anaesth* 47:615-617, 1975

⁹ Gibbs CP, Schwartz DJ, Wynne JW, et al: Antacid pulmonary aspiration (abstr), Society of Obstetric Anesthesia and Perinatology, Annual Meeting, 1978, p 26.

^{**} Kuchling A, Joyce TH, Cook S: The pulmonary lesion of antacid aspiration. (abstr). American Society of Anesthesiology, Annual Meeting, Chicago, 1975, p 281.