

3. Erdemir HA, Sopper LE, Sweet RB: Studies of factors affecting peridural anesthesia. *Anesth Analg (Cleve)* 44:400-404, 1965
4. Schulte-Steinberg O, Rahlfs VW: Spread of extradural analgesia following caudal injection in children. A statistical study. *Br J Anaesth* 49:1027-1034, 1977
5. Eidelberg EE: Cardiovascular response to experimental spinal cord compression. *J Neurosurg* 38:326-331, 1973
6. Greenhoot JH, Shiel FO, Mauck HP: Experimental spinal cord injury. *Arch Neurol* 26:524-529, 1972
7. Alexander S, Kerr FWL: Blood pressure response in acute compression of the spinal cord. *J Neurosurg* 21:485-491, 1964
8. Clark CJ, Whitwell J: Intraocular hemorrhage after epidural injection. *Br Med J* 2:1612-1613, 1961
9. Moore DC: *Regional Block*. Fourth edition. Springfield, Ill., Charles C Thomas, 1976, pp 22-23

Anesthesiology  
51:84-86, 1979

## Chronic Arsenic Poisoning, A Problem in Anesthetic Management

IAN REES, M.D.,\* MILTON ADELMAN, M.D.,† VASILIOS PRATILAS, M.D.‡

Anesthesiologists are occasionally confronted by patients who have cutaneous disorders that affect anesthetic management. Epidermolysis bullosa has frequently been a problem.<sup>1,2</sup> Other dermatologic problems of concern to the anesthesiologist include pemphigus, scleroderma, neurofibromatosis, congenital anhidrotic ectodermal defect, and mastocytosis. These have been well described by Zackheim *et al.*<sup>3</sup>

The medical literature appears to contain no reference to chronic arsenism, with its associated cutaneous disorders, as an anesthetic problem. This report presents the anesthetic considerations in a case of a patient who had chronic arsenism. A further anesthetic problem in this case was previous tracheal resection for carcinoma due to chronic arsenism.

### REPORT OF A CASE

A well-nourished, 50-year-old white woman was admitted for excision of a large ulcerating mass on the right posterior chest wall.

Past history revealed that psoriasis had developed when the patient was 20 years old. Her dermatologist had treated her with a combination of x-ray and Fowler's solution (1 per cent potassium arsenite solution). The psoriasis had abated and the patient had terminated her medical supervision but continued to take daily doses of Fowler's solution for the next ten years.

In 1964, a cutaneous lesion developed at the base of the neck. It was excised and diagnosed as a granuloma secondary to chronic arsenism. In 1970, the patient was admitted to another hospital with a four-week history of dyspnea and increasing stridor following an upper respiratory infection. Bronchoscopy revealed a mass below the vocal cords, about 4 cm above the carina. Biopsy demonstrated a

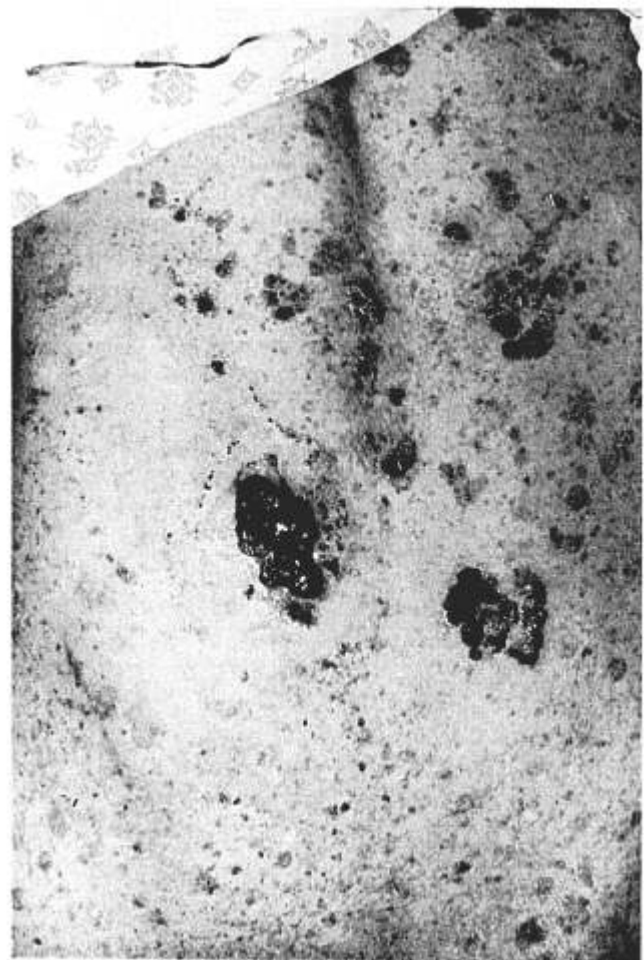


FIG. 1. Posterior chest wall, showing hyperpigmentation, multiple keratoses, and ulcerating squamous-cell carcinoma, secondary to chronic arsenism.

squamous-cell carcinoma extending into the paratracheal region. Subsequently, the entire tumor was removed through a right anterior thoracotomy. Reconstruction of the tracheal wall necessitated the use of a small plastic implant. In the immediate post-operative period, it was clear that paralysis of the right vocal cord

\* Chief Resident.

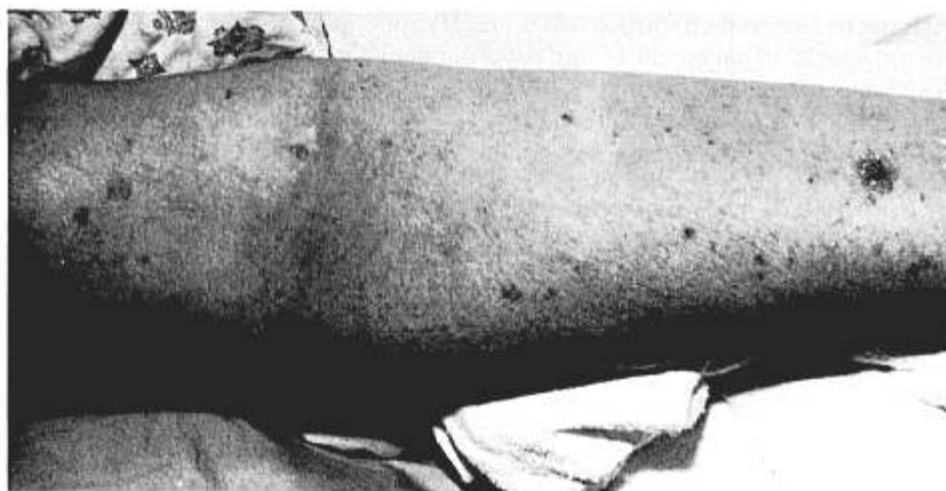† Clinical Professor.

‡ Associate Clinical Professor.

Received from the Department of Anesthesiology, Mount Sinai School of Medicine, C.U.N.Y., New York, New York. Accepted for publication December 3, 1978.

Address reprint requests to Dr. Pratilas: Department of Anesthesiology, Mount Sinai Medical Center, One Gustave L. Levy Place, New York, N. Y. 10029.

FIG. 2. Arm, showing pigmented keratoses and granulomatous formation at sites of earlier venipunctures.



had developed, probably due to section of the right recurrent laryngeal nerve. The patient's convalescence was otherwise satisfactory. At a later date, a Teflon preparation was injected into the paralyzed right vocal cord, with some improvement in speech. The patient remained in good general health to the time of the present admission.

Physical examination revealed an ulcerated, fungating mass on the right posterior chest wall, measuring  $5 \times 3 \times 2$  cm (fig. 1). Approximately 90 per cent of the surface of the skin showed hyperpigmentation and numerous keratotic lesions. The hyperpigmentation and keratoses were the result of chronic irritation by clothing, minor trauma, and prolonged pressure. In figure 2, pigmented keratoses resulting from earlier venipunctures can be seen. One of these keratoses was large enough to require surgical excision, and proved to be a squamous-cell carcinoma.

The remainder of the physical examination was unremarkable. However, hyperextension of the head and neck produced mild stridor and respiratory distress, probably due to a narrowing of the trachea at the site of the reconstruction. Results of hematologic, urinary and blood chemistry studies were all within normal ranges.

Premedication was with diazepam (15 mg), given orally two hours before operation. Intraoperative monitoring was selectively restricted to a blood pressure cuff and continuous electrocardiographic observation. The use of adhesive tape was avoided to minimize trauma to the skin. Similar considerations precluded the use of an intravenous infusion. A no. 4 black rubber anesthetic mask was applied after covering the points of facial contact with non-abrasive cotton wadding. Anesthesia was induced and maintained with 3 per cent enflurane,  $N_2O$  (6 l/min) and  $O_2$  (4 l/min). A good airway was maintained without the use of an oropharyngeal device or an endotracheal tube. The patient was placed in the left lateral position and a radical excision of the mass in the chest wall was performed. The operation, postanesthetic period, and convalescence were without complication.

The pathology report indicated that the excised mass was a basal-cell carcinoma with granulomatous tissue formation secondary to chronic arsenism.

#### DISCUSSION

Arsenic has been used for centuries in the treatment of a variety of disorders. Arsenical cancer is most often due to arsenical medication.<sup>4</sup> About 7 per cent of patients with cutaneous cancers have been exposed to

arsenic.<sup>5</sup> Arsenical keratoses, hyperpigmentation, and carcinoma tend to localize in areas of chronic irritation and minor trauma. Mechanical stimulation is an important factor in determining the site of development of arsenical epitheliomas.<sup>6</sup> Some investigators indicate that arsenic produces a generalized neoplastic diathesis of the skin, with cancer formation following nonspecific injuries.<sup>7</sup>

Our patient manifested this diathesis with numerous keratoses and granulomatous lesions at the sites of previous injections, both iv and im. We felt that regional anesthesia was contraindicated for this patient, due to the lack of healthy skin and the risk of transplanting premalignant or malignant cells. General anesthesia was selected as the anesthetic technique. The primary consideration in the management of our patient was to avoid trauma to the skin. Thus, injections were avoided, although we were prepared for an immediate iv infusion if operative or anesthetic circumstances made it imperative. For similar reasons we avoided the use of im premedications. Antisialagogues were avoided to reduce excessive dryness of the orotracheal mucous membranes and possible injury.

Although the skin is the tissue most commonly affected in chronic arsenism, the mucous membranes of the mouth, respiratory tract and esophagus are frequently involved. Our patient had had a resection of a tracheal squamous-cell carcinoma secondary to arsenism. Therefore, we considered it prudent to avoid the use of an oropharyngeal airway or an endotracheal tube if adequate ventilation could be ensured without them. We were prepared, however, for the immediate use of an airway should a ventilatory problem develop. We suggest that pharyngeal airways, endotracheal tubes and laryngoscopic blades, if used, be well covered with a water-soluble lubricant, and that

their use be undertaken with extreme care. Happily, in the anesthetic management of our patient, no airway device was necessary.

#### REFERENCES

1. Hamman RA, Cohen PS: Anesthetic management of a patient with epidermolysis bullosa dystrophica. *ANESTHESIOLOGY* 34:389-390, 1971
2. Pratilas V, Biezunski A: Epidermolysis bullosa manifested and treated during anesthesia. *ANESTHESIOLOGY* 43:581-583, 1975
3. Zackheim HS, Rudzinski DJ, Katz J, et al: Skin and bone

disorders, Anesthesia and Uncommon Diseases. Edited by J Katz, LB Kadis. Philadelphia, London, W. B. Saunders Co., 1973

4. Sanderson KV: Arsenic and skin cancer, *Cancer of the Skin*. Edited by R Andrade, S Gumport, G Popkin, et al. Philadelphia, London, Toronto, W. B. Saunders Co. 1976, pp 473-491
5. Arhelger SW, Kremen AJ: Arsenical epitheliomas of medicinal origin. *Surgery* 30:977-983, 1951
6. Sommers SC, McManus RG: Multiple arsenical cancers of skin and internal organs (review). *Cancer* 6:347-362, 1953
7. Bungeler W: Tierexperimentelle und zellphysiologische Untersuchungen zur Frage der allgemeinen Geschwulstdisposition. *Frankfurt Z Pathol* 39:314-319, 1930

Anesthesiology  
51:86-87, 1979

## Intracranial Hypertension Caused by Nitroglycerin

ROBERT L. GAGNON, M.D.,\* M. LOU MARSH, M.D.,\* RANDALL W. SMITH, M.D.,†  
HARVEY M. SHAPIRO, M.D.‡

Nitroglycerin has gained widespread acceptance as a drug for control of myocardial ischemia, as well as for induction of hypotension during anesthesia and operation.<sup>1,2</sup> We observed a brisk increase in intracranial pressure (ICP) following the use of nitroglycerin for cardiac therapy in a patient with intracranial hypertension. This observation suggests a need for caution when using nitroglycerin in management of patients who have intracranial hypertension.

#### REPORT OF A CASE

A 67-year-old white man (height 183 cm, weight 88 kg) who had a preoperative diagnosis of posterior-fossa brain tumor, obstructive hydrocephalus, and intracranial hypertension was scheduled for craniotomy. The medical history included essential hypertension, well controlled with Diazide® (50 mg triamterene, 25 mg hydrochlorothiazide), one tablet daily, biweekly episodes of angina pectoris relieved by sublingually administered nitroglycerin, and residual paresis of the right leg following a cerebrovascular accident, which had occurred six months prior to admission. Dexamethasone (4 mg, four times a day) was started two days preoperatively to control symptoms of intracranial hypertension.

With informed consent, the patient agreed to participate in a double-blind study of the effects on ICP of an intravenously administered benzodiazepine premedicant. The protocol included administration of this drug or a placebo 45 min prior to induction of anesthesia. ICP (via ventricular catheter), arterial pressure (BP),

central venous pressure (CVP), and electrocardiogram (ECG) were monitored during the 45-min observation period and intraoperatively. All monitored physiologic indices were continuously recorded on a Hewlett-Packard polygraph.

Forty-five minutes after receiving either the premedicant or placebo, iv, BP was 150/95 torr; ICP, 12 torr. A borderline-normal cerebrospinal fluid volume-pressure response was elicited at this time; 20 sec after the injection of 1 ml sterile saline solution into the ventriculostomy, an increase in ICP to 4 torr above baseline occurred (abnormal response, ICP gain >5 torr).<sup>3</sup> Anesthesia was then induced with thiopental, 250 mg. Pancuronium bromide, 8 mg, was given iv and hyperventilation initiated. Anesthesia was maintained with incremental doses of thiopental (460 mg total) and an inspired gas mixture of 60 per cent N<sub>2</sub>O in O<sub>2</sub>. When PaCO<sub>2</sub> was 21 torr, halothane 1 per cent was added to the inspired mixture for 10 min and, thereafter, the concentration was increased to 2 per cent.

After 18 min (10 min at 1 per cent, 8 min at 2 per cent) of exposure to halothane, a transient tachyarrhythmia developed; it spontaneously reverted to a sinus pattern. However, there appeared marked ST-segment depression and QRS widening. Since myocardial ischemia was suspected, 1 ml 0.08 per cent solution of nitroglycerin (equivalent to two tablets administered sublingually) was given intranasally on two separate occasions. Figure 1 shows the responses of BP and ICP to both doses. The ICP prior to the first dose of nitroglycerin was 18 torr. This climbed to a peak of 40 torr within 2½ minutes of nitroglycerin administration. Removal of 5 ml cerebrospinal fluid (CSF) curtailed a further increase in ICP. Following the first dose of nitroglycerin, blood pressure increased from 120/80 to 135/85 torr within 30 sec, but then decreased to 100/60 torr after 2 min.

Since the ECG was unchanged, a second dose of nitroglycerin was given 8 min after the first. After the second dose, ICP increased from 22 to 48 torr within 2½ min. Blood pressure initially increased from 122/80 to 175/100 torr within the first minute, but then decreased to 120/60 torr after 2½ min. To offset intracranial hypertension, 200 mg thiopental were given iv when ICP was highest. This produced reductions in both ICP and BP to 16 and 80/45 torr, respectively. The ECG returned to its preanesthetic configuration. With laryngoscopy and intubation, blood pressure increased without the appearance of ischemic ECG changes.

\* Assistant Professor of Anesthesia.

† Associate Professor of Surgery/Neurosurgery.

‡ Associate Professor of Anesthesia and Surgery/Neurosurgery.

Received from the Departments of Anesthesiology and Surgery, Division of Neurosurgery, Veteran's Administration Hospital and the University of California, San Diego, California. Accepted for publication December 3, 1978.

Address reprint requests to Dr. Shapiro: Department of Anesthesiology, Veterans Administration Hospital, 3350 La Jolla Village Drive, San Diego, California 92161.