

Title : AXILLARY ARTERIAL CATHETERIZATION

Authors : C. W. Bryan-Brown, M.D., P. D. Lumb, M.D., K. S. Kathirithamby, M.D.,
B. Shapiro, M.D., and S. Azer, M.D.

Affiliation: Surgical and Respiratory Intensive Care Unit, Departments of Anesthesiology and
Surgery, Mount Sinai School of Medicine, City University of New York,
New York 10029

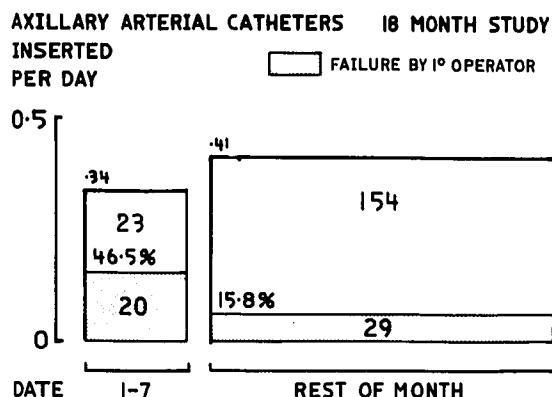
Introduction. In the past nine years over one thousand axillary arterial catheters have been used for routine invasive blood pressure monitoring in an adult multidisciplinary intensive care unit. The patient comfort, convenience and catheter longevity, with extremely low incidence of serious complication led us to perform a more detailed study, through 1977 and 1978. The effect of experience on the failure rate was analyzed.

Methods. All catheters are inserted by the Seldinger technique into the third part of the axillary artery by medical students and PGY 1 and PGY 2 residents. They are closely supervised until proficient. If a trainee fails to insert a catheter by the second attempt, or before if deemed necessary, it is the duty of the supervisor to take over. The left side is used whenever possible.

Results. 251 arterial catheters were used, 245 (97.6%) into the axillary artery, two-thirds on the left side.

Attempts at Insertion		
1	139	(56.7%)
2	73	(29.8%)
>2	33	(13.5%)
	245	

63 (25.7%) were inserted by a secondary operator and there were 4 (1.6%) complete failures. An 18 month study indicated that the trainee failure rate was higher at the beginning of the month, when they had just arrived. (Figure 1)



The duration of catheterization is shown in Figure 2. One quarter of the catheters were in over a week and three for three weeks.

	Removal	
	#18	#20
Total	115	130
Malfunction	6 (5.2%)	21 (16.2%)
Leak	1 (0.9%)	5 (3.8%)
Accidental	3 (2.6%)	-

Malfunction=clotting, kinking or not transmitting arterial trace. Leak=blood oozing around catheter. No sepsis could be attributed to arterial catheters, but 7 were removed as a precaution in septic patients. One patient in cardiogenic shock (CI=0.8L/min/m²) required a distal embolectomy under local anesthesia to restore circulation to the hand. She died three weeks later of her heart condition. Prior to this series a patient presented a mycotic aneurysm of the subclavian artery which was excised without problem. She had a catheter inserted for four days three weeks before, just after brachial angiography.

Discussion. The use of the axillary arterial catheter for monitoring has been reported on a limited scale.^{1,2} The fear of flushing foreign material into the cerebral circulation may have made people wary and would preclude its safe use outside special care areas. The third part of the axillary artery is not an end-artery because of scapular anastomoses, and the site does not have to be splinted to maintain catheter function. In conclusion, we suggest that the axillary arterial catheter is suitable for long term use in adult special care units by those familiar with the Seldinger technique. The serious complication rate in our hands is low, less than one or two cases in 1,000 and there has been no loss of life, limb or digit.

References.

1. Adler DC, Bryan-Brown CW: Use of axillary artery for intravascular monitoring. Crit Care Med 1:148-150, 1973
2. De Angelis, J: Axillary arterial monitoring. Crit Care Med 4:205, 1976

AXILLARY ARTERIAL CATHETERS 1977 & 1978

#18 - 115
#20 - 130 TOTAL - 245

