

Antacid Pulmonary Aspiration in the Dog

Charles P. Gibbs, M.D.,* Daniel J. Schwartz, M.D.,† James W. Wynne, M.D.,‡
C. Ian Hood, M.B., Ch.B.,§ Earlene J. Kuck¶

The amount of damage resulting from pulmonary aspiration of gastric contents is determined primarily by the acidity of the aspirate. Thus, it has been recommended that the pH of stomach contents of pregnant women be increased by the oral administration of antacids prior to anesthesia for delivery. This study was done to investigate the effects of antacid aspiration in dogs and compare these effects with those obtained by trials of aspiration of acid, saline solution, and alkaline saline solution. Mean $P_{a_{O_2}}$ of the saline-treated group had decreased from 81 to 60 torr at 10 min, while that of the alkaline saline-treated group had decreased from 83 to 58 torr. Fractional intrapulmonary physiologic shunt (\dot{Q}_p/\dot{Q}_t) increased in these two groups, from 15 to 34 and from 16 to 42 per cent, respectively. The \dot{Q}_p/\dot{Q}_t had returned to control values in both groups by four hours, and the $P_{a_{O_2}}$ had returned to control values by 24 hours. By contrast, the acid- and antacid-treated groups had decreases in $P_{a_{O_2}}$ values from 77 to 34 torr and from 84 to 46 torr, respectively. Neither group had a return of $P_{a_{O_2}}$ to pre-aspiration level by 24 hours. Likewise, the \dot{Q}_p/\dot{Q}_t increased significantly more in these two groups: 14 to 66 per cent in the acid-treated group and 13 to 47 per cent in the antacid-treated group. These changes persisted throughout four hours. The saline and alkaline saline aspirates produced little histologic damage. The acid aspirate produced hemorrhage, exudates, and edema. However, these changes were no longer present a month later. The antacid aspirate produced a marked bronchopneumonia that was still present as a chronic inflammatory reaction after a month. These findings indicate that antacids can cause pulmonary damage when aspirated. (Key words: Anesthesia, obstetric. Complications: aspiration, antacid. Lung: aspiration.)

SINCE THE WORK OF MENDELSON¹ in man and rabbits, it has generally been believed that pulmonary dysfunction subsequent to aspiration of gastric contents is caused by gastric acid. Using acid solutions of various pH values in rabbits, Teabeaut² demonstrated that aspirates at pHs of less than 1.5 caused severe histologic changes and that those with pHs of more than 2.4 caused little or no damage; the severity of pulmonary damage caused by aspirates having pH

values between these two levels varied directly with acidity. Because of these findings, Roberts and Shirley and others have suggested that oral antacid preparations be administered routinely to women in labor and to others predisposed to aspiration to increase the pH of gastric contents to above 2.5 and thereby prevent the consequences of pulmonary aspiration.³⁻⁷ However, the possibility that antacids themselves may be injurious to the lung has not been fully investigated. Our study has evaluated the severity of pulmonary damage caused by aspiration of an antacid and compared the changes with those occurring in control groups aspirating saline solution and acid.

Methods and Materials

Forty-one healthy mongrel dogs, fasted overnight, were studied. All animals had $P_{a_{O_2}}$ s of more than 70 torr in arterial blood samples obtained while they were awake and breathing room air prior to study. Each animal was placed in the supine position, anesthetized with sodium pentobarbital, 25 mg/kg, intravenously, and the trachea intubated with a large-volume, low-pressure, cuffed tube. Anesthesia was maintained with 30-60-mg supplemental doses of sodium pentobarbital. An esophageal temperature probe, femoral-artery catheter, and balloon-tipped pulmonary-artery catheter were positioned, and systemic and pulmonary arterial pressures were monitored continuously on a Grass Model 5 polygraph. Arterial and mixed venous blood were sampled for determinations of P_{O_2} , P_{CO_2} , pH, and hematocrit, prior to aspiration and 10, 30, 60, 90, 120, 180, and 240 min after aspiration. Arterial blood-gas measurements were made on an Instrumentation Laboratories Model 113 blood-gas analyzer and were corrected for ambient barometric pressure and the animal's body temperature.⁸ These data were used to calculate arteriovenous oxygen content difference [$C(a-\bar{v})_{O_2}$] and fractional intrapulmonary physiologic shunt (\dot{Q}_p/\dot{Q}_t), using the method of Ruiz *et al.*⁸

With the animal supine and tilted about 30 degrees to one side, a Coudé polyethylene catheter was inserted through the endotracheal tube to a depth of approximately 40 cm. Using gentle pressure, the aspirate, 1 ml/kg, was delivered through the catheter to the dependent lung. The process was then repeated for the opposite lung, providing a total dose of 2

* Associate Professor of Anesthesiology and Obstetrics and Gynecology.

† Clinical Fellow in Pulmonary Medicine.

‡ Associate Professor of Medicine and Anesthesiology.

§ Professor of Pathology.

¶ Assistant in Anesthesiology.

Received from the Departments of Anesthesiology, Obstetrics and Gynecology, Medicine (Pulmonary Division), and Pathology, University of Florida College of Medicine, Gainesville, Florida. Accepted for publication May 29, 1979. Supported in part by Public Health Service Pulmonary Academic Award K07 H100122 from the National Heart, Lung, and Blood Institute.

Address reprint requests to Dr. Gibbs: Department of Anesthesiology, University of Florida College of Medicine, Box J-254, J. Hillis Miller Health Center, Gainesville, Florida 32610.

FIG. 1. Measured values of \dot{Q}_s/\dot{Q}_t of animals receiving antacid aspirate differed only slightly from those of animals receiving acid aspirate. Saline and alkaline saline aspirates produced smaller changes, which had reverted to control values by four hours. * $p < 0.05$, HCl and antacid vs. saline; † $p < 0.05$, HCl vs. antacid.

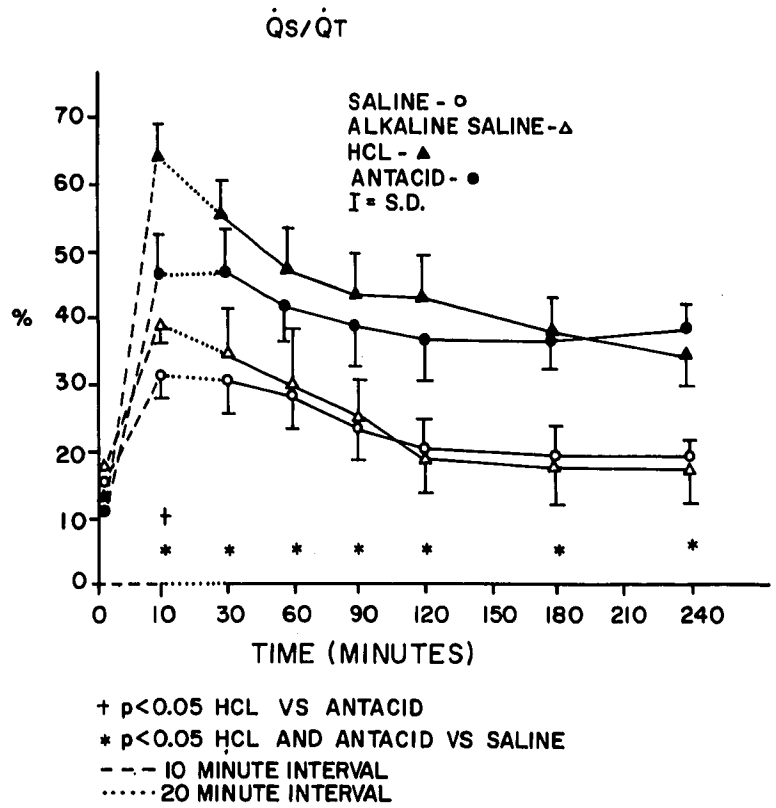
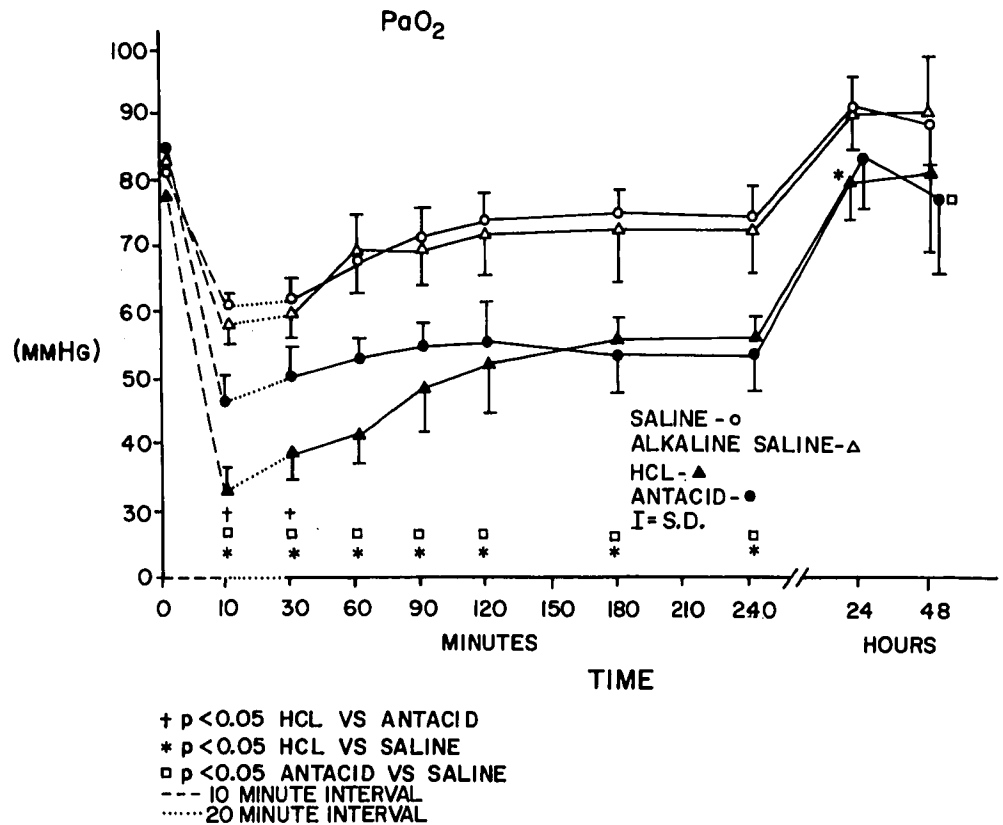


FIG. 2. Measured values of P_{aO_2} of animals receiving antacid aspirate differed only slightly from those of animals receiving acid aspirate. Saline and alkaline saline aspirates produced smaller changes, which had reverted to control values by four hours. * $P < 0.05$, HCl and antacid vs. saline; † $P < 0.05$, HCl vs. antacid.



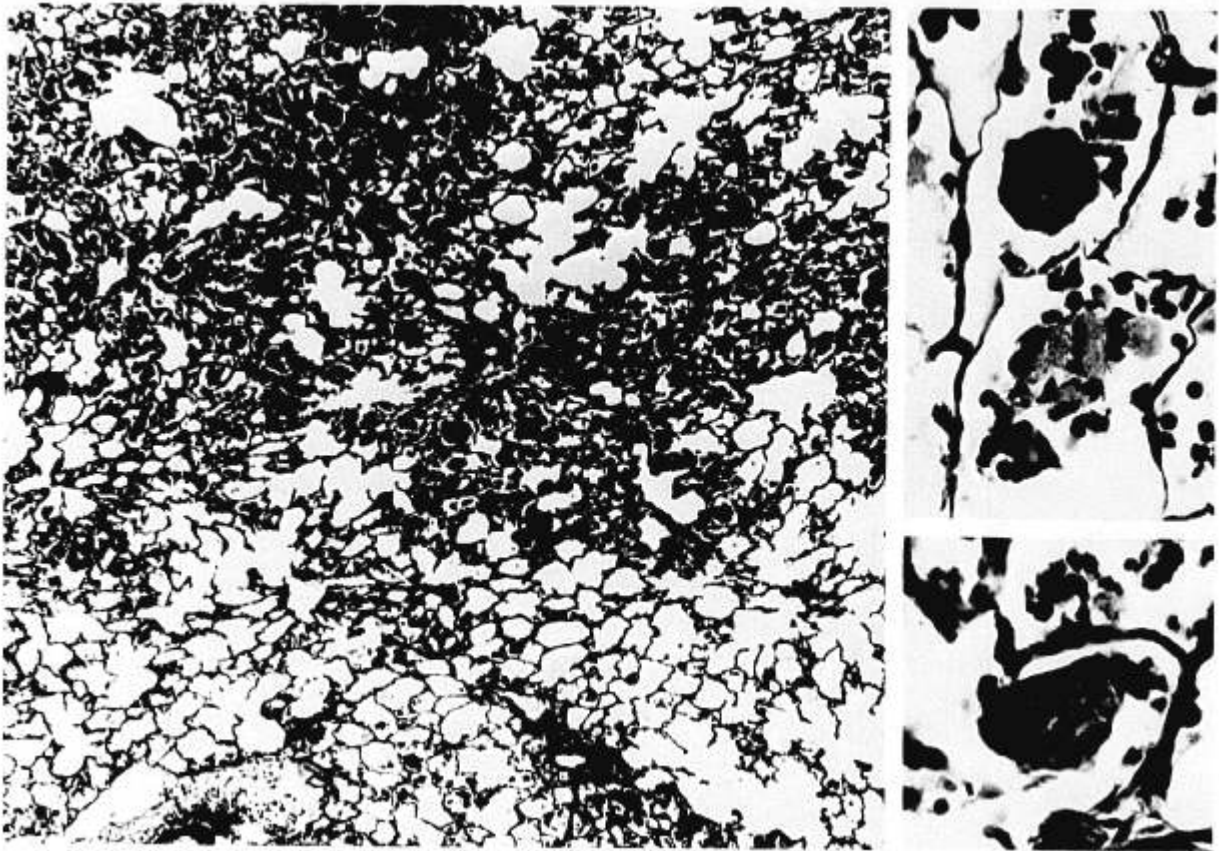


Fig. 3. Group III. Section of lung 48 hours after aspiration of antacid, pH 8.3. Notice extensive bronchopneumonia at left. The majority of alveoli are filled with polymorphonuclear leukocytes and macrophages in approximately equal numbers. Insets at right illustrate large and small intra-alveolar particles surrounded by inflammatory cells (hematoxylin-eosin, $\times 46$, main illustration; $\times 440$, insets).

ml/kg body weight for each animal. Thirteen dogs (Group I) received saline solution, pH 5.9, and were the control group. Eight dogs (Group II) received hydrochloric acid, pH 1.8. Eight dogs (Group III) received an antacid solution, pH 8.3. The antacid used (Kolantyl Gel, 0.5 ml/kg) is a suspension of aluminum hydroxide (30 mg/ml) and magnesium hydroxide (30 mg/ml). It was given with saline solution 1.5 ml/kg, making the total dose 2 ml/kg (pH 8.3). The last eight dogs (Group IV) received saline solution adjusted with sodium hydroxide to pH 8.3. The osmolalities of the aspirates were 281, 39, 308, and 285, respectively.

Following aspiration, the animals received no therapy other than intravenous maintenance fluids. After four hours, pulmonary-artery catheters were removed, the tracheas extubated, and the dogs returned to their cages. Additional arterial blood-gas determinations were made 24 and 48 hours after aspiration. Immediately after the last blood samples were obtained, the animals were sacrificed with a rapid intravenous infusion of sodium pentobarbital, 50 mg/kg, followed by intravenous infusion of potassium chloride, 12 ml, in a saturated solution. The lungs and trachea were removed *en bloc* and im-

mediately inflated and fixed according to the method of Markarian.⁹ A minimum of four tissue samples was obtained randomly from lungs that appeared normal grossly. Otherwise, samples were taken from areas that appeared abnormal. The tissue was sectioned (6 μ m thick) and stained with hematoxylin and eosin. Six additional animals in Groups II (acid) and III (antacid) were sacrificed in a similar manner a month after aspiration. These animals were separate from those utilized to collect physiologic and early histologic data.

Statistical analysis of all physiologic data was performed using Duncan's multiple-range test, the level of significance being $P < 0.05$.

Results

All animals had significant increases in \dot{Q}_s/\dot{Q}_t and concomitant decreases in Pa_{O_2} values within 10 min of aspiration (figs. 1 and 2). In the animals given saline and alkaline saline solutions the decreases in Pa_{O_2} were from 81 to 60 torr and 83 to 58 torr, respectively. The \dot{Q}_s/\dot{Q}_t increased from 15 to 34 per cent in the saline-treated group and from 16 to 42 per cent in the alkaline saline-treated group. In both groups \dot{Q}_s/\dot{Q}_t had returned to baseline by four hours and the

Pa_{O_2} had returned to control values by 24 hours. The \dot{Q}_s/\dot{Q}_t and Pa_{O_2} values for these two groups were not different from each other at any time. By contrast, the animals receiving acid and antacid aspirates showed significantly more severe alterations. They had decreases in Pa_{O_2} values from 77 to 34 torr and from 84 to 46 torr, respectively. Neither group's Pa_{O_2} values had returned to preaspiration levels by 24 hours. Likewise, the \dot{Q}_s/\dot{Q}_t increased significantly more in these two groups: 14 to 66 per cent in the acid-treated group and 13 to 47 per cent in the antacid-treated group. These \dot{Q}_s/\dot{Q}_t changes persisted throughout four hours (figs. 1 and 2).

In Groups I, III, and IV, Pa_{CO_2} and pH values remained unchanged throughout the study. However, the acid-treated group had a mild transient hypercarbia and concomitant acidemia that reverted to baseline within 60 min. Also, no difference in $a-\bar{v}O_2$ contents was found among groups at any sampling time during the study, and little change within groups occurred over time. Although pulmonary arterial pressures increased in all groups immediately after aspiration, they returned to baseline within 10 min. Systemic arterial pressures were unchanged, and none of the animals died during the study period.

Histologic examination of sections of lungs obtained at 48 hours from control animals demonstrated either

completely normal lungs or small, widely scattered foci of inflammatory cells consisting of an admixture of polymorphonuclear leukocytes and macrophages. Sections taken from lungs of dogs in the acid-treated group showed an alveolar exudate consisting of edema, fibrin, hemorrhage, and polymorphonuclear leukocytes. The hemorrhagic pulmonary edema varied from small focal patches to extensive confluent areas in different sections. In a few of these hemorrhagic foci there was some necrosis of alveolar septae. No vascular thrombosis or tissue infarction was found, and no particulate matter was found. All dogs in the antacid-treated group had extensive bronchopneumonia consisting of an exudate (composed of polymorphonuclear leukocytes and macrophages in about equal proportions) that filled the alveoli (fig. 3). Small amphiphilic granular particles (approximately 10–50 μm in diameter) were also found in the exudate. Some were contained within macrophages, and some were the apparent center of an inflammatory response. This reaction was very diffuse and almost confluent in many of the sections. The antacid suspension itself, on wet preparation, was found to contain these pale amphiphilic particles, confirming the antacid as the source of this material (fig. 4). Sections from the lungs of dogs in the alkaline saline-treated group

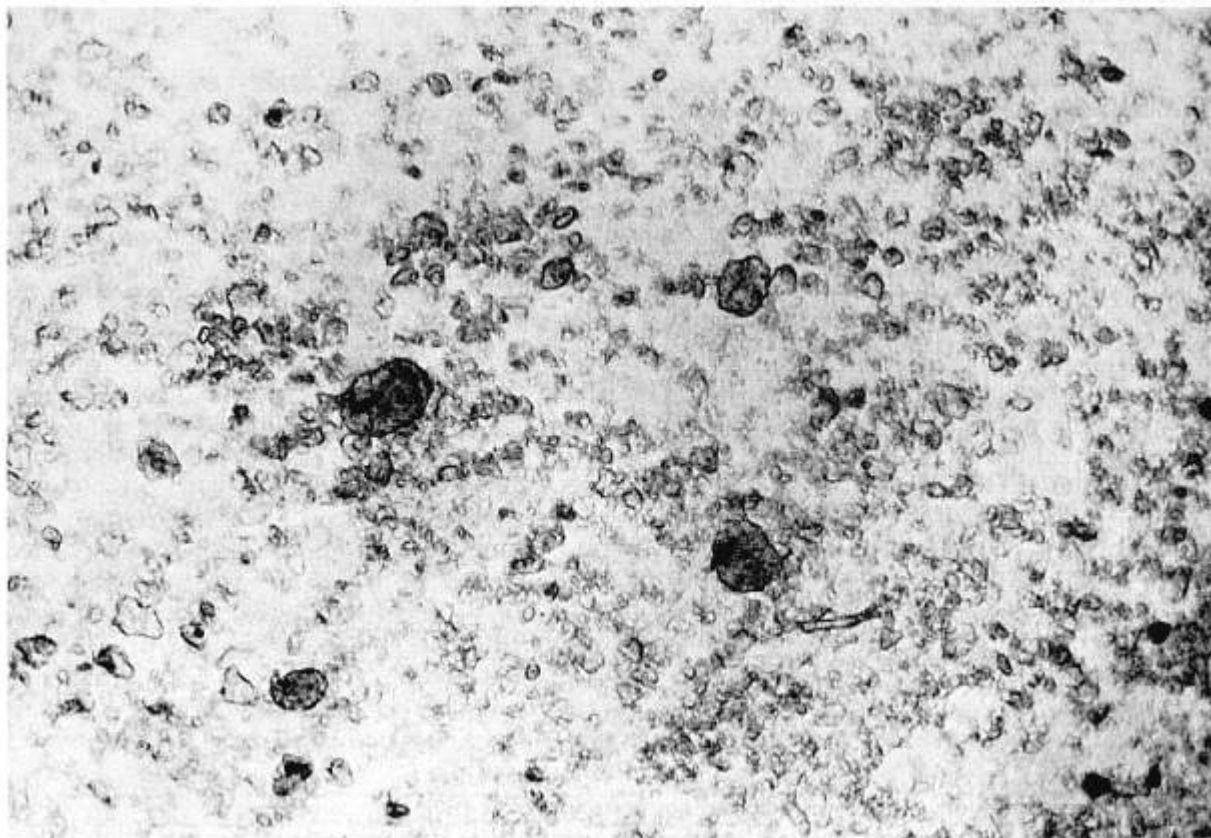


FIG. 4. Notice particles and aggregates of varied sizes in this wet smear of antacid diluted 1:3 with saline solution (unstained $\times 258$).

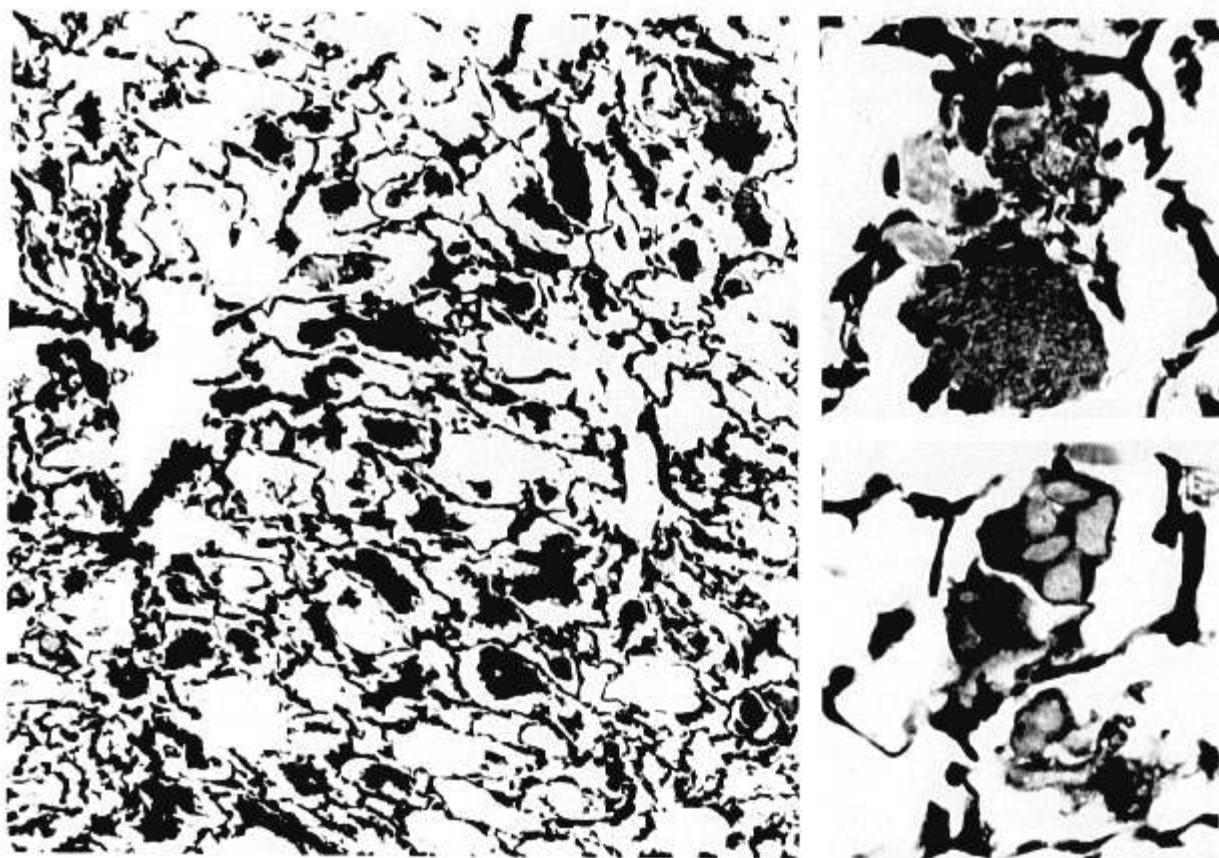


FIG. 5. Group III. Lung one month after aspiration of antacid, pH 8.3. Notice the numerous large intra-alveolar macrophages at left. Insets at right illustrate large granular and smaller pale intra-alveolar particles most of which are contained within macrophages. The pulmonary structure is otherwise normal (hematoxylin-eosin, $\times 155$, main illustration; $\times 563$, insets).

were indistinguishable from those in the saline-treated group, and were either completely normal or had similar small, widely scattered islands of inflammatory cells.

Sections taken at one month from animals that had aspirated acid were essentially normal. All of the sections taken at one month from animals receiving antacid aspirate showed a diffuse, sometimes confluent, intra-alveolar cellular reaction that occasionally extended to the interstitium. This reaction consisted of clusters of large macrophages with abundant granular cytoplasm, in some of which were small amphiphilic particles similar to those found in sections from this group of animals at 48 hours (fig. 5). No fibrosis or other inflammatory reaction was seen.

Discussion

As Teabeaut,² Taylor and Pryse-Davies,¹⁰ and others¹¹ have demonstrated, pulmonary damage due to acid aspiration is severe at pH 1.0–1.4, causing diffuse alveolar septal necrosis, vascular thrombosis, pulmonary infarction, hypoxemia, and death. From pH 1.5 to pH 2.4, damage varies with acidity, and

with acid aspirates at pHs of more than 2.4, the damage is virtually negligible.

Within this framework, Roberts and Shirley,^{3,4} Taylor and Pryse-Davies,⁵ Hester and Heath,⁶ Peskett,⁷ and others have suggested the prophylactic use of antacids in obstetric patients, and have demonstrated the effectiveness of antacids in increasing the pH of gastric contents.^{3,5,7} Investigations into the possible toxicity of aspirating antacid suspension itself have been limited. Taylor and Pryse-Davies⁵ found a peribronchial inflammatory reaction with a predominance of macrophages and occasional foreign-body giant cells in the lungs of rats receiving antacid aspirates. Kuchling *et al.*** found similar changes in rabbits, although they reported no change in arterial blood-gas values as measured in samples from the central artery of the ear.

The antacid suspension we used is similar to that suggested by Roberts and Shirley.⁴ We compared the effects of the aspiration of this antacid solution with those of aspiration of acid at pH 1.8, as this has been

** Kuchling A, Joyce TH III, Cook S: The pulmonary lesion of antacid aspiration (abstr), Annual Meeting, American Society of Anesthesiologists, October 1975, pp 281–282.

studied previously in dogs and had produced a consistently severe hemorrhagic reaction.¹¹ The pH of gastric contents in the nonfasted individual is not usually less than 2.0, and rarely less than 1.5.^{4,12-15} Our animals receiving an aspirate of HCl at pH 1.8 had hemorrhagic pulmonary edema with a few foci of alveolar septal necrosis, which cleared spontaneously without apparent residual damage. Neither vascular thrombosis nor pulmonary infarction was seen. These changes are similar to, but less severe than, changes found by Chapman *et al.* using an acid with a pH of 1.8 as aspirate.¹¹ The reason for the difference in severities may be due to a difference in techniques. We injected our aspirate slowly toward first one lung and then the other, while Chapman *et al.* injected the total dose of aspirate rapidly at the tip of the endotracheal tube.

Animals receiving an aspirate of dilute antacid solution showed changes in PaO₂ and \dot{Q}_s/\dot{Q}_t values after 10 min that were nearly as severe as those seen after aspiration of hydrochloric acid at pH 1.8. The extent and duration of induced hypoxemia were virtually identical. There was no difference in a- $\bar{v}O_2$ content differences among groups at any sampling time, suggesting that the changes seen were not caused by differences in cardiac output. The animals aspirating HCl showed mild to moderate hemorrhagic pulmonary edema at 48 hours and had no significant residual damage to the lung tissue at one month. Animals receiving an antacid aspirate, however, had a severe extensive parenchymal pneumonitis at 48 hours, which was easily distinguishable from the lesions seen with acid aspiration. An extensive intra-alveolar cellular response was seen at one month. Interestingly, this diffuse reaction involving the alveolar spaces and occasionally the interstitium appeared to spare the alveolar and bronchiolar walls. The histologic changes observed at 48 hours in animals aspirating antacid were similar to those described by Taylor and Pryse-Davies,⁵ although they did not report the amphophilic particles in the exudate and macrophages found by us. The diffuse histologic changes we found at one month have not been reported previously.

We demonstrated that the alkalinity of the solution was not the cause of the damage, because animals aspirating saline solution altered with sodium hydroxide had no more physiologic or histologic changes than did control animals. Therefore, something inherent in the antacid suspension caused the severe inflammatory reaction. Antacid suspensions not only contain elemental magnesium and aluminum, but have various preservatives (methylpropyl and butylparaben), stabilizers (methylcellulose), flavoring oils, and sweeteners (sorbitol or saccharin). Which combination of the many com-

ponents of an antacid suspension may be responsible for the inflammatory reaction is not yet known.

At this point, we cannot offer suggestions for clinical practice, but further evaluation of this area is indicated. Different antacids should be studied to determine their potentials to elicit the pulmonary reaction seen after aspiration. An investigation of which components of the antacid solution produce this damage may lead to safer antacid preparations. Efforts to adjust the pH of gastric contents exclusive of antacid preparations (as with hydrogen receptor antagonists) also deserve study. The osmolalities of the various solutions may also play a role in the selection of a benign antacid. We have clearly demonstrated, however, that an antacid suspension itself may cause significant pulmonary damage when aspirated.

References

1. Mendelson CL: The aspiration of stomach contents into the lungs during obstetric anesthesia. *Am J Obstet Gynecol* 52:191-205, 1946
2. Teabeaut JR II: Aspiration of gastric contents. An experimental study. *Am J Pathol* 28:51-67, 1952
3. Roberts RB, Shirley MA: Reducing the risk of acid aspiration during cesarean section. *Anesth Analg (Cleve)* 53:859-868, 1974
4. Roberts RB, Shirley MA: The obstetrician's role in reducing the risk of aspiration pneumonitis. *Am J Obstet Gynecol* 124:611-617, 1976
5. Taylor G, Pryse-Davies J: The prophylactic use of antacids in the prevention of the acid-pulmonary-aspiration syndrome (Mendelson's syndrome). *Lancet* 1:288-291, 1966
6. Hester JB, Heath ML: Pulmonary acid aspiration syndrome: Should prophylaxis be routine? *Br J Anaesth* 49:595-599, 1977
7. Peskett WGH: Antacids before obstetric anaesthesia. A clinical evaluation of the effectiveness of mist, magnesium trisilicate BPC. *Anaesthesia* 28:509-513, 1973
8. Ruiz BC, Tucker WK, Kirby RR: A program for calculation of intrapulmonary shunts, blood-gas and acid-base values with a programmable calculator. *ANESTHESIOLOGY* 42:88-95, 1975
9. Markarian B: A simple method of inflation-fixation and air drying of lungs. *Am J Clin Pathol* 63:20-24, 1975
10. Taylor G, Pryse-Davies J: Evaluation of endotracheal steroid therapy in acid pulmonary aspiration syndrome (Mendelson's syndrome). *ANESTHESIOLOGY* 29:17-21, 1968
11. Chapman RL Jr, Modell JH, Ruiz BC, et al: Effects of continuous positive pressure ventilation and steroids on aspiration of hydrochloric acid (pH 1.8) in dogs. *Anesth Analg (Cleve)* 53:556-562, 1974
12. Shohl AT: Determination of the acidity of gastric contents. I. Determination and significance of acidity. *Johns Hopkins Hosp Bull* 31:152-158, 1920
13. Shohl AT, King JH: Determination of the acidity of gastric contents. II. The colorimetric determination of free hydrochloric acid. *Johns Hopkins Hosp Bull* 31:158-162, 1920
14. Malagelada JR, Longstreth GF, Deering TB, et al: Gastric secretion and emptying after ordinary meals in duodenal ulcer. *Gastroenterology* 73:989-994, 1977
15. Kirsner JB, Palmer WL: The effect of various antacids on the hydrogen-ion concentration of the gastric contents. *Am J Dig Dis* 7:85-93, 1940