

- toxicity: Prolonged enflurane and halothane anesthesia in volunteers. *ANESTHESIOLOGY* 46:265-271, 1977
5. Jain R: Acute renal failure in the neonate. *Pediatr Clin North Am* 24:605-618, 1977
 6. Mazze RI, Cousins MJ: Renal toxicity of anaesthetics: With specific reference to the nephrotoxicity of methoxyflurane. *Can Anaesth Soc J* 20:64-80, 1973
 7. Cohen EN, VanDyke RA: Metabolism of Volatile Anesthetics.

- Implications for Toxicity. Reading, Mass., Addison-Wesley Publishing Co., 1977, p 185
8. Roman RJ, Carter JR, North WC, et al: Renal tubular site of action of fluoride in Fischer 344 rats. *ANESTHESIOLOGY* 46:260-264, 1977
 9. Shen YW, Taves DR: Fluoride concentration in the human placenta and maternal and cord blood. *Am J Obstet Gynecol* 119:205-207, 1974

Anesthesiology
51:467-469, 1979

Anatomic Locations of the Tips of Pulmonary-artery Catheters in Supine Patients

GREGORY M. KRONBERG, M.D.,* STUART F. QUAN, M.D.,† RICHARD M. SCHLOBOHM, M.D.,‡
JAMES M. LINDAUER, M.D.,§ PHILIP C. GOODMAN, M.D.¶

Pulmonary-artery occluded pressure (PAOP) is considered an accurate indicator of left atrial pressure (LAP) under most circumstances.¹⁻³ However, several possible measurement errors can make interpretation and utilization difficult. The importance of referencing the zero point of the transducer to the level of the left atrium is well known. In addition, recent studies have stressed the importance of the vertical location of the distal pulmonary-artery (PA) catheter tip.⁴⁻⁷ They demonstrated that PAOP reflects airway pressure instead of LAP when the catheter tip is positioned vertically above** the left atrium and positive end-expiratory pressure (PEEP) is applied. It has also been demonstrated that when the pulmonary-artery catheter tip is vertically below the left atrium, there is a high correlation between PAOP and LAP even with PEEP as high as 30 cm H₂O.⁴⁻⁶ Benumof *et al.*⁸ reviewed the locations of catheter tips in supine patients by use of anteroposterior roentgenograms, but did not evaluate the true vertical positions of the catheter tips. To clarify the issue of catheter tip location, we utilized both anteroposterior and lateral roentgenograms to locate catheters in supine patients.

METHODS

Thirty patients (ages 26-83 years) admitted to the Medical-Surgical Intensive Care Unit at the San

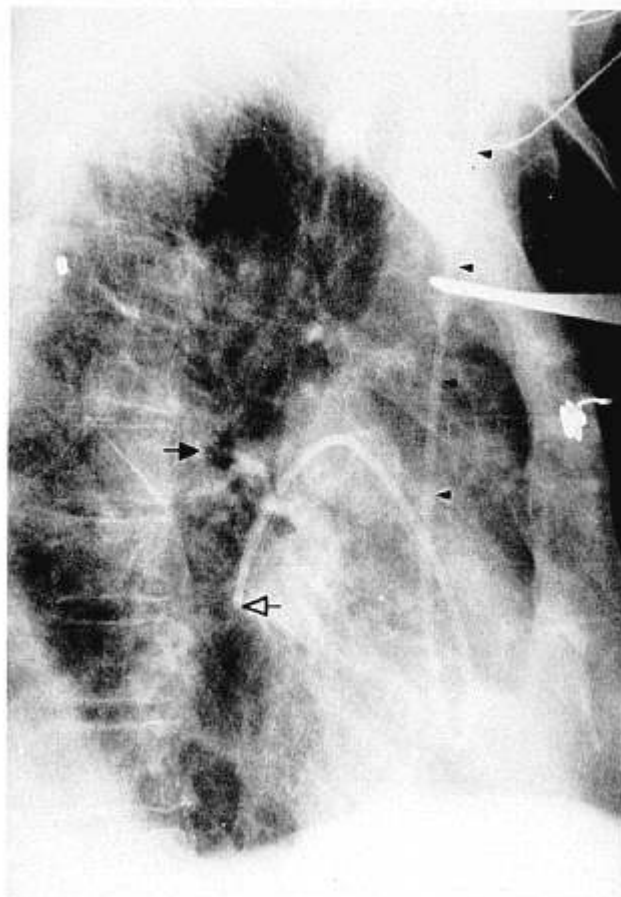


FIG. 1. Roentgenogram of the lateral chest, showing a pulmonary catheter. The course in the superior vena cava is marked by small arrowheads (◄). The catheter tip (◄) and left mainstem bronchus (►) are also marked.

* Intensive Care Fellow, Department of Anesthesia. Current address: Department of Anesthesiology Wilford Hall USAF Medical Center, San Antonio, Texas 78236.

† Intensive Care Fellow, Department of Anesthesia.

‡ Associate Clinical Professor, Department of Anesthesia.

§ Assistant Clinical Professor, Department of Medicine.

¶ Assistant Clinical Professor, Department of Radiology.

Received from the University of California, San Francisco, San Francisco, California 94110. Accepted for publication April 18, 1979.

Address reprint requests to Dr. Schlobohm: Department of Anesthesia, San Francisco General Hospital, San Francisco, California 94110.

** In the supine patient, "vertically above" refers to ventral and "vertically below" refers to dorsal.

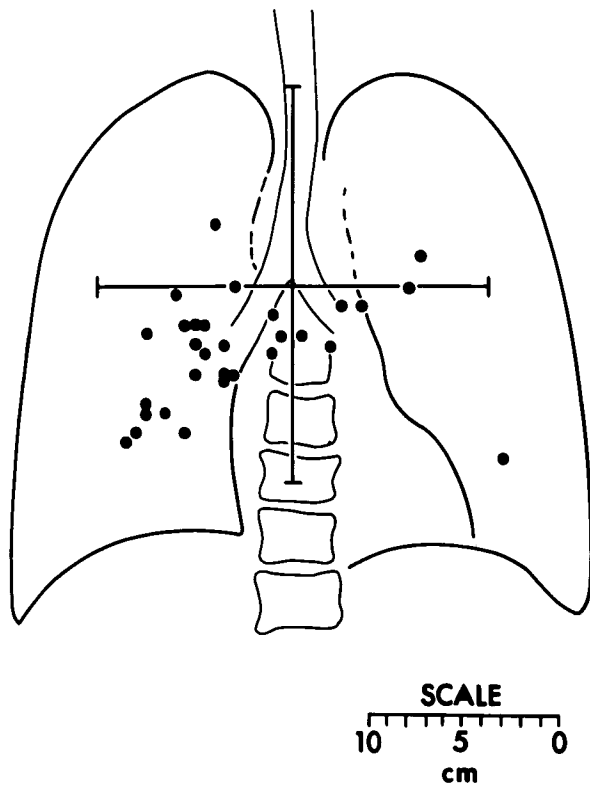


FIG. 2. Distribution of tips of pulmonary-artery catheters on anteroposterior roentgenograms.

Francisco General Hospital had pulmonary-artery catheters placed for clinical indications. At the time of the catheter insertion, 20 patients were being mechanically ventilated for acute respiratory failure, 12 of whom were being treated with PEEP (range 4–12, mean 7 cm H₂O). The catheter was positioned in the most proximal location where PAOP could be measured. Portable anteroposterior and lateral chest roentgenograms were obtained. The position of the catheter tip on the anteroposterior projection was measured relative to the carina and the midline. On the lateral roentgenogram, the route of the catheter through the superior vena cava outlines the anterior border of the left atrium,⁹ and the position of the catheter tip was measured relative to this landmark (fig. 1). In addition, pulmonary arterial pressure, PAOP, and thermodilution cardiac output were measured after catheter insertion.

RESULTS

On anteroposterior roentgenograms (fig. 2), 73 per cent of the catheter tips were located in the right lower quadrant ($P < .005$).^{††} On the lateral view (fig. 3), the

^{††} χ^2 analysis.

tips of the pulmonary-artery catheters were $2.9 \pm .4$ cm (mean \pm SE) vertically below the superior vena cava ($P < .005$).^{††} Using this distance as a measure of posterior location, there was no statistically significant correlation^{‡‡} between catheter tip location and the following variables: cardiac output (range 1.5–11.7 l/min), mean pulmonary arterial pressure (range 11–65 torr), PAOP (range 5–26 torr), or PEEP (range 5–12 torr). The mode of ventilation (spontaneous, mechanical ventilation, mechanical ventilation with PEEP) did not alter the location of the catheter tip relative to the superior vena cava.^{§§}

DISCUSSION

This study showed that in supine patients the placement of most catheter tips is vertically below the superior vena cava and thus at or vertically below the left atrium. In addition, 73 per cent of catheter tips

^{‡‡} Least-squares regression.

^{§§} Two-tailed Student *t* test for unpaired data.

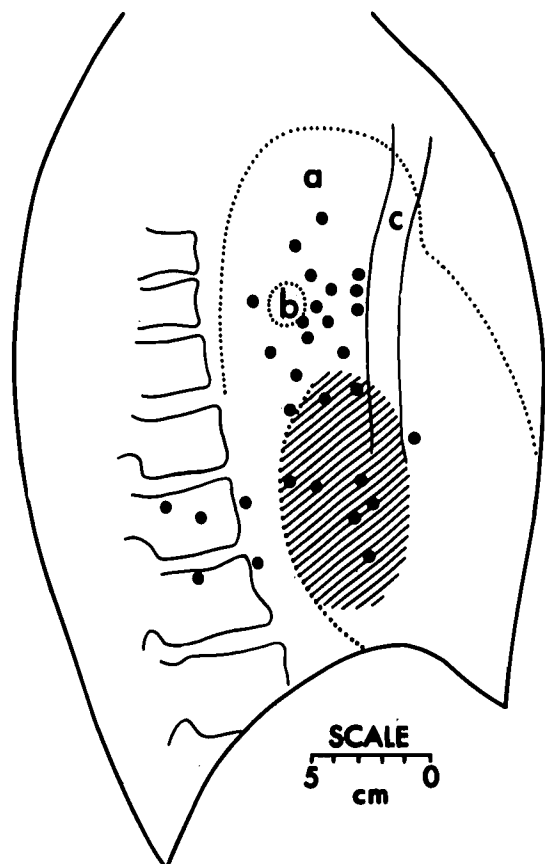


FIG. 3. Distribution of tips of pulmonary-artery catheters on lateral roentgenograms. a = aortic arch; b = left mainstem bronchus; c = superior vena cava. Shaded area is the area of the left atrium.

were located in the right lower quadrant on the antero-posterior roentgenogram, which confirms the observations of Benumof *et al.*⁸

The pulmonary vasculature has primarily been described as being analogous to the Starling resistor.¹⁰⁻¹² A measurement of PAOP that accurately and reliably reflects LAP depends on a patent vascular system between the left atrium and the catheter tip. Early reports of experiences with flotation pulmonary-artery catheters did not mention experience with coincident mechanical ventilation with PEEP. When alveolar pressure increases with mechanical ventilation and high PEEP to cause collapse of the pulmonary vasculature, PAOP will reflect airway pressure. However, PAOP accurately reflects LAP in animals with high PEEP when the catheter tip is vertically below the left atrium.⁴⁻⁶ Combining these findings with those of the present study, PAOP should accurately reflect LAP in supine patients when the transducer is referenced to the left atrium.

The authors gratefully acknowledge the editorial assistance of Ms. Mary Wondra and Ms. Virginia Swim.

REFERENCES

1. Connolly DC, Kirklin JW, Wood EH: The relationship between pulmonary artery wedge pressure and left atrial pressure in man. *Circ Res* 2:434-440, 1954
2. Lappas D, Lell WA, Gabel JC, et al: Indirect measurement of left atrial pressure in surgical patients—pulmonary capillary wedge and pulmonary-artery diastolic pressures compared with left atrial pressure. *ANESTHESIOLOGY* 38:394-397, 1973
3. Malik AB, Kidd BSL: Pulmonary arterial wedge and left atrial pressures and the site of hypoxic pulmonary vasoconstriction. *Respiration* 33:123-132, 1976
4. Roy R, Powers SR, Feustel PJ, et al: Pulmonary wedge catheterization during positive end-expiratory pressure ventilation in the dog. *ANESTHESIOLOGY* 46:385-390, 1977
5. Tooker J, Huseby J, Butler J: The effect of Swan-Ganz catheter height on the wedge pressure—left atrial pressure relationships in edema during positive-pressure ventilation. *Am Rev Resp Dis* 117:721-725, 1978
6. Cassidy SS, Robertson CH Jr, Pierce AK, et al: Cardiovascular effects of positive end-expiratory pressure in dogs. *J Appl Physiol* 44:743-750, 1978
7. Cross CJ, Cain HD, Deaton WJ, et al: Vertical relationships of the pulmonary artery catheter tip and transducer reference point in estimation of the left atrium. *Am Rev Resp Dis* (Part 2) 117:105, 1978
8. Benumof JL, Saidman LJ, Arkin DB, et al: Where pulmonary arterial catheters go: Intrathoracic distribution. *ANESTHESIOLOGY* 46:336-338, 1977
9. Carter BL, Morchhead J, Wolpert SM, et al: Cross-sectional Anatomy Computer Tomography, and Ultrasound Correlation. Section 24. New York, Appleton-Century-Crofts, 1977
10. West JB, Dollery CT, Naimark A: Distribution of blood flow in isolated lung; relation to vascular and alveolar pressures. *J Appl Physiol* 19:713-724, 1964
11. Bannister J, Torrence RW. The effect of the tracheal pressure upon flow:pressure relations in the vascular bed of isolated lungs. *Q J Exp Physio* 45:352-367, 1960
12. Permutt S, Bromberger-Barnea B, Bone HN: Alveolar pressure, pulmonary venous pressure, and the vascular waterfall. *Med Thorac* 19:239-260, 1962

Anesthesiology
51:469-471, 1979

Massive Trophoblastic Embolization and PEEP Therapy

ROBERT NATONSON, M.D.,* BARRY A. SHAPIRO, M.D.,† RONALD A. HARRISON, M.D.,‡
ROBERT C. STANHOPE, M.D.§

Embolization of trophoblastic tissue to lung is a potentially fatal complication of uterine evacuation of a benign hydatidiform mole. It appears that tissue emboli may result in a progressive hypoxemia and cardiopulmonary instability. To our knowledge all pre-

viously reported cases of massive trophoblastic embolization in which ventilatory support has been necessary have been fatal. We present a case in which a patient with this diagnosis was successfully supported with combined ventilatory support and positive end-expiratory pressure (PEEP) therapy.

REPORT OF A CASE

A 19-year-old previously healthy white girl complained of orthopnea, dyspnea on exertion, and a nonproductive cough for six days prior to a scheduled uterine evacuation of a hydatidiform mole. Copious vaginal bleeding necessitated admission to the hospital on an emergency basis, at which time the patient was alert and oriented,

* Respiratory Care Fellow, Department of Anesthesia.

† Associate Professor of Clinical Anesthesia.

‡ Assistant Professor of Clinical Anesthesia.

§ Assistant Professor of Obstetrics and Gynecology.

Received from Northwestern University Medical School, Chicago, Illinois 60611. Accepted for publication April 18, 1979.

Address reprint requests to Dr. Natanson: 613 Illinois Road, Wilmette, Illinois 60091.