

Zero Suppression in Cardiovascular Pressure Monitoring

To the Editor:—The pressures measured by a transducer in the operating room and intensive care areas vary considerably, from low pressures in the venous system, through higher pressures in the pulmonary circulation, to still higher pressures in the systemic arterial system. Most monitors have a low and a high range, one running from 0 to 20 torr for venous pressure measurement and the other 0 to 200 torr for measurement of higher pressures. Unfortunately, a pressure just above 20 torr is too high for the venous scale, while all of the necessary information is crammed into just a small area on the arterial scale. A solution to this problem involves a simple form of zero suppression. When the pressure transducer is calibrated, a predetermined level in the patient is selected as a zero reference point and the monitoring system is calibrated relative to this point. The transducer value is increased a known distance above the original zero reference point until pressures of interest occur on the readout. Thus, a record of the pressure of interest is obtained at the high gain provided by the venous mode. The height of the transducer above the original zero reference

point is measured and added to the pressure on the written record to provide a true value of the pressure being measured. A zero suppression of 20 to 40 torr is conveniently available by this means (fig. 1).

This suggested technique is useful in other situations where pressures somewhat greater than 30 torr need to be monitored with fine resolution. In the operating room and intensive care unit, pressures are often displayed on an oscilloscope, but the size of the trace may be limited by the size of the oscilloscope screen. When fine details of the pressure waveform are of interest, one cannot use a low-sensitivity arterial range. For example, when a patient is being maintained on intra-aortic balloon counterpulsation, it is necessary to determine the temporal location of the dicrotic notch on the arterial trace for optimal synchronization of the pump. This is particularly difficult with a small oscilloscope. Increased sensitivity may be obtained by changing the monitor to the venous mode and then suppressing zero by elevating the transducer until the section of the arterial trace containing the dicrotic notch is displayed in an amplified form. Although absolute pressure can be

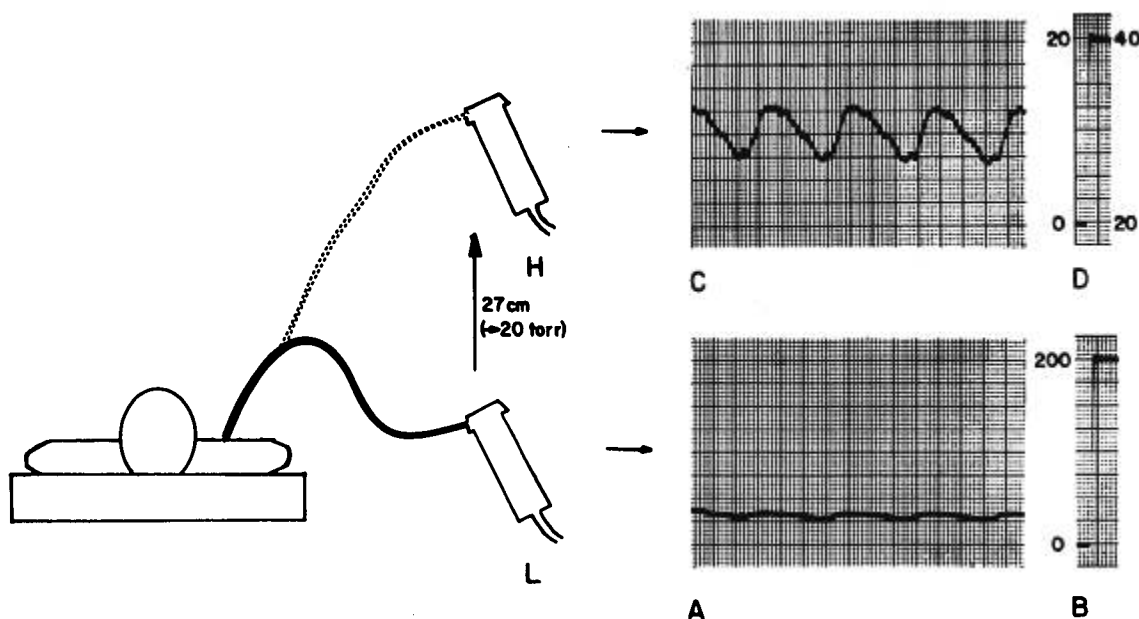


FIG. 1. Zero suppression by transducer elevation. Panel *A* shows a pulmonary arterial pressure recording from a catheter connected to a transducer in the usual location (*L*) and on the arterial pressure range. Panel *B* gives the corresponding calibration. Panel *C* gives the tracing obtained when the monitoring system is switched to the venous range and the transducer is raised 27 cm (the equivalent of 20 torr) to the position *H*. Notice the wealth of detail revealed. Panel *D* gives the corresponding calibration. The record in *D* was obtained while the transducer was still down at position *L*, and the 0–20-torr scale applies to that level. However, when the transducer is elevated 27 cm to *H*, the scale 20–40 torr on the right side of the *D* is immediately applicable.

calculated from the extent of transducer elevation, this is unnecessary, as all that is required is a clear indication of the time of closure of the aortic valve; the absolute pressure at which this occurs is irrelevant to the pump-synchronizing process. Zero suppression by transducer elevation may be utilized in other situations where the time at which an event occurs is of primary interest. For example, in determining systolic time intervals, one might measure the time from the QRS of the electrocardiogram to some pressure signal reflecting opening of the aortic valve. Use of the high-gain venous channel with zero suppression will greatly facilitate visualization of the pressure end point.

It has been found convenient, in situations where absolute pressures as well as small increments of pressure are of interest, to have available a measur-

ing stick calibrated in steps of 10 torr (13.6 cm), so that the transducer can be raised a distance such that the extent of zero suppression is a convenient round number. Similarly, if it is desirable to alternate rapidly between zero suppression and regular recording, one can simply place a second transducer holder at the appropriate distance above zero reference level.

STANLEY LEE SON, M.B., B.CH., F.F.A.R.C.S.
*Assistant Professor of Anaesthesia
Harvard Medical School
Senior Associate in Anesthesia
Peter Bent Brigham Hospital
721 Huntington Avenue
Boston, Massachusetts 02115*

(Accepted for publication July 12, 1979.)

Anesthesiology
51:574, 1979

Anomalous Pulmonary Arterial Catheterization

To the Editor:—I read with interest Dr. Falltrick's report of a pulmonary-artery catheterization through a persistent left superior vena cava.¹ I had recently inserted a pulmonary-artery catheter during resuscitation of a 70-year-old woman who was moribund following a massive mesenteric infarction. The roentgenogram of the chest (fig. 1), taken after insertion, showed a picture similar to the one described by Dr. Falltrick. My patient had previously had roentgenographic examinations of the chest and abdomen, including aortography, in our hospital over the preceding 11 years, but the anomalous left superior vena cava was not noticed prior to this roentgenogram.

M. C. CROCKER, M.B.
*Assistant Professor
Department of Anesthesia
Faculty of Medicine
The University of Manitoba
St. Boniface General Hospital
409 Tache Avenue
Winnipeg, Manitoba R2H 2A6, Canada*

REFERENCE

1. Falltrick RT: Pulmonary arterial catheterization through a persistent left superior vena cava. *ANESTHESIOLOGY* 50:155-156, 1979

(Accepted for publication July 12, 1979.)



FIG. 1. Roentgenogram of the chest, showing the pulmonary-artery catheter passing through the anomalous left superior vena cava.