

## Unilateral Analgesia Following Epidural and Subarachnoid Block

PETER M. BOZEMAN, M.D.,\* AND PHOOL CHANDRA, M.D.†

A case report of unexpected hemianalgesia following epidural and subarachnoid block is presented, with a possible explanation.

## REPORT OF A CASE

Anesthesia for cesarean section was requested for a 27-year-old woman, gravida 1, para 0, at 36 weeks gestation. Review of systems and prenatal and past medical history were unremarkable. The patient denied previous regional anesthesia.

Vital signs revealed supine blood pressure 120/80 torr and pulse rate 100 beats/min. The rest of the physical examination and laboratory studies disclosed no abnormalities. A single-dose epidural technique was planned.

The patient was placed in the left lateral position and a 17-gauge Tuohy epidural needle placed in the epidural space at the L2-3 level on the first attempt. A total of 19 ml 0.75 per cent bupivacaine was injected. After a 20-min wait, sensory level to pin prick was

found to extend from the L2 to T8 dermatomes, but only on the right side. There was no change in the anesthetic pattern following an additional 20 min. The patient expressed a desire to be awake during the procedure and, therefore, a subarachnoid block was used.

Two unsuccessful attempts were made with the patient in the left lateral position. The patient was then moved to the sitting position. A successful lumbar puncture was achieved at the L3-4 interspace, with free flow of cerebrospinal fluid in all four quadrants of needle position. Tetracaine, 1 ml, 1 per cent, with 1:200,000 epinephrine, was used. When the patient was sitting, it could be seen that she had a lumbar scoliosis that had not been evident when she was in the lateral position. The scoliosis may have contributed to the difficulty of the block. The sensory level now extended over the entire lower extremity up to the T6 level, but, surprisingly, only on the right side. The patient could not tolerate surgical stimulation left of the midline, and local lidocaine infiltration was necessary. The skin incision to the right of the midline was well tolerated and no local anesthetic was needed in this area.

\* Instructor in Anesthesiology.

† Assistant Professor in Anesthesiology.

Received from the Department of Anesthesiology, University of Michigan Medical School, Ann Arbor, Michigan 48109. Accepted for publication October 19, 1979.

Address reprint requests to Dr. Chandra.

## DISCUSSION

In this patient, epidural and subarachnoid block resulted in unilateral analgesia. Four causes have been described for unilateral epidural analgesia. 1) When

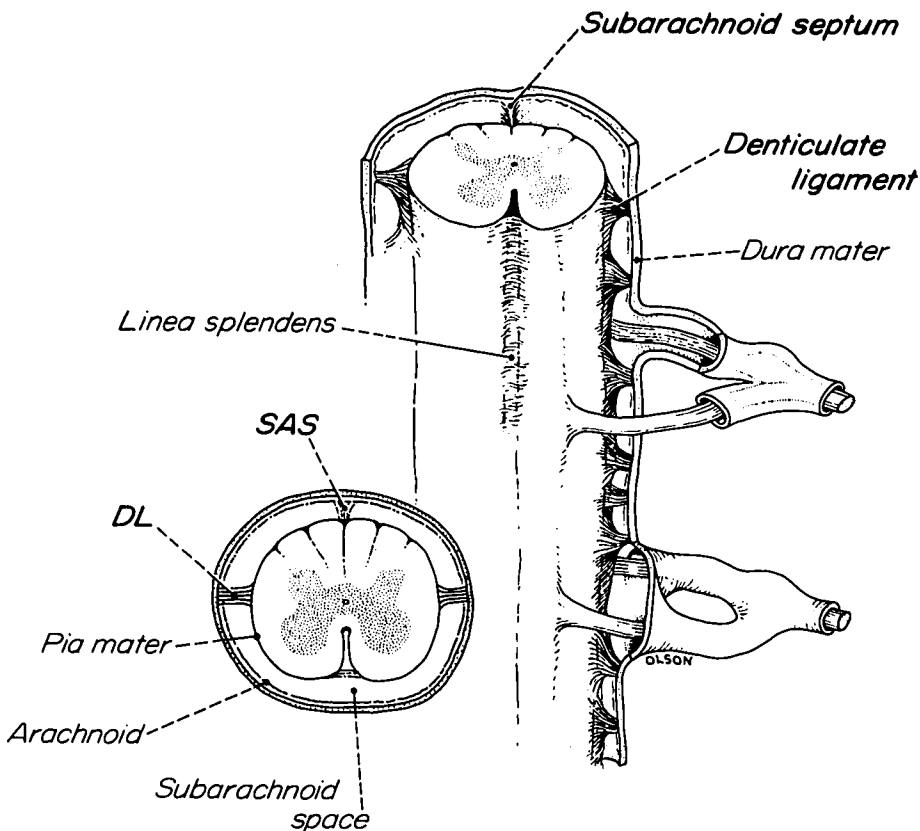


FIG. 1. Two views of spinal cord, showing ligamentous projections extending from pia mater to dura mater. (See text.)

the patient is lying on his or her side, and small volumes of local anesthetic solution are slowly injected, gravity causes the solution to be deposited along the lowermost part of the epidural space and also favors escape of the solution toward the dependent paravertebral area.<sup>1</sup> 2) Acquired<sup>2</sup> or congenital<sup>3</sup> midline adhesions between the dura mater and the lamina may act as diffusion barriers, regardless of the patient's position. 3) If an excessive length of catheter is introduced epidurally,<sup>4</sup> the catheter tip may pass into the paravertebral area and subsequent unilateral anesthesia may occur. 4) The catheter tip may be placed in the anterior epidural area, thereby favoring longitudinal and ipsilateral transverse spread of anesthetic rather than circumferential spread around the dura.<sup>5</sup>

In this patient, an epidural catheter was not used and the unblocked side was the dependent side, thus eliminating causes 1, 3, and 4. This leaves a strong possibility of either an acquired or congenital abnormality as the probable cause of unilateral analgesia. However, in this patient, *both* epidural and subarachnoid blocks produced unilateral analgesia. There has been no case report of unintentional unilateral spinal blocks, even though patchy or inadequate blocks have been caused by low drug dosage, time-expired drugs, improper positioning, and failure to deposit a part of the anesthetic intrathecally.

The following is offered as a possible explanation for the unilateral analgesia in this patient. The pia mater is a thin vascular membrane that closely invests the spinal cord and extends four ligamentous projections to the dura (fig. 1). It is conceivable that if these ligaments were overdeveloped and unbroken, they could interfere with the subarachnoid spread of local anesthetic agents and result in unilateral subarachnoid block.<sup>6</sup>

As mentioned, this patient had scoliosis of the lumbar spine. Valentino<sup>7</sup> has demonstrated with myelography a unilateral distribution of contrast medium in some patients with severe scoliosis. He hypothesized that the dura on the convex aspect of the spine is tensed like the chord of an arc, causing the spinal cord to be pressed against the opposite surface of the spinal canal and the subarachnoid space to be squeezed between the spinal canal wall and the cord. This condition could also hinder the movement of cerebrospinal fluid and local anesthetics placed in the subarachnoid space.

#### SUMMARY

A case of unintentional unilateral analgesia following both epidural and subarachnoid block is presented. It is suggested that the presence of an anomalous congenital midline diffusion barrier in both the epidural and subarachnoid spaces could explain this phenomenon.

#### REFERENCES

1. Gutierrez A: Anestesia metamérica peridural. *Rev Cir Buenos Aires* 12:665, 1932
2. Singh A: Unilateral epidural analgesia. *ANAESTHESIA* 22: 147-149, 1967
3. Vandam LD: Quoted by Singh A<sup>2</sup>
4. Sanchez A, Acuna L, Rochs F: An analysis of the radiological visualization of the catheters placed in the epidural space. *Br J Anaesth* 39:485, 1967
5. Usubiaga JE, Dos Reis A, Usubiaga LE: Epidural misplacement of catheters and mechanisms of unilateral block. *ANESTHESIOLOGY* 32:158-161, 1970
6. Lund PC: *Principles and Practice of Spinal Anesthesia*. Springfield, Ill., Charles C Thomas, 1971, pp 51-52
7. Valentino V: *Myelography*. Springfield, Ill. Charles C Thomas, 1965, pp 238-239

## Experiences with a New Endotracheal Tube for Microlaryngeal Surgery

LUIS E. TORRES G., M.D.,\* AND ROBERT C. REYNOLDS, M.D., PH.D.†

The introduction of the operating microscope<sup>1-3</sup> made earlier<sup>4</sup> anesthetic techniques inadequate for microlaryngeal surgery.

\* Resident in Anesthesia.

† Associate Professor of Anesthesia.

Received from the Department of Anesthesiology, University of California at Los Angeles. Accepted for publication October 26, 1979. This work was done at the Center for the Health Sciences at the University of California at Los Angeles. Supported by grants from UCLA Department of Anesthesiology, Medrec Inc., and

In developing new methods, Urban<sup>5</sup> and Oulton<sup>6</sup> turned to the venturi principle for their techniques of nonintubated ventilation. Carden<sup>7</sup> and Spoerel<sup>8</sup>

Sandoz Pharmaceutical, and contributions from National Catheter Company, Argyle, New York. Presented at the Seventeenth Annual Western Anesthesia Residents' Research Conference held at Dillon, Colorado, March 30-April 1, 1979.

Address reprint requests to Dr. Torres: Department of Anesthesiology, UCLA School of Medicine, The Center for the Health Sciences, Los Angeles, California 90029.