

Anesthesiology
53:69-71, 1980

Disturbance of Consciousness and Hypocalcemia after Neomycin Irrigation, and Reversal by Calcium and Physostigmine

FUN-SUN YAO, M.D.,* STEVEN F. SEIDMAN, M.D.,† JOSEPH F. ARTUSIO, JR., M.D.‡

Soon after the initial discovery of neomycin sulfate by Waksman and Lechevalier, in 1949, enthusiasm for the parenteral use of this broad-spectrum antibiotic was dampened by reports of serious nephrotoxicity and ototoxicity. In 1956, a third striking toxicity of neomycin therapy was emphasized by Pridgen,¹ who reported four cases of respiratory arrest which he attributed to the use of intraperitoneal neomycin. By 1970, Pittinger² was able to review 111 cases of respiratory arrest following antibiotic administration. The following is a report of an unusual complication: hypocalcemia and prolonged consciousness disturbance without respiratory arrest following irrigation of the bladder with neomycin sulfate.

REPORT OF A CASE

A 30-month-old white boy weighing 19 kg was admitted March 18, 1979, for cystoscopy and removal of the cystostomy tube. He had undergone first- and second-stage repair of hypospadias. The patient had received general anesthesia with halothane-nitrous oxide-oxygen for the procedures and had recovered from anesthesia uneventfully.

On March 19, no premedication was given. General anesthesia was started at 9:45 A.M. and maintained with 1 per cent halothane, nitrous oxide, 3 l/min, and oxygen, 2 l/min, using a mask technique. At 10:00 A.M. a 175-ml volume of 0.5 per cent diluted neomycin sulfate solution with contrast medium was instilled through the suprapubic cystostomy tube in an attempt to demonstrate a good voiding stream. The child did not void. The cystostomy tube was allowed to drain, and only 75 ml neomycin solution were recovered. A radiogram of the abdomen demonstrated an intraperitoneal accumulation of contrast medium. Anesthesia lasted 35 min and was uneventful.

On arrival in the recovery room (10:20 A.M.), the child was crying and awakening. Blood pressure was 110/50 torr, pulse rate 110/min, and respiratory rate 30/min, without impairment. Rectal temperature was 34.3 C. By 11:00 A.M. the patient was fully awake, but his temperature was only 35.9 C. He was kept in the recovery room for observation. By 12:00 noon, his temperature returned to normal, and vital signs were stable, but he became lethargic and arousability progressively decreased.

By 1:00 P.M. the child was totally unresponsive to verbal and

pain stimulation. Extremities were flaccid, and intercostal movement had decreased. Pupils were almost fully dilated and reacted only slightly to light. Vital signs remained stable. Respiratory movement was smooth and mainly diaphragmatic at a rate of 25/min. Tidal volume was 110-140 ml. Clinically, respiration was adequate and the patient's color was normal. Arterial blood-gas values were not determined. Oxygen, 30 per cent, was administered by mask, but artificial respiration was not attempted.

The tentative diagnosis was neomycin-induced neuromuscular block and central nervous system depression. At 1:30 P.M. calcium gluconate, 200 mg, was given iv to reverse the neuromuscular depression. Dramatically, the child opened his eyes and responded to his name approximately 2 min following the injection. Intercostal movement improved, but the pupils remained dilated. Ten minutes later the child became unresponsive again. An additional 100 mg calcium gluconate was given at 2:00 P.M., with only a transient response. Because of prominent central nervous system depression in spite of adequate spontaneous respiration, physostigmine, 0.2 mg, was given iv at 2:30 P.M. The child woke up almost immediately and called for his mother. Another 0.2 mg physostigmine was given iv 10 min later to prolong the effect on the central nervous system. The child again became unconscious at 3:00 P.M. At 5:30 P.M., seven and a half hours after neomycin irrigation, 0.4 mg physostigmine failed to reverse the disturbance of consciousness.

The neuromuscular block was monitored with a peripheral nerve stimulator. Before the initial administration of calcium and physostigmine, single-twitch and 50-Hz tetanus stimulation using a maximal output of 30 mA showed decreased twitch height compared with subsequent stimulation after calcium and physostigmine therapy. Tetanic fade or posttetanic facilitation was not observed. By 3:30 P.M. the patient was withdrawing his arm while the tetanic stimulation was applied, but he remained unconscious.

Because of definite hypocalcemia (serum calcium 7.7 mg/dl) and the good initial response to calcium gluconate, we decided to continue calcium therapy. Three doses of calcium gluconate, 100 mg, were given iv at 20-min intervals starting at 6:30 P.M. The child responded transiently after each injection, but sinus bradycardia was also noticed. The heart rate decreased from 120/min to 80/min. Calcium gluconate was then given by continuous intravenous infusion of 100 mg per hour from 8:00 P.M. until 6:00 A.M. the next morning, when serum calcium was 8.6 mg/dl, and then 50 mg per hour until 12:00 noon, when serum calcium was 8.9 mg/dl. A total of 1,900 mg of calcium gluconate had been given.

The child had become arousable but drowsy about 15 min following the start of the continuous intravenous infusion of calcium. Four hours later (12:00 midnight) he was fully oriented and talking clearly to his mother.

Pupillary dilation did not respond to calcium or physostigmine as did consciousness. Pupils gradually returned to normal size and reacted normally to light in 20 hours. Vital signs remained stable during the course of treatment. Negative fluid balance was noticed, and the child was given 1,200 ml 5 per cent dextrose in 0.225 per cent saline solution and 1,000 ml 5 per cent dextrose in

* Assistant Professor of Anesthesiology.

† Resident in Anesthesiology.

‡ Professor and Chairman of Anesthesiology.

Received from the Department of Anesthesiology, Cornell University Medical College—The New York Hospital, New York, New York 10021. Accepted for publication January 13, 1980.

Address reprint requests to Dr. Yao.

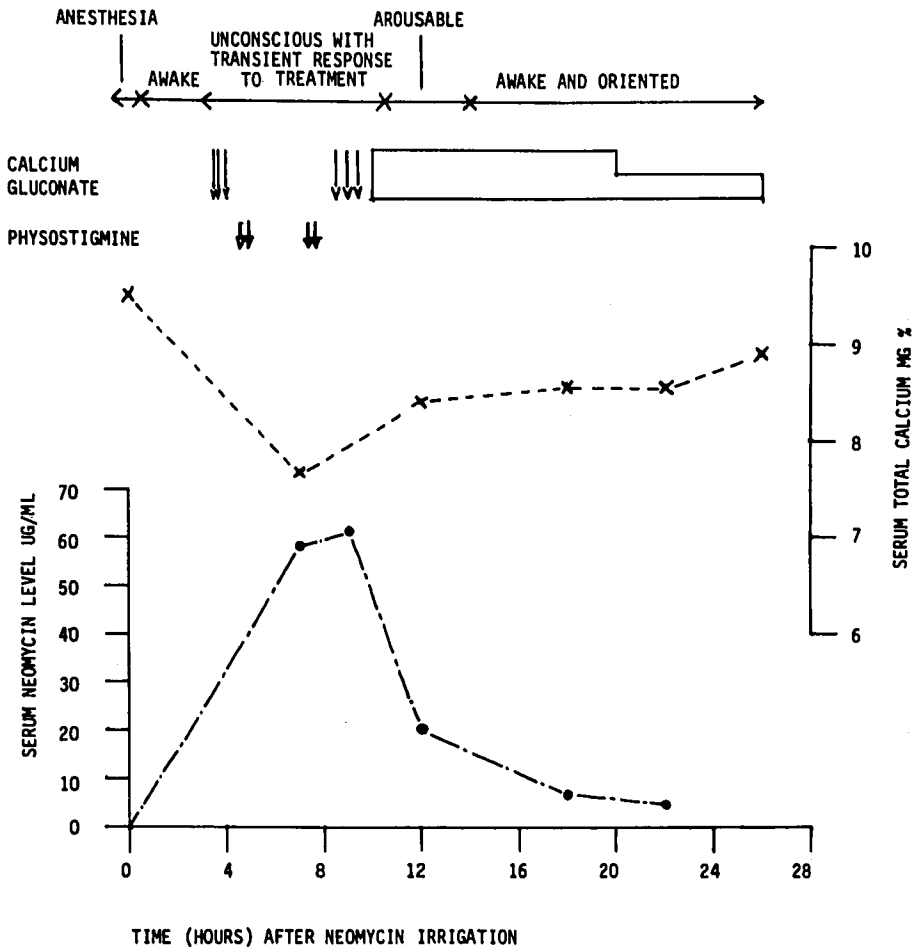


FIG. 1. Level of serum neomycin, its effects on consciousness and serum total calcium, and its treatment with bolus injections of calcium gluconate (\downarrow), physostigmine (∇), and continuous calcium gluconate drip (\square).

0.45 per cent saline solution in 24 hours. He urinated 2,450 ml of urine with specific gravities ranging from 1.006 to 1.014.

Blood electrolytes, serum calcium, urea nitrogen, glucose, and creatinine were followed carefully. They were unremarkable except for hypocalcemia. The serum neomycin level and its relationship to the serum calcium level and to consciousness are shown in figure 1. The highest serum neomycin level was 61.4 $\mu\text{g/ml}$. (Therapeutic level is 5–10 $\mu\text{g/ml}$.)

DISCUSSION

Many studies have shown that the neuromuscular block produced by neomycin is similar to the effect of excess magnesium ions.³ Magnesium is known to block neuromuscular transmission mainly by preventing acetylcholine release from the nerve terminal. It also has been demonstrated that both magnesium ions and neomycin desensitize the postsynaptic membrane to acetylcholine.⁴ The predominant presynaptic blocking effect of neomycin was confirmed in 1977 by Wright and Collier.⁵ They concluded that neomycin blocks acetylcholine release by blocking the influx of calcium ions necessary for transmitter release.

The partial neuromuscular blocking effect in this patient was demonstrated by peripheral nerve blockade monitor. The initial flaccidity of the extremities

without diaphragmatic paralysis could be explained by the low serum level of neomycin. The neomycin dose of 500 mg was equivalent to 26.3 mg/kg, and the highest serum level of neomycin in this patient was 61.4 $\mu\text{g/ml}$. Short *et al.*⁶ found in dogs that the average blood level at the onset of apnea was 200 $\mu\text{g/ml}$ and that the minimum intravenous dose of neomycin required to produce apnea was 50 mg/kg.

Disturbance of consciousness after neomycin administration is not well documented in the literature. Pittinger² reviewed 111 cases of antibiotic-induced apnea in 1970. Ten patients died despite artificial ventilation. They were very young or very old. Apnea was usually accompanied by unconsciousness, but artificial ventilation did not reverse the disturbance of consciousness. In the patients who recovered, consciousness usually returned shortly after the recovery of adequate respiration. This suggests that unconsciousness may be due to central effect of neomycin.

Our patient, although he had adequate spontaneous respiration, remained unconscious for seven hours after complete recovery from anesthesia. While unconscious he had no hypoxia or hypoglycemia, and no electrolyte imbalance except hypocalcemia. The

disturbance of consciousness corresponded well with an increased serum neomycin level. The response to calcium gluconate and physostigmine injection also suggested a central nervous system effect of neomycin.

Kanamycin⁷ is a similar aminoglycoside antibiotic. In the adult, very little kanamycin is detected in the cerebrospinal fluid. But intramuscular injection of kanamycin in normal children produces spinal fluid concentrations that average a fifth to a tenth of those present in the plasma. Neomycin, having the same aminoglycoside base, may be able to pass the blood-brain barrier of pediatric patients and inhibit central neurotransmitter release, resulting in disturbance of consciousness.

The treatment of antibiotic-induced neuromuscular blockade is well documented in clinical cases and in animal experiments.^{2,8,9} Neostigmine given alone is effective only when the block is incomplete, while calcium is usually effective with any degree of blockade.⁹ Hava¹⁰ found that the acute toxicity and chronic damage of the kidney and organ of Corti depended on the ionized calcium level, and that higher calcium levels abolished nephrotoxicity and ototoxicity.

We propose that in our patient the disturbance of consciousness after neomycin administration was probably due to decreased release of central nervous system neurotransmitter, and that neomycin directly competes with calcium ions necessary for transmitter release. Because of the obvious hypocalcemia and potential ototoxic and nephrotoxic effects of neomycin, calcium therapy was our first choice to reverse the unconsciousness, and we recommend that calcium therapy be continued until the serum calcium level reaches the normal range.

Physostigmine had been used to reverse the adverse central nervous system effects of neuroleptics, belladonna alkaloids, antiparkinsonism drugs, antihistamines, and tricyclic antidepressants. Being a tertiary amine, physostigmine is able to cross the blood-brain barrier, and acts as an antidote through activation of central cholinergic pathways. But physostigmine has muscarinic side effects, and experience with it in pediatric patients has been limited. We used it only to demonstrate a central nervous system effect. The ineffectiveness of the third dose of physostigmine could be explained by the higher serum neomycin level, 58.7 $\mu\text{g}/\text{ml}$ at that time.

The pupillary dilation seen with apnea has been reported by Ferrara and Stedishi.² It is due to the ciliary ganglionic blocking effect of neomycin.⁵ We do not know why the pupillary dilation did not respond to calcium or physostigmine therapy. Possibly the ciliary ganglion is very sensitive to neomycin.

The hypocalcemia (serum calcium 7.7 mg/dl) observed in this case corresponded with a high serum

neomycin level (fig. 1). Neomycin has been shown to bind calcium in a manner similar to that of ethylenediaminetetraacetic acid (EDTA). Several studies have shown that neomycin does not significantly affect ionized calcium.⁵ In 1977 Crawford *et al.*¹¹ demonstrated that neomycin decreases total calcium content at the expense of the bound calcium fraction rather than the unbound fraction. Crawford,¹² in 1978, further discovered that urinary calcium excretion and volume were increased in neomycin-treated dogs. Since ionized calcium is not affected, we do not consider that hypocalcemia is the primary cause of neuromuscular block and the disturbance of consciousness.

In summary, in addition to neuromuscular blockade, disturbance of consciousness and hypocalcemia may occur when neomycin solution is administered, especially to pediatric patients. Careful monitoring and maintenance of vital signs, especially respiration, must be emphasized. Artificial ventilation should be used at the first indication of respiratory insufficiency. Calcium is the drug of choice in the treatment of complications induced by neomycin administration.

The authors are grateful to Dr. John Romankiewicz and the Upjohn Company for their assistance in analyzing serum neomycin levels.

REFERENCES

1. Pridgen JE: Respiratory arrest thought to be due to intraperitoneal neomycin. *Surgery* 40:571-574, 1956
2. Pittinger CB, Eryasa Y, Adamson R: Antibiotic-induced paralysis. *Anesth Analg (Cleve)* 49:487-501, 1970
3. Corrado AP, Nicolette RL: Mechanism of neuromuscular block produced by streptomycin, dihydrostreptomycin, neomycin and kanamycin. *Acta Physiol Lat Am* 12:212, 1961
4. Elmquist D, Jeselsson JO: The nature of neuromuscular block produced by neomycin. *Acta Physiol Scand* 54:105-110, 1962
5. Wright JM, Collier B: The effects of neomycin upon transmitter release and action. *J Pharmacol Exp Ther* 200:576-587, 1977
6. Short WB, Hartley JL, Martin JD Jr: A study of respiratory arrest following the administration of neomycin. *Surg Forum* 9:402-404, 1958
7. Goodman LS, Gilman A: *The Pharmacological Basis of Therapeutics*. New York, Macmillan, 1975, p 1177
8. Lee C, Chen D, Barnes A, et al: Neuromuscular block by neomycin in the cat. *Can Anaesth Soc J* 23:527-533, 1976
9. Stanley VF, Giesecke AHJ, Jenkins MT: Neomycin-curare neuromuscular block and reversal in cats. *ANESTHESIOLOGY* 31:228-232, 1969
10. Hava M, Sobek V, Mikulaskova J: On the role of calcium ions in the toxic neomycin action. *Biochem Pharmacol* 8:76, 1961
11. Crawford LM, Campell DL, Harvey T: Hypocalcemic effect of aminoglycoside antibiotics in the dairy cow. *Can J Comp Med* 41:251-256, 1977
12. Crawford LM, Teske RH: Urinary calcium excretion by neomycin-treated dogs. *Toxicol Appl Pharmacol* 4:567-570, 1978