

Clinical Reports

RONALD D. MILLER, M.D., *Editor*

Anesthesiology
53:242-244, 1980

Management of Tracheal Atresia with Tracheoesophageal Fistula

DAVID D. ALFERY, M.D.,* C. F. WARD, M.D.,† MICHAEL H. PLUMER, M.D.,‡ FRANK LYNCH, M.D.§

Tracheal atresia is compatible with life when associated with a tracheoesophageal or bronchoesophageal fistula. Survival at birth depends on prompt diagnosis and proper airway management. The possibility of surgical correction or palliation rests on the extent of atresia present. We present a case of tracheal atresia for which a palliative operation was performed. The important features of the diagnosis and airway control of this condition are discussed.

REPORT OF A CASE

A 31-year-old woman, gravida 2, para 1, was admitted to University Hospital in premature labor with a pregnancy at 30 weeks' gestation, complicated earlier by first-trimester bleeding. Labor progressed rapidly, and a 1,250-g male infant was delivered vaginally with the aid of a pudendal block and 50 per cent nitrous oxide analgesia. Polyhydramnios was noticed at the time of delivery.

The infant was initially cyanotic, with fair tone and reflex responsiveness, a heart rate of 100 beats/min, but little evidence of air movement despite apparently strong ventilatory efforts. The 1-minute Apgar score was 5. As the pulse rate declined to 60 beats/min, endotracheal intubation with a 3.0-mm endotracheal tube was attempted. The vocal cords were easily visualized and moved as if the infant were crying, though no sound was audible. Endotracheal intubation proved impossible, as the tube could not be passed more than a few millimeters beyond the vocal cords. Although mouth-to-tube ventilation through the partially inserted tube was attempted, the tube seemed to be completely obstructed.

* Fellow in Anesthesia.

† Assistant Professor of Anesthesiology.

‡ Associate Clinical Professor of Anesthesiology and Reproductive Medicine.

§ Assistant Clinical Professor of Surgery.

Received from the Departments of Anesthesiology and Surgery, University of California Medical Center, San Diego, 225 Dickinson Street, San Diego, California 92103.

Address reprint requests to Dr. Alfery.

Key words: Anesthesia; pediatric. Lung: aspiration. Airway: tracheal atresia; tracheoesophageal fistula.

The tube was removed, and ventilation via a bag and mask was begun. The heart rate increased to 120 beats/min, color improved, and ventilation was audible bilaterally on auscultation of the chest. The 5-minute Apgar score was 7.

Since ventilation via bag and mask was possible despite demonstrated subglottic obstruction, the diagnosis of tracheal web or atresia with tracheoesophageal fistula seemed likely. Also, because air was not present in the stomach despite the high airway pressures necessary for ventilation, we considered the diagnosis of esophageal atresia. Two attempts to pass an endotracheal tube blindly into the trachea via the esophagus were unsuccessful, and leaving the tube in the upper esophagus seemed only to make ventilation more difficult. Consequently, ventilation via bag and mask was continued until 30 min after birth, when an otolaryngologist confirmed the presence of a tracheoesophageal fistula by placing a 3.0-mm endotracheal tube into the trachea via the esophagus under direct vision. The fistula appeared to be located approximately midway between the larynx and the carina.

The patient was admitted to the newborn intensive care unit, where continuous mechanical ventilation with PEEP of 2 cm H₂O and 40 per cent oxygen was initiated. The risk of aspiration was minimized by the presence of the endotracheal tube filling the proximal esophageal segment and by frequent suctioning of the mouth and pharynx. Good respiratory status was maintained until the fourth hospital day, when oxygenation deteriorated and the murmur of a patent ductus arteriosus was heard. Congestive heart failure rapidly developed and was controlled with digitalis and furosemide. Maintenance of an adequate airway was increasingly difficult due to the instability of the endotracheal tube and the ease and frequency with which intubation of the right mainstem bronchus occurred. Therefore, the infant underwent an operation on the ninth day of life to ligate the patent ductus arteriosus and attempt definitive correction of the airway anomaly.

Anesthesia was provided with humidified nitrous oxide (2 l/min) and oxygen (1 l/min) and supplemented with *d*-tubocurarine. With the airway maintained by the endotracheal tube previously inserted through the tracheoesophageal fistula, the patent ductus arteriosus was ligated through a left thoracotomy. The infant's condition improved, and laryngoscopy next showed a blind tracheal pouch a few millimeters below the normal-appearing vocal cords. Esophagoscopy revealed the esophagus to end in the upper mediastinum, with a 3-mm opening anteriorly into the trachea (fig. 1). Maintenance of the airway during endoscopy was difficult, with endobronchial intubation occurring easily whenever the child was moved. At one point it was necessary to reinsert the endotracheal

tube by passing a Miller #0 laryngoscope blade down the esophagus and replacing the endotracheal tube through the fistula.

Because positive-pressure ventilatory assistance would be necessary postoperatively, an attempt to provide a more secure airway was undertaken. During cervical exploration, we found that the blind tracheal pouch had no connection to the distal portion of the trachea into which the tracheoesophageal fistula opened. Tracheal reconstruction was deemed impossible due to the relatively long absent portion. Therefore, a permanent tracheal stoma was constructed by dividing the fistula and then securing the small segment of distal trachea to the skin in the sternal notch. During creation of the stoma, the airway was maintained by having a surgeon hold an endotracheal tube into place in the tracheal stump. When the stoma was complete, a shortened Shiley® #0 tracheostomy tube was inserted and sutured in place.

This new airway proved satisfactory for continued mechanical ventilation and for subsequent general anesthesia provided for gastrostomy and correction of malrotation of the gut on the fifteenth day of life. Following this procedure, however, the infant's general condition deteriorated, with the onset of seizure activity, clotting abnormalities, and progressive congestive heart failure. The infant died on the eighteenth day of life. Postmortem examination revealed massive central nervous system hemorrhage as the cause of death.

DISCUSSION

Atresia of the trachea, with or without associated esophageal defects, is an extremely rare anomaly. In a review of the literature in 1972, Hopkinson added four cases of congenital absence of the trachea to the 20 that had been recorded since 1900.¹ Of the 24 cases he discussed, the trachea was totally absent in 19. The joined mainstem bronchi usually communicated with the esophagus, either at the level of the normal bifurcation or at a lower level (bronchoesophageal fistula); four cases with total absence of the trachea showed no communication between the respiratory tract and esophagus, a condition incompatible with life. The five cases of partial atresia all showed communication between the apex of a short length of distal trachea with the esophagus (tracheoesophageal fistula). In addition, many of these patients had other malformations of development, particularly cardiac and genitourinary.² In the majority of cases the larynx was described as normal.

Although most patients with tracheal atresia have died at birth, the condition is not necessarily incompatible with life. Lyons and Bruce described an infant with an absent trachea in which ventilation was possible by bag and mask because of a communication between the esophagus and the joined mainstem bronchi.³ Similarly, McNie and Pryse-Davies described an infant with tracheal agenesis who survived for several hours after birth.⁴ This infant had a communication from the larynx to the esophagus and then to the mainstem bronchi.

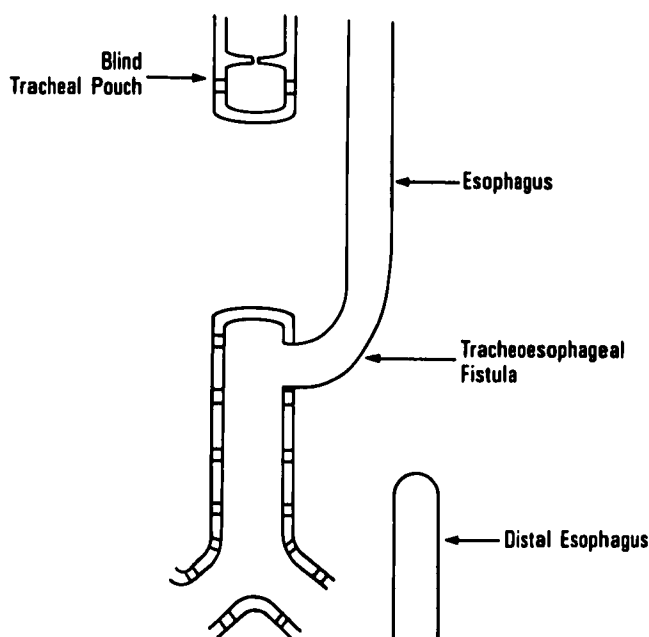


FIG. 1. Schematic representation of the anomaly, showing blind tracheal pouch and connection between esophagus and distal trachea.

The diagnosis of tracheal obstruction (although not necessarily complete) is established when the endotracheal tube has been passed through the glottis and there is an inability to advance the tube further or ventilate the patient.⁵ When ventilation can be accomplished with relatively high inflation pressures by bag and mask without producing gastric distention, severe tracheal obstruction accompanied by a tracheoesophageal fistula or bronchoesophageal fistula is the likely diagnosis. In this situation efforts to intubate the trachea should be abandoned and oxygenation maintained by assisted bag-and-mask ventilation. Lyons and Bruce³ suggest "support (of) the esophagus with an endotracheal tube to provide an air passage," and this is essentially what was accomplished in our case. Exposure for passage of the tube can be provided with a Miller #0 laryngoscope blade in the esophagus. When the endotracheal tube is passed into the esophagus in an attempt to provide a means for ventilation, the possible presence of a bronchoesophageal fistula must be considered and the tube advanced only as far as necessary to establish a functioning airway; accidental endobronchial intubation can easily occur in this setting.

When the airway is secure, further management will depend upon the exact nature of the defect. Immediate exploration is indicated if the stability of the endotracheal tube necessitates continuous personal attention from the endoscopist. Operation was

† Shiley, Inc., Irvine, California.

delayed several days for the patient presented herein, yet even with a short segment of the trachea present, considerable instability of the airway was encountered.

In selected cases of tracheal atresia surgical palliation is possible. The first surgical correction of this condition with survival beyond the immediate post-operative period was reported in 1963.⁶ This infant's trachea ended just inferior to the vocal cords; ventilation was possible because of an associated bronchoesophageal fistula. At 36 hours of life the patient underwent a cervical esophagostomy and feeding gastrostomy. The distal esophagus was divided and a respiratory passage composed of esophagus leading to the bronchi was brought out to the skin; thus, an "esophageal tracheostomy" was constructed. Other children with congenital tracheal malformations have been operated upon successfully,^{7,8} and a recent report details the resection of a 17-mm hypoplastic segment of trachea in a 4-month-old infant.⁹ Our patient was potentially salvageable because of the presence of distal trachea.

In summary, we wish to emphasize the following points: 1) The diagnosis of tracheal atresia with tracheoesophageal fistula or bronchoesophageal fistula should be considered when one can neither advance nor ventilate through an endotracheal tube, especially when ventilation via bag and mask proves successful; 2) initial treatment consists of assisted

ventilation by bag and mask. Although attempts at endotracheal intubation should cease, a tube in the esophagus may improve ventilation; 3) an early attempt at surgical palliation (or correction) should be undertaken when the airway is inadequate or unstable. If exploration reveals the presence of a bronchoesophageal fistula, the desirability of further therapy is debatable.³

REFERENCES

1. Hopkinson JM: Congenital absence of the trachea. *J Pathol* 107:63-67, 1972
2. Ashley DJB: A case of congenital tracheal obstruction with esophageal atresia. *J Pathol* 108:261-263, 1972
3. Lyons SM, Bruce AEG: Tracheal agenesis: A report of two cases. *Anesthesia* 23:98-102, 1968
4. McNie DJM, Pryse-Davies J: Tracheal agenesis. *Arch Dis Child* 45:143-144, 1970
5. Hammallah R, Rosales JK: Laryngeal web in an infant with tracheoesophageal fistula. *ANESTHESIOLOGY* 42:95-97, 1975
6. Fonkalsrud EW, Martelle RR, Maloney JV: Surgical treatment of tracheal agenesis. *J Thorac Cardiovasc Surg* 45:520-525, 1963
7. Cantrell JR, Guild HG: Congenital stenosis of the trachea. *Am J Surg* 108:297-305, 1964
8. Fearon B, Ellis D: The management of long term airway problems in infants and children. *Ann Otol Rhinol Laryngol* 80:669-677, 1971
9. Debrand M, Tseuda K, Browning SK, et al: Anesthesia for extensive resection of congenital tracheal stenosis in an infant. *Anesth Analg (Cleve)* 58:431-433, 1979

Anesthesiology
53:244-246, 1980

Unilateral Pneumothorax Following Jet Ventilation during General Anesthesia

JUEI-LING CHANG, M.D.,* ACHIEL BLEYAERT, M.D.,† RICHARD BEDGER, D.M.D.‡

Jet ventilation has become an accepted and practical technique during anesthesia for laryngoscopy, fiberoptic bronchoscopy and certain head and neck surgical procedures involving invasion of the airway. However, complications such as pneumothorax¹ and abdominal² distention have been reported. This is the

case report of unilateral pneumothorax secondary to endobronchial intubation with the jet catheter.

REPORT OF A CASE

A 73-year-old woman weighing 47 kg was admitted with a diagnosis of recurrent squamous cell carcinoma and scheduled for direct laryngoscopy and biopsy. She had no history of cardiopulmonary problems; preoperative roentgenogram of the chest was normal, and electrocardiogram was within normal limits. All laboratory values were within normal limits with except serum potassium, which showed slight hypokalemia (serum K⁺ = 3.3 mEq/l).

Hydroxyzine, 50 mg, im, and atropine, 0.4 mg, im were given 60 min before operation. Arterial blood pressure was 100/70 torr. Thiomytal, 160 mg, iv, was given, followed by inhalation of halothane, nitrous oxide and oxygen. The patient was then positioned with a roll under the shoulders and a Jackson laryngoscope

* Assistant Professor.

† Associate Professor.

‡ Fellow.

Received from the Department of Anesthesiology, Eye and Ear Hospital of Pittsburgh, University of Pittsburgh, 230 Lothrop Street, Pittsburgh, Pennsylvania 15213. Accepted for publication March 10, 1980.

Address reprint requests to Dr. Chang.

Key words: Equipment: jet catheter. Anesthetic techniques: laryngoscopy; bronchoscopy. Complication, pneumothorax.