

Date: April 30, 1980

Title: ELECTRICAL AND PATHOLOGICAL CORRELATES OF BRAIN HYPOXIA DURING HYPOTENSION

Authors: D.Y. Eng, M.D., W.K. Dong, Ph.D., S.W. Bledsoe, Ph.D., J.E. Heavner, D.V.M., Ph.D.,
C.M. Shaw, M.D. and T.F. Hornbein, M.D.

Affiliation: Department of Anesthesiology, University of Washington, Seattle, Washington

INTRODUCTION:

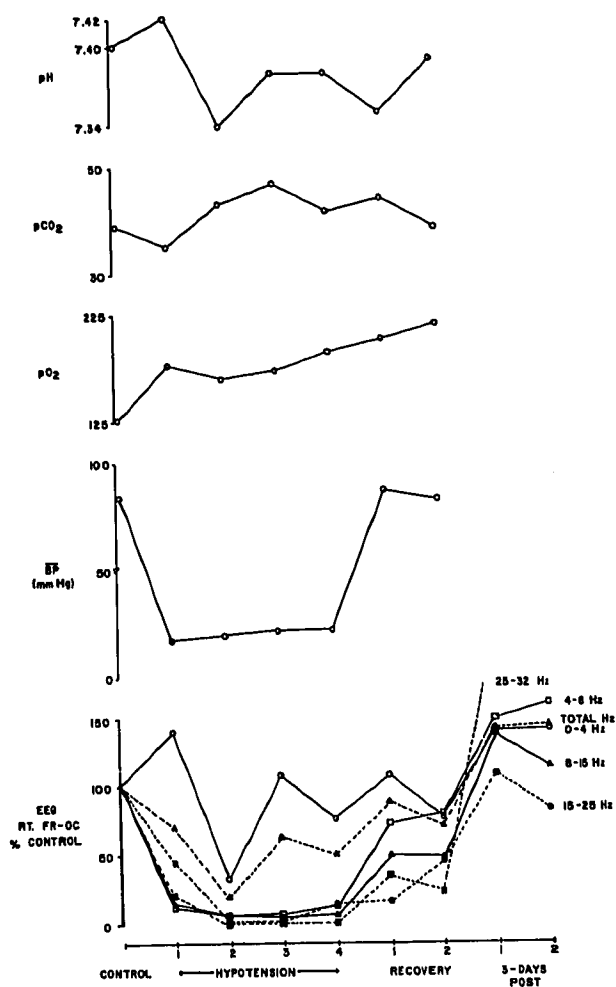
Induced hypotension is used to decrease blood loss and transfusion requirement, to provide a clear surgical field, and to increase the safety of certain vascular procedures. Cerebral oxygenation may be impaired when cerebral perfusion pressure (mean arterial pressure - intracranial pressure) falls below the range of autoregulation of cerebral blood flow. Studies were performed to determine if the electroencephalogram (EEG) or cerebral evoked potentials (EP) provide a reliable, sensitive monitor of the maximum degree of brain hypoxia that can be sustained without neuronal damage.

METHODS:

Male mongrel dogs were anesthetized with halothane and O₂, intubated and mechanically ventilated to achieve a normal end-tidal Pco₂. Inspired halothane concentration was adjusted to maintain blood halothane at 0.9 ± 0.1%. Arterial blood gases were measured every 10 minutes. Acid-base status was maintained normal by adjustment of minute ventilation and sodium bicarbonate infusion. Animal temperature was maintained at 37-38°C. Skull electrodes were implanted for EEG and EP measurements. EEG was recorded via a 6-channel bipolar montage similar to the parasagittal array of the standard international 10-20 system. Power spectral analysis of the EEG was performed. Somatosensory evoked potentials (SEP), elicited by electrical stimulation of the contralateral superficial radial nerve, were recorded from a frontal skull electrode referred to nose. Auditory evoked potentials (AEP), elicited by clicks, were recorded from a vertex electrode referred to mastoid. After recording control EEG, SEP, AEP, the dogs received trimethaphan (1.5 mg/kg IV bolus) to achieve a mean arterial pressure of 20 ± 3 torr for 1 hr. Two control animals did not receive trimethaphan. Neurological examination was performed daily following recovery. Three days later, the animals were again anesthetized and their heads perfused with normal saline followed by buffered formalin. The brain was removed for histopathology.

RESULTS:

The figure shows the mean values of arterial blood pressure, arterial Po₂, Pco₂ and pH, and the percentage change from control of EEG power in different frequency bands before, during and after hypotension in 9 dogs. Power in all frequency bands, except 0-4 Hz, was significantly reduced during and immediately after hypotension. Decrease in amplitude of cortical and brainstem SEP were observed during hypotension only, while no



change in brainstem AEP was noted. No latency changes occurred.

CONCLUSIONS:

Although changes in spontaneous electrical activity (EEG) and SEP compatible with hypoxia occurred, there was no electrophysiological, neurological or histopathological evidence of brain damage at blood pressures as low as 20 torr. Because of possible species differences in response to cerebral hypoxia, studies in non-human primates are currently in progress.

This study was supported by NIH Grant GM 25824.