

Title : CRYOANALGESIA: BIOPHYSICAL AND NEUROPATHOLOGIC EFFECTS

Authors : Heidi Heckman, B.S., Jordan Katz, M.D., William Nelson, M.D., and Henry Powell, M.D., Robert Myers, Ph.D.

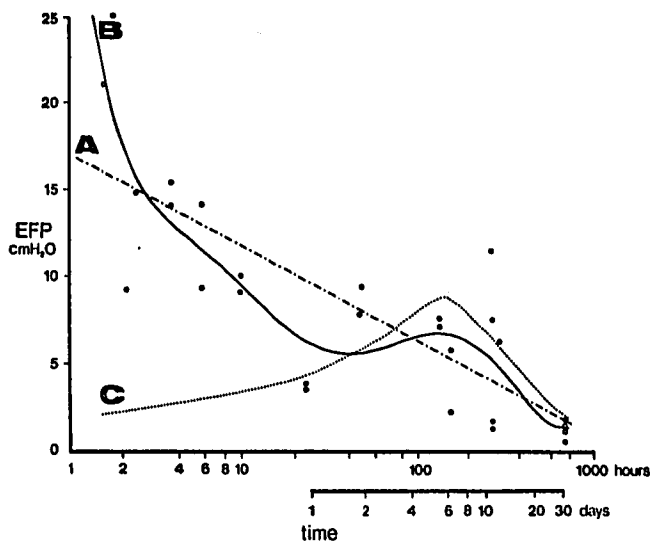
Affiliation: Veterans Administration Medical Center and University of California, San Diego, School of Medicine, Departments of Anesthesiology, Neuropathology, and Neurosciences, La Jolla, California 92093

Cryogenic lesions of intercostal nerves have been used therapeutically to reduce post-thoracotomy pain (1). Unlike conventional therapy cryoanalgesia is not associated with respiratory depression or hypotension, and is effective for 2-3 weeks following a single procedure performed at the end of thoracotomy. We explored the biophysical and neuropathologic sequelae of cryogenic lesions to peripheral nerves in 23 experimental animals to document changes in permeability, endoneurial fluid pressure (EFP), and nerve morphology.

METHODS. Sprague-Dawley rats were anesthetized with 110 mg/kg Inactin injected intraperitoneally. Both sciatic nerves were exposed. A Spemby BMS-40 cryosurgical unit was used with a specially designed probe (1) to form an ice-ball (-60 C) around the proximal portion of the exposed nerve for a 30 second period. This was followed by a 5 second thawing period and a second application of the probe for 30 seconds. The permeability of horseradish peroxidase (HRP) was tested in two animals and compared with changes known to occur in crush injury with Wallerian degeneration (2). Endoneurial fluid pressure was measured in 27 nerves at different times between 90 minutes and 32 days post-lesion. Following EFP measurement, the nerve was removed and placed in 2.5% phosphate-buffered gluteraldehyde and processed for microscopy. One-micron-thick sections for light microscopy were stained with paraphenylenediamine. Ultra-thin sections for electron microscopy were stained with uranylacetate.

RESULTS. Light microscopic examination of nerve distal to the site of cryoprobe application showed pronounced endoneurial edema characterized by wide separation of myelinated nerve fibers and perivascular and subperineurial fluid accumulation. Capillaries of the vasa nervorum were dilated and packed with erythrocytes. Larger vessels contained numerous erythrocytes with some walls lined with leucocytes closely applied to the endothelium. By electron microscopy mast cells showed degranulation, axons and Schwann cells were necrotic and there was injury to endothelial cells and pericytes. Numerous polymorphonuclear cells were seen closely applied to basement membrane of damaged endothelial cells. Altered vascular permeability was demonstrated by leakage of HRP at the site of injury and diapedesis of

polymorphonuclear cells through vessel walls. Wallerian degeneration was observed. EFP reached a peak of approximately 23 cm H₂O within 90 minutes after the lesion and returned to normal values (2.0 + 1.0 cm H₂O) by 32 days. A semilogarithmic plot of the data is given in the Figure. Line 'A' is a first-order regression of EFP vs. ln (time). Line 'B' is a sixth-order regression determined by computer and 'best-fits' the data. Line 'C' represents the relationship which exists between EFP and time for a peripheral nerve distal segment undergoing Wallerian degeneration following crush injury (2).



DISCUSSION. Our measurements suggest the superposition of two separate pathologic processes following cryogenic nerve lesion. There is extensive vascular damage giving rise to macromolecular and cellular extravasation which rapidly increases EFP. This, by itself, may be sufficient to cause local anesthesia (3). Secondly, nerve fibers undergo Wallerian degeneration with eventual recovery since the basement membrane is not disrupted by the lesion. Increased EFP due to Wallerian degeneration peaks at the sixth day post-lesion reflecting changes in permeability due to trauma and liberation of vasogenic amines as well as the accumulation of new Schwann cells and phagocytic cells in the endoneurial space.

(1) Katz J, Nelson W, et al., *Lancet* 8167: 512-513, 1980. (2) Powell H, Myers R, et al., *Annals of Neurology* 5:550-557, 1979. (3) Fink R, et al., *Anesthesiology* S1(3S): S220, 1979.