

CORRESPONDENCE

Anesthesiology
54:89, 1981

A New Technique for Location and Cannulation of the Internal Jugular Vein

To the Editor:—Percutaneous catheterization of the internal jugular vein to provide access to the central venous system has gained wide acceptance.*¹⁻³ Inadvertent puncture of the carotid artery may be a major complication, since a large-bore catheter may lead to hematoma formation. Accordingly, the use of a 22-gauge locator needle has been recommended. The locator needle may then be left in place and an appropriate catheter placed underneath, or the needle may be removed and a catheter inserted using the same entrance wound and direction.

The method we describe eliminates this additional step. A 22-gauge 14-cm spinal needle with the stylet removed is threaded through a 16-gauge catheter over needle (fig. 1). Using conventional landmarks, the entire assembly is inserted through the skin. The leading 4 cm portion of the 22-gauge needle is used to locate the vein. Once the internal jugular vein is entered, as ascertained by the flash of blood in the syringe, the catheter over needle is advanced approximately 6 cm into the vein. Both needles are then withdrawn. Satisfactory blood return from the catheter indicates internal jugular venous cannulation that may then be used as an intravenous route or for the introduction of a guide wire prior to central venous or pulmonary arterial catheterization. This technique eliminates two difficulties encountered using a separate locator needle. Occasionally one is able to locate the internal jugular vein with the locator needle, but is unable to cannulate the vein with the larger catheter. In addition, multiple punctures of the internal jugular vein are avoided, since the locator needle and the catheter over the needle assembly move as a unit through one venipuncture site. The advantage of a small-bore locator needle is retained.

CHARLES GIBBS, M.D.
Fellow

HERNANDO ARANDIA, M.D.
Assistant Professor

* Blitt D: Intraoperative Cardiovascular Monitoring: Invasive and Noninvasive. American Society of Anesthesiologists 1979 Annual Refresher Course Lectures; Lecture 215, 1979.

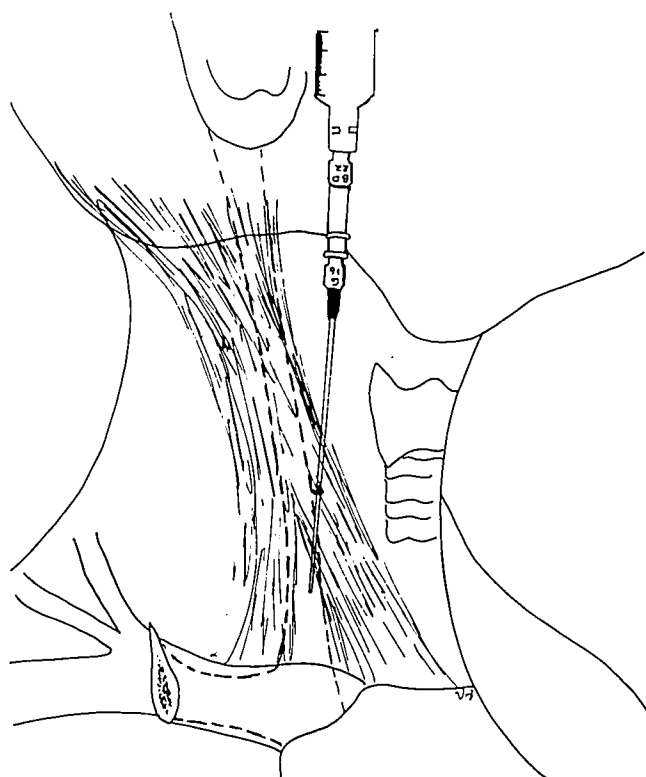


FIG. 1. Insertion of the entire assembly at the apex of the triangle and direction of the spinal needle into the jugular vein.

State University of New York
Upstate Medical Center
750 East Adams Street
Syracuse, New York 13210

REFERENCES

1. Webre DR, Arens JF: Use of cephalic and basilic veins for introduction of central venous catheters. *ANESTHESIOLOGY* 38:389-392, 1973
2. James PM, Myers RT: Central venous pressure monitoring: complications and a new technic. *Surgery* 39:75-81, 1973
3. Moosman DA: The anatomy of infraclavicular subclavian vein catheterization and its complication. *Surg Gynecol Obstet* 136:71-74, 1973

(Accepted for publication July 24, 1980.)