

# CLINICAL REPORTS

Ronald D. Miller, M.D., Editor

Anesthesiology  
54:164-166, 1981

## Caudal Anesthesia in a Patient with Ankylosing Spondylitis for Hip Surgery

JAMES W. DEBOARD, M.D.,\* JAWAHAR N. GHIA, M.D.,† W. BONNER GUILFORD, M.D.‡

Rheumatic joint diseases account for a significant proportion of orthopedic procedures, and their multisystem manifestations challenge the anesthetist's imagination and proficiency. Particularly troublesome are those patients with ankylosing spondylitis (Marie-Strumpell arthritis) in whom cervical fusion and flexion deformity make airway management for general anesthesia difficult. Additionally, ossification of interspinous ligaments and the formation of bony bridges (syndesmophytes) between vertebrae, resulting in a classic "bamboo spine" appearance, make placement of an epidural or spinal needle difficult or impossible. Fortunately, the possibility of regional anesthesia need not be excluded, because even in severe disease, access to the caudal canal can be gained via the sacral hiatus. The following case report describes successful anesthetic management for right total hip replacement using caudal block in a patient with ankylosing spondylitis.

### REPORT OF A CASE

A 50-year-old man who had an 18-month history of increasing pain in the right hip was admitted for right total hip arthroplasty. He had a 20-year history of ankylosing spondylitis and previously had had a left total hip replacement with general anesthesia; blind nasotracheal intubation had been accomplished with marked difficulty, and had been very distressful to the patient. Past medical history revealed diet-controlled diabetes mellitus and smoking for 18 pack years. He was taking no medication.

The patient weighed 80 kg. He had moderate kyphosis in the upper thoracic region, and walked with a cane. Spinal range of motion was present only at C1-C2, which allowed 20° of head flexion from 45° to 65° and 20° of bilateral rotation. He could open

his mouth only 4 cm. His abdomen was obese, and the lumbosacral curve was markedly flattened. Examination of the sacral hiatus and sacral cornu disclosed no abnormality. Right and left hip flexion were limited at 40° and 75°, respectively. Radiographs of the chest revealed moderate thoracic kyphosis and severe ankylosis of the vertebral bodies throughout the cervical, thoracic, and lumbar spine. However, anteroposterior (angled 10° caudad and 25-30° cephalad) and lateral views of the sacrum showed no evidence of bone deposition or bony fusion in the area of the caudal foramen (fig. 1). The type of anesthetic to be used the next day was discussed with the patient at great length. He refused awake endotracheal intubation and preferred a regional anesthetic. He was advised that there was a remote chance that endotracheal intubation might still be necessary despite the use of regional anesthesia. He accepted this possibility.

On the day of operation the patient received morphine 4 mg, im, and diazepam, 5 mg, orally. Subsequently, he did not appear to be anxious, and he was very cooperative throughout the procedure. With the patient in the left lateral position, the sacral canal was entered with an 18-gauge Tuohy needle. After negative aspiration for CSF, a non-styletted catheter was advanced 5 cm inside the caudal canal and 2 ml and 4 ml test doses of 3 per cent chlorprocaine hydrochloride were given, without adverse effect. The patient was then turned supine and 24 ml of 3 per cent chlorprocaine were administered.

Forty minutes later, a 30-ml volume of 0.5 per cent bupivacaine hydrochloride was injected. During the five-hour procedure, totals of 30 ml 3 per cent chlorprocaine 80 ml 0.5 per cent bupivacaine were given. There was no significant intraoperative problem, and both sensory and motor function had returned by the seventh hour after operation. Surgical blood loss was estimated to be 1,700 ml; 1,000 ml whole blood were replaced. The patient began tilt-table exercise three days postoperatively, ambulated on crutches nine days later, and was discharged two weeks postoperatively.

### DISCUSSION

Anesthetic management considerations included the patient's anesthetic preference, technical considerations for selection of continuous caudal anesthesia, potential airway maintenance problems, laryngeal damage, and the potential for postoperative pain and neurologic sequelae. Regional anesthesia was chosen in preference to general anesthesia based on these six considerations.

The choice of regional anesthesia for this patient

\* Anesthesiology Fellow.

† Associate Professor of Anesthesiology.

‡ Director of Skeletal Radiology.

Received from the Departments of Anesthesiology and Radiology, The University of North Carolina at Chapel Hill, North Carolina Memorial Hospital, Chapel Hill, North Carolina 27514. Accepted for publication August 22, 1980.

Address reprint requests to Dr. DeBoard.

Key words: Anesthetic techniques: epidural; caudal. Surgery, orthopedic.

was somewhat influenced by his unwillingness to undergo an awake endotracheal intubation. Careful planning regarding technical feasibility of achieving regional anesthesia necessitated a review of radiographs of the lumbosacral spine, which revealed that the placement of an epidural or spinal needle would be impossible. Ordinarily we would have dropped the idea of performing regional anesthesia at this point, but a very careful physical examination of the lumbosacral spine revealed an easily palpated hiatus. As the means of access to the caudal canal, special radiographs of the sacrum were obtained to confirm this impression and to rule out any deformity of the bone that might make the procedure technically difficult. Examination of the caudal foramen, in our experience, is best afforded by obtaining a spot lateral radiograph and anteroposterior view with cephalic or caudal angulation as needed. Without both of these views, small areas of ossification sufficient to impede catheter placement could be missed because of overlap of lateral margins of the posterior arch structures.

Inhalational induction of anesthesia with a mask and airway maintenance with the patient in the lateral position would have been especially difficult in this case. Reduced motion of the cervical spine and temporomandibular joint ankylosis predispose to respiratory obstruction and limit manipulations to correct it. Minimal opening of the mouth severely limits visualization of the larynx; in addition, atlantoaxial subluxation during intubation could result in spinal cord compression.<sup>1,2</sup> Despite careful attention to topical anesthesia, awake intubation may be quite unpleasant in a significant number of patients,<sup>3</sup> and indeed, had caused our patient to refuse it after his previous experience. Intubation after sleep would have been difficult and potentially hazardous because of limited opening of the mouth and the possibility of traumatizing the larynx. A history of progressive hoarseness and fullness of the throat in this patient suggested involvement of the cricoarytenoid joint, which is known often to be involved by the inflammatory process. Since laryngeal damage from intubation is quite common when joint ankylosis is present,<sup>4</sup> an anesthetic technique avoiding airway instrumentation would seem desirable.

Before final selection of continuous caudal anesthesia, we considered the potential risks of this procedure for this patient, which included hypotension, nausea, vomiting, systemic toxic reactions to local anesthetic and vasoconstrictors, high or total spinal block, and partial or complete failure to achieve an adequate block, subsequently necessitating supplementary anesthesia. Several of the above-mentioned complications of regional anesthesia would re-

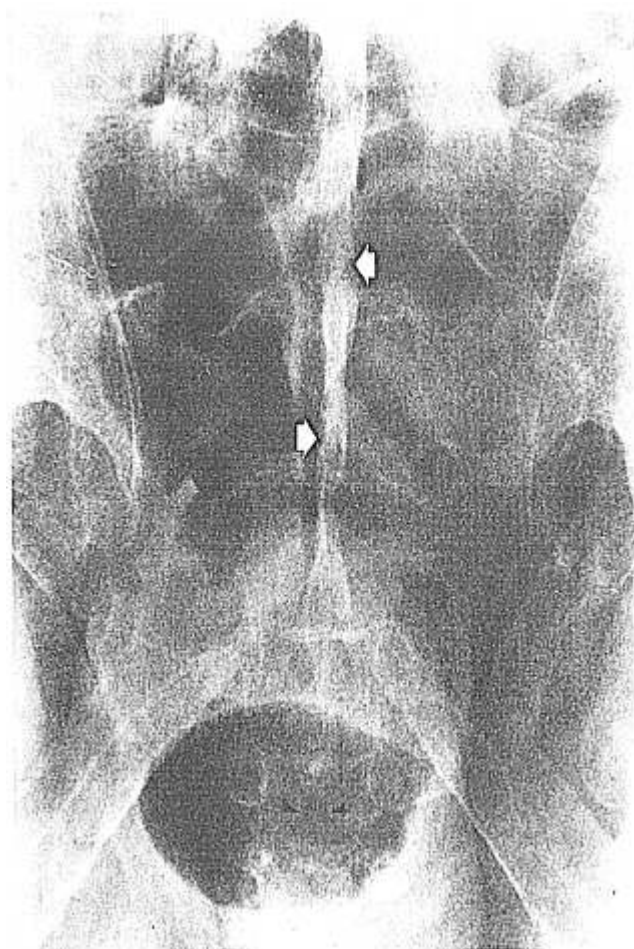


FIG. 1. Anteroposterior view of the sacrum with 25° cephalic angulation. Radiographs of the sacrum demonstrate total ossification of sacral interspinous and supraspinous ligaments (*arrows*). The caudal foramen is shown to be open and noncalcified (*arrowheads*).

quire assisted ventilation, which would initially be attempted via a mask, but might necessitate endotracheal intubation or even surgical access to the airway. The increased risk from an emergency rather than an elective endotracheal intubation, which this entailed, was explained to the patient, and he accepted it. Moreover, when we weighed the risks of caudal anesthesia against those of general anesthesia, we felt that the problems associated with caudal anesthesia were unlikely and manageable.

Since this report, we have successfully managed two additional similar patients with caudal epidural anesthesia, and advocate its use as the primary anesthetic approach in similar circumstances. For optimal results we suggest that anesthesia consultation should be obtained earlier during patients' visits to the orthopedic clinic when plans for surgical procedures begin. If caudal epidural anesthesia is

indicated, special sacral radiographs can often be obtained, along with radiographs of the pelvis and hips, with minimum extra cost or inconvenience to the patient.

## REFERENCES

1. Edelist G: Principles of anesthetic management in rheumatoid arthritic patients. *Anesth Analg (Cleve)* 43:227-232, 1964
2. Hassan I: Cauda equina syndrome in ankylosing spondylitis: a report of six cases. *J Neurol Neurosurg Psychiat* 39: 1172-1178, 1976
3. Kopman AF, Wollman SB, Ross K, et al: Awake endotracheal intubation: a review of 267 cases. *Anesth Analg (Cleve)* 54: 323-327, 1975
4. Phelps JA: Laryngeal obstruction due to cricoarytenoid arthritis. *ANESTHESIOLOGY* 27:518-522, 1966

Anesthesiology  
54:166-169, 1981

## Error in a Pipeline Gas Concentration: An Unanticipated Consequence of a Defective Check Valve

ROBERT A. BAGEANT, M.S., R.R.T.,\* JOHN W. HOYT, M.D.,† ROBERT M. EPSTEIN, M.D.‡

We found a major threat to patient safety resulting from a defective check valve in the air flowmeter of an IMV Emerson Ventilator simultaneously coupled with a 24 per cent decrease in the air pressure of the hospital's central pipeline system. These simultaneous failures caused a gross increase in oxygen concentration in the air pipelines.

The decrease in air pressure resulted from an open circuit breaker in one of the two main air compressors. An auxiliary air compressor was activated by a pressure switch in the air line preset to turn on at 40 psig. The pressure was 38 psig in the surgical intensive care unit (SICU) and in the newborn intensive care unit (NICU).

The IMV Emerson Ventilator (Model #3-MV) with an air-oxygen blending device, contained a defective check valve in the air flowmeter, which resulted in oxygen at 50 psig flowing backwards through the flowmeter into the central compressed air pipeline (fig. 1).

### PROBLEM IDENTIFICATION AND CORRECTION

Air pressure in the SICU was recognized as being low because low-pressure alarms on blenders were being activated. The NICU was then checked, because both areas were supplied by the same riser. In the

NICU, a nurse complained that the oxygen concentration in an infant hood was too high. Even with the oxygen flow turned off, the oxygen concentration remained above 21 per cent. With a calibrated oxygen analyzer (IMI Model #3300), the actual oxygen concentration in the air supply was measured at 33 per cent, later increasing to 40 per cent in the NICU and 80+ per cent in the SICU.

Because no new pipelines had been repaired or installed, oxygen was assumed to be entering the air lines from an external source connected to both air and oxygen high-pressure lines. All air-oxygen blenders in use were suspected as a possible source for crossover. After all air-oxygen blenders were disconnected, and the air compressor circuit breaker was closed, the problem was corrected.

Somewhat fortuitously, a new IMV Emerson ventilator was singled out for closer evaluation. To test its blender, equipment was set up as shown in figure 2. When air pressure was decreased, using the variable regulator, oxygen flowed backwards through the air flowmeter and control valve, and the oxygen percentage in the "air" line exceeded 80 per cent.

The check valve was removed from the air flowmeter and was found to be incompetent. The internal spring was broken and did not close the valve, as shown in figure 3. Because the valve looked identical to the check valve in an automobile tire, a tire valve stem was inserted in the rear of the air flowmeter. Although it fit well, the spring tension was greater, and 50 psig from the wall outlets would push a maximum flow of only 10 to 15 l/min of air through the valve. Thus, substitution was impossible. This valve has been replaced with an original from the J. H. Emerson Company, and additional check valves (Puritan-Bennett 255465) have been installed immediately behind the Emerson check valves.

\* Assistant Professor of Anesthesiology; Technical Director, Respiratory Therapy.

† Assistant Professor of Anesthesiology; Medical Director, Respiratory Therapy and Surgical Intensive Care Unit.

‡ Professor and Chairman Department of Anesthesiology.

Received from the Departments of Anesthesiology and Respiratory Therapy, University of Virginia Medical Center, Charlottesville, Virginia 22908. Accepted for publication September 18, 1980.

Address reprint requests to Mr. Bageant.

Key words: Equipment: cylinders; ventilators; medical gas systems. Oxygen: supply lines.