

oxide.⁷ The author does not know of any studies with inhalation agents currently in use.

In summary, thiopental dilates the pupils of most subjects but how the dilation occurs or why it is blocked by narcotics cannot be answered by this study.

The author thanks Dr. John P. Bunker for critically reviewing the manuscript.

REFERENCES

1. Cullen DJ, Eger EI, Steven WC, et al: Clinical signs of anesthesia. *ANESTHESIOLOGY* 36:21-36, 1972

2. Oono S: Pharmacological studies on pupillary reflex dilatation. *Jpn J Pharmacol* 65:91-112, 1965
3. Borgman H: Basic principles of clinical pupillography. Age dependence of the light reaction parameters. *Albrecht Von Graefes Arch Klin Exp Ophthalmol* 185:1-10, 1972
4. Larson MD: A new pupillometer for operating room use. *Anesthesiol Rev* 5:41-43, 1978
5. Bonvallet M, Zbrozyna A: Les commandes reticulaires du systeme autonome et en particulier de l'innervation sympathique et parasympathique de la pupille. *Arch Ital Biol* 101:174-207, 1963
6. Lee HK, Wang SC: Mechanism of morphine-induced meiosis in the dog. *J Pharmacol Exp Ther* 192:415-431, 1975
7. Guedel AE: *Inhalation Anesthesia*. New York, Macmillan, 1937, pp 25-36

Anesthesiology
54:249-253, 1981

Arterial Pressure Manipulation Alters Spinal Cord Function during Correction of Scoliosis

BETTY L. GRUNDY, M.D.,* CLYDE L. NASH, JR., M.D.,† RICHARD H. BROWN, PH.D.‡

Induced hypotension has been employed as a means of improving operating conditions and reducing blood loss during surgery for scoliosis.^{1,2} However, damage to the spinal cord,³ presumably secondary to ischemia, occurs.^{4,5} Effects of hypotension and direct pressure on the cord are additive in producing impairment of spinal cord function^{6,7} and restoration of function with correction of hypotension has been reported.⁸ The purported benefits of deliberate hypotension during operative treatment of scoliosis must be weighed against the possibility that hypotension might increase the risk of acute neurologic complications.

When patients awaken paraplegic after surgery for scoliosis, recovery of neurologic function is unlikely; but immediate removal of Harrington rod instrumentation improves prognosis.³ Assessment of spinal cord

function intraoperatively may therefore be helpful. This can be accomplished using either the "wake up test"^{9,10} or somatosensory cortical evoked potential (SCEP) monitoring.^{11,12} Scalp recorded cortical potentials evoked by stimulation of somatosensory nerves reflect impulse transmission in the dorsal columns of the spinal cord.¹³ Clinically, alterations of these potentials are sensitive indicators of damage to the cord.^{14,15} Studies of cord injury in animals have shown that SCEP changes correlate well with pathologic changes¹⁶ and neurologic outcomes.¹⁷ Though dorsal column transmission and SCEPs may be preserved in the presence of isolated ventral column lesions,¹⁸ traumatic myelopathy usually affects multiple tracts. Transmission of impulses by the dorsal columns often reflects the degree of spinal cord injury.^{15,16,19} Monitoring of evoked potentials has certain advantages over the wake up test. It can be performed continually, while the wake up test can be done only at intervals. SCEP monitoring avoids risks introduced by awakening the patient intraoperatively to check voluntary motor function (risks such as dislodgment of life support and monitoring devices, dislocation of orthopedic instrumentation and air embolism with deep inspiration).

One of our patients demonstrated SCEP changes reproducibly related to arterial pressure during Harrington rod instrumentation for uncomplicated idiopathic scoliosis. Because SCEP monitoring during anesthesia is relatively new and because a number of factors under the control of the anesthesiologist alter SCEPs, we include with this case report a descrip-

* Assistant Professor of Anesthesiology and Neurosurgery, University of Pittsburgh.

† Associate Professor of Orthopedics, Case Western Reserve University.

‡ Assistant Professor of Orthopedic Engineering, Case Western Reserve University.

Received from Case Western Reserve University, Cleveland, Ohio 44106, and University Hospitals of Cleveland. Accepted for publication September 22, 1980. Supported by Grants #1 R23 GM-26264-01 and GM-19599-06 from the National Institute of General Medical Sciences and by Grant #267 from the Orthopedic Research and Education Foundation.

Address reprint requests to Dr. Grundy, Department of Anesthesiology/CCM, 1060E Scaife Hall, University of Pittsburgh, Pittsburgh, Pennsylvania 15261.

Key words: Spinal cord; blood flow; pressure; function. Monitoring: somatosensory cortical evoked potential. Surgery: orthopedic; scoliosis. Anesthetic techniques: hypotension, induced.

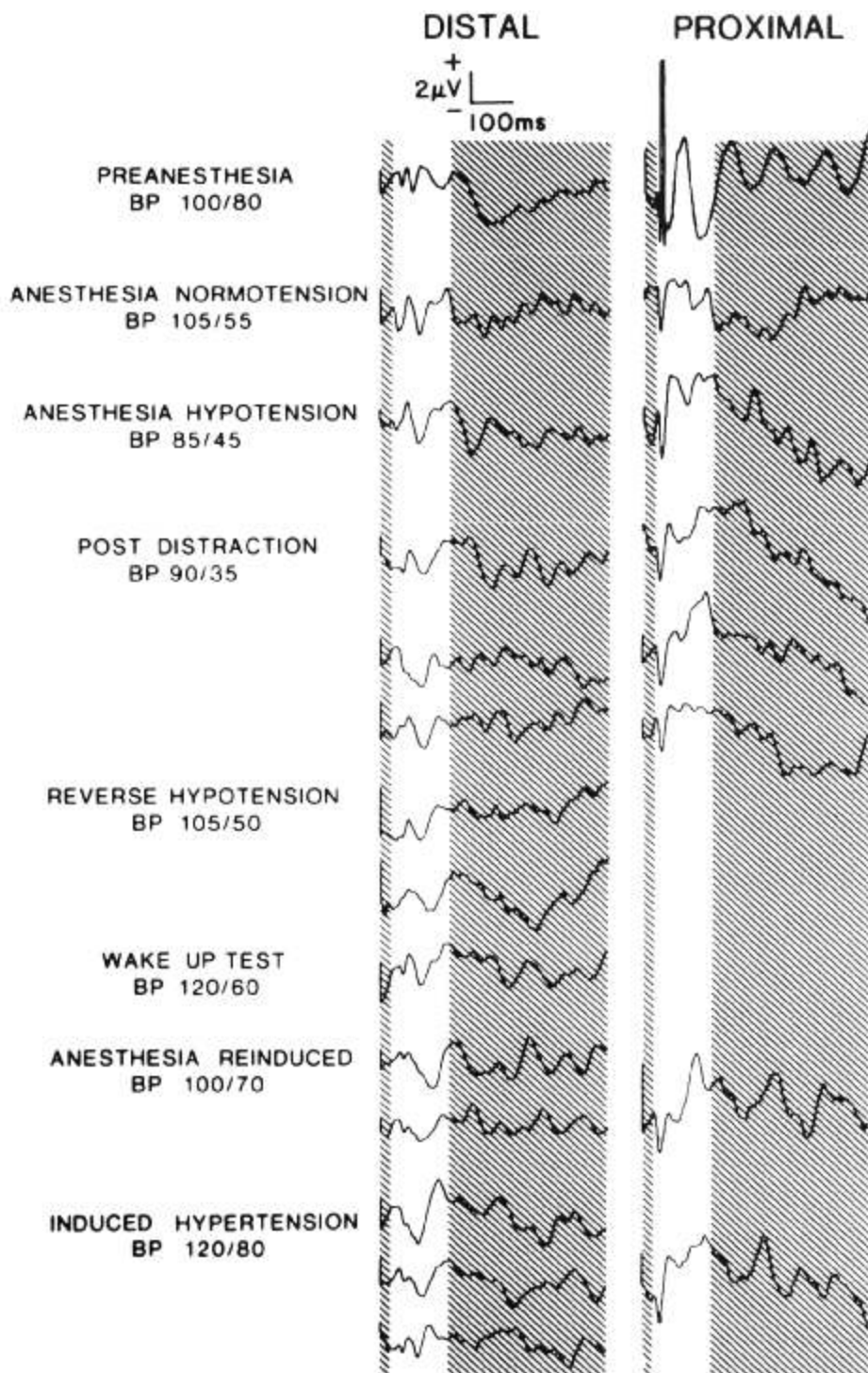


FIG. 1. Evoked potential waveforms photographed directly from untouched records obtained in the operating room. Note excessive variability of components more than 150 ms after stimulus. Only the early components are used in clinical decision making. Potentials evoked by median nerve stimulation (proximal) were stable after distraction of the spine, in contrast to potentials elicited by stimulation of the posterior tibial nerve (distal). Note particularly alteration of early peaks (20 to 50 ms poststimulus) and increases in poststimulus latency of the major negative peak.

tion of our protocol for intraoperative SCEP monitoring (see Appendix).

REPORT OF A CASE

A 23-year-old, 48.9-kg female in good general health was admitted for surgery to correct idiopathic adolescent scoliosis. History, physical examination, electrocardiogram and chest roentgenogram were unremarkable except for her orthopedic de-

formity. Spine films showed a right T6 to L2 curve, 60 degrees standing, 32 degrees side-bending, 30 degrees in preoperative cast. Arterial blood pressure was 102/80 torr. Preoperative hematocrit was 35 per cent. Other laboratory values were within normal limits. Spine fusion with Harrington rod instrumentation was scheduled and anesthesia with nitrous oxide, thiopental, narcotic and muscle relaxant was uneventful. Sodium nitroprusside (less than 10 μ g/kg/min) served to maintain systolic arterial pressure 80-90 torr. Goldstein¹ believes that this pressure minimizes bleed-

ing from cortical bone, and with subcutaneous epinephrine 1:500,000, soft tissue bleeding is not excessive. Arterial P_{O_2} ranged from 123 to 170 torr, P_{CO_2} 31 to 46 torr, pH 7.34 to 7.49, hematocrit 38 to 28 per cent. Earlobe hemoglobin saturation was 97 per cent or greater throughout.

SCEPs recorded during stimulation of the posterior tibial nerve immediately following distraction (straightening or stretching) of the spine showed marked and progressive deterioration, while responses evoked by stimulation of the median nerve remained stable (fig. 1). At this time Pa_{O_2} was 146 torr, Pa_{CO_2} 43 torr, pH_a 7.37 and hematocrit 28 per cent. Because of the SCEP changes, nitroprusside was discontinued and intravenous crystalloid administration begun. Arterial systolic blood pressure rose from 85 to 105 torr but responses evoked by stimulation of the posterior tibial nerve did not return toward predistracted patterns until the patient was awakened (100 per cent oxygen, atropine 0.6 mg, prostigmin 0.5 mg) to test motor function in the distal extremities. During the wake up test systolic blood pressure rose to 30 per cent above preoperative levels and SCEPs improved. When adequate motor function in both feet was confirmed, anesthesia was reinduced with 70 per cent nitrous oxide and thiopental 100 mg. Arterial systolic blood pressure fell to preoperative levels and SCEPs evoked by stimulation at the ankle again deteriorated. We attributed these SCEP changes to spinal cord ischemia produced by straightening of the spine. Because both SCEPs and the wake up test had been satisfactory at a slightly higher arterial blood pressure, we decided to return the blood pressure to that level rather than reducing our correction of the spinal deformity. If continual SCEP monitoring intraoperatively and frequent neurological assessment postoperatively showed intact cord function the patient would be able to enjoy the benefits of full correction with little risk of neurologic damage. Arterial blood pressure was therefore raised to 20 per cent above baseline values by additional intravenous crystalloid, atropine (0.6 mg over 10 min) and small doses of mephenteramine (4.5 mg over 8 min). SCEPs immediately improved and no further deterioration in evoked responses occurred despite additional distraction and compression instrumentation of the spine. A second wake up test before wound closure again demonstrated symmetrical motor function in both legs. Anticipating continued blood loss into the wound after surgery, we replaced the 710 ml measured blood loss with two units of whole blood. We infused 1975 ml of crystalloid solution. Intraoperative urine output was 215 ml. Relative hypervolemia allowed maintenance of modest hypertension throughout the early hours of recovery without need for vasopressors. Hematocrit on the first postoperative day was 34 per cent. Neurologic function was normal throughout. Spinal curvature was 30 degrees immediately after operation and 28 degrees in the homegoing cast.

DISCUSSION

Our patient exhibited none of the factors such as congenital scoliosis, preoperative neurologic deficit and severe rigid curvature that are known to increase the risk of neurologic damage during operative treatment of scoliosis.³ Yet distraction of the spine during modest hypotension (approximately 20 per cent below preoperative baseline values) altered cortical potentials evoked by stimulation of the posterior tibial nerve while potentials evoked by

stimulation of the median nerve remained stable. The impaired cortical response to stimulation of the distal extremity was reproducibly responsive to modest increases in arterial blood pressure (approximately 20 per cent above preoperative baseline values).

The mechanism of injury to the spinal cord during operative treatment of scoliosis may be ischemic in nature.^{4,5} The spinal cord's blood supply can be compromised by stretching or other mechanical distortion of the cord as well as by pressure on blood vessels or on the cord itself. Hypotension exacerbates damage produced by direct pressure on the cord.⁶ Ponte⁸ reported that two patients, who developed acute paraplegia in the recovery room after scoliosis fusion, had partial recovery of neurologic function when blood was infused to correct hypovolemic hypotension in preparation for removal of Harrington rods.

We believe that the altered SCEPs seen in our patient after straightening of the spine may have been indicative of spinal cord ischemia and that return of these potentials toward normal with modest hypertension represented improved spinal cord function secondary to enhanced perfusion. SCEP changes due primarily to changing depth of anesthesia should have been seen in potentials evoked by median nerve stimulation as well, yet these potentials remained stable throughout. We cannot tell what role, if any, the induced hypertension may have played in determining our patient's favorable neurologic outcome. It nevertheless seems possible that without intraoperative monitoring of spinal cord function, this seemingly low risk patient may well have suffered permanent neurologic damage. We now monitor cord function intraoperatively using either somatosensory cortical evoked potential recording or the wake up test in all patients having induced hypotension as an adjunct to anesthesia for operative treatment of scoliosis.

APPENDIX

We use a mobile monitoring system based on a Data General Nova 2/10[®] digital computer and developed by one of the authors (RHB). Platinum subdermal electrodes serve for scalp recording and peripheral nerve stimulation; gold cup ear clip electrodes serve for patient ground. We stimulate the posterior tibial nerve at the ankle and the median nerve at the wrist, recording from electrodes just posterior to respective primary somatosensory areas (2 cm posterior to C1²⁰ and 2 cm posterior to C3, each referred to F3; 2 cm posterior to C2 and 2 cm posterior to C4, each referred to F4). The on-going electroencephalogram (EEG) is monitored on an oscilloscope. For each averaged

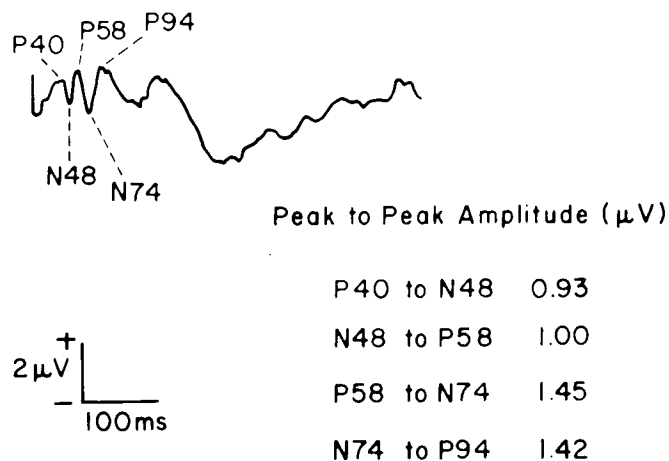


FIG. 2. Single wave form (distal-preanesthesia) with labelled peaks and amplitude measurements. Peaks are labelled P for positive and N for negative with numbers indicating poststimulus latency.²²

SCEP, 64 stimuli are delivered at pseudorandom intervals of 1–1.4 s. Stimuli are monopolar constant current square wave pulses of 300 μs duration, set before anesthesia to produce visible but painless motor stimulation and during anesthesia at 20 milliamperes (ma). The battery powered stimulators are photocoupled and automatically deactivate at an energy level equivalent to 20 ma 500 μs -duration. The short duty cycle (300 μs every 1.2 s) and the relatively short duration of recording minimize electrode polarization.

Evoked EEG responses are recorded for 512 ms after each stimulus. Signals are amplified 12 inches from the electrodes using double buffered isolation amplifiers with differential input impedance of 200,000 ohms balanced to ground. The isolation amplifiers provide a gain of 50 in voltage but more than 1000 in power. The cable then sees only a 10 ohm source impedance, but the system provides 10²⁴ ohm isolation for the patient. Signals are led from the isolation amplifiers to Gould EEG amplifiers[®] (bandwidth 0.3–90Hz) then to the Nova 2/10[®] computer (16 K core memory, 8 channels 10 bit A-D converters, 2 channels 12 bit D-A converters, digital I/O for controlling the monitoring system, ASR-33 teletype for user-system interaction). The EEG is sampled at 500 Hz. Developing evoked response wave forms are displayed on a 611 Tektronix[®] cathode ray tube with associated hard copy unit. SCEPs are visually inspected and manually measured in the operating room. Each full set of records includes three averages of responses evoked by stimulation at each of the four peripheral nerve sites as well as background averages recorded in the absence of stimulation. Digitized SCEP data are stored on cassette tapes and subsequently played into a Data General Nova 800[®] digital computer (32K core memory) for measurement of peak latencies and peak-to-peak amplitudes using a controllable cursor program (see fig. 2).

Anesthetic techniques are designed to keep factors affecting SCEPs as constant as possible so that evoked

wave forms will be relatively stable. Halogenated anesthetics¹¹ and droperidol²¹ are not used. Bolus injection of intravenous agents is avoided during critical phases of the operation because anesthetics can alter SCEPs at the cortical level when cord function is intact. Other factors known to affect evoked potentials (temperature, blood gases) are monitored. Potentially confounding factors must be controlled if SCEP changes are to reflect changes in spinal cord function produced by operative manipulation.

REFERENCES

- Goldstein LA: Surgical management of scoliosis. *J Bone Joint Surg* 48-A:167–196, 1966
- McNeill TW, DeWald RL, Kuo KN, et al: Controlled hypotensive anesthesia in scoliosis surgery. *J Bone Joint Surg* 56-A:1167–1172, 1974
- MacEwen GD, Bunnell WP, Sriram K: Acute neurological complications in the treatment of scoliosis: A report of the Scoliosis Research Society. *J Bone Joint Surg* 57-A: 404–408, 1975
- Moe JH, Winter RB, Bradford DS, et al: *Scoliosis and Other Spinal Deformities*. Philadelphia, WB Saunders, 1978
- Winter RB: Treatment of scoliosis and possible neurologic complications, *Spinal Deformities and Neurological Dysfunction*. Edited by Chou SN, Seljeskog EL. New York, Raven Press, 1978, pp 209–230.
- Brodkey JS, Richards DE, Blasingame JP, et al: Reversible spinal cord trauma in cats: Additive effects of direct pressure and ischemia. *J Neurosurg* 37:591–593, 1972
- Hardy RW, Nash CL, Brodkey JS: Experimental and clinical studies in spinal cord monitoring: The effects of pressure, anoxia and ischemia on spinal cord function. *J Bone Joint Surg* 55-A:435, 1973
- Ponte A: Postoperative paraplegia due to hypercorrection of scoliosis and drop of blood pressure. *J Bone Joint Surg* 56-A:444, 1974
- Vauzelle C, Stagnara P, Jouvinroux P: Functional monitoring of spinal cord activity during spinal surgery. *Clin Orthop Rel Res* 93:173–178, 1973
- Sudhir KG, Smith RM, Hall JE, et al: Intraoperative awakening for early recognition of possible neurologic sequelae during Harrington rod spinal fusion. *Anesth Analg (Cleve)* 55:526–528, 1976
- Nash CL, Lorig RA, Schatzinger LA, et al: Spinal cord monitoring during operative treatment of the spine. *Clin Orthop Rel Res* 126:100–105, 1977
- Engler GL, Spielholz NI, Bernhard WN, et al: Somatosensory evoked potentials during Harrington instrumentation for scoliosis. *J Bone Joint Surg* 60-A:528–532, 1978
- Cusick JF, Myklebust JB, Larson SJ, et al: Spinal cord evaluation by cortical evoked responses. *Arch Neurol* 36:140–143, 1979
- Perot PL: The clinical use of somatosensory evoked potentials in spinal cord injury. *Clin Neurosurg* 20:367–381, 1972
- Rowed DW, McLean JAG, Tator CH: Somatosensory evoked potentials in acute spinal cord injury: Prognostic value. *Surg Neurol* 9:203–210, 1978
- D'Angelo CM, VanGilder JC, Taub A: Evoked cortical potentials in experimental spinal cord trauma. *J Neurosurg* 38:332–336, 1973
- Martin SH, Bloedel JR: Evaluation of experimental spinal cord injury using cortical evoked potentials. *J Neurosurg* 39:75–81, 1973
- Halliday AM, Wakefield GS: Cerebral evoked potentials in

- patients with dissociated sensory loss. *J Neurol Neurosurg Psychiatr* 26:211-219, 1963
19. Larson SJ, Holst RA, Hemmy DE, et al: Lateral extracavitary approach to traumatic lesions of the thoracic and lumbar spine. *J Neurosurg* 45:628-637, 1976
20. Jasper HH: The ten twenty electrode system of the International Federation. *Electroenceph Clin Neurophysiol* 10: 371-375, 1958

21. Grundy BL, Brown RH, Clifton PC: Effect of droperidol on cortical evoked potentials (abs). *Electroencephal Clin Neurophysiol* 50:158P-159P, 1980
22. Donchin E, Callaway E, Cooper R, et al: Publication criteria for studies of evoked potentials (EP) in man, Attention, Voluntary Contraction and Event-Related Cerebral Potentials. *Prog Clin Neurophysiol*, 1. Edited by Desmedt JE. Basel, Karger, 1977, pp 1-11.

Anesthesiology
54:253-255, 1981

Massive Intraoperative Pulmonary Tumor Embolus from Renal Cell Carcinoma

BRIAN MILNE, M.D.,* FRANK W. CERVENKO, M.D.,† ALVARO MORALES, M.D.,‡ TOMAS A. SALERNO, M.D.§

Renal cell carcinoma occasionally invades the inferior vena cava (IVC). In such patients a radical nephrectomy and complete removal of the tumor thrombus from the IVC is required.¹ Intraoperative problems encountered include massive hemorrhage, decrease in venous return due to manipulation of the IVC, tumor obstruction of the outflow of the right ventricle,² and air and tumor pulmonary embolus.³ Fatal results have been reported with massive tumor embolization to the lungs during surgery.⁴ This report describes the recognition and successful treatment of intraoperative massive tumor embolus to the lungs by the rapid institution of cardiopulmonary bypass (CPB) and removal of the tumor from the pulmonary artery.

REPORT OF A CASE

A 15-year-old girl, weighing 57 kg, was admitted for investigation of shortness of breath, chills, fever, dry cough, and chest wall and back pain. Physical examination revealed a pale girl with decreased breath sounds in the right lower lung field and a palpable mass in the right upper quadrant of the abdomen. The hemoglobin was 10.9 g/dl. Electrolytes, platelet count, prothrombin time, partial thromboplastin time, blood urea nitrogen, creatinine, and serum glutamic oxaloacetic transaminase were within normal limits. Lactic acid dehydrogenase was elevated to 266 IU/l

(normal 0-110). The chest roentgenogram revealed a large right-sided pleural effusion, which was drained preoperatively, with bilateral basal inflammatory changes. A renal arteriogram revealed a large mass arising from the mid portion of the right kidney. Venous angiography showed the IVC to be totally occluded at the level of T 12 (fig. 1).

After the intravenous administration of diazepam, 7.5 mg, and fentanyl, 25 µg, a left radial artery catheter and a right atrial catheter were inserted under local anesthesia for continuous monitoring of arterial blood pressure and central venous pressure (CVP). Anesthesia was induced with thiopental, 300 mg, intravenous (iv), and after succinylcholine, 60 mg, iv, the trachea was intubated. Anesthesia was maintained with 50 per cent nitrous oxide, halothane at an inspired concentration of 0.5-1.0 per cent, 25 µg increments of fentanyl, and pancuronium.

With CPB available on standby and the patient in the right lateral decubitus position, a radical nephrectomy was performed. The pH_a was 7.38, Pa_{O_2} 220 torr, Pa_{CO_2} 39 torr, HCO_3^- 22 mEq/l, 30 min after induction of anesthesia. Following control of the IVC at the diaphragm and bifurcation, the tumor thrombus was removed from the IVC. After closure of the venotomy, when all thrombus was thought to have been removed and the cava irrigated with normal saline, a sudden decrease in arterial blood pressure from 110 torr to 30 torr systolic occurred. A sinus tachycardia of 125 beats/min and cyanosis immediately followed. With an increase in the CVP from 4 to 32 cm H_2O , absence of a mill-wheel murmur, and inability to aspirate air through the CVP catheter (to rule out air embolism), the diagnosis of pulmonary tumor embolus was made. Ventilation with 100 per cent O_2 and a dopamine infusion were immediately instituted. The patient was then turned to the supine position in preparation for a median sternotomy. After heparinization (200 units/kg) and cannulation of the right femoral artery, CPB was instituted following sternotomy and cannulation of both vena cavae. The time from the beginning of hypotension to commencement of CPB was approximately 10 min, during which time cardiac arrest occurred requiring closed and then open cardiac massage. Sodium bicarbonate (50 mEq) and dexamethasone (20 mg) were given intravenously. After the cavae had been snared, the main pulmonary artery was opened and large amounts of tumor thrombus was removed with forceps from both the left and right pulmonary arteries. Residual tumor was removed by using a Fogarty catheter and by having both pleural spaces opened and both lungs manually compressed. After closure of the pulmonary artery, the patient could not be

* Resident, Department of Anesthesia.

† Associate Professor, Department of Anesthesia.

‡ Associate Professor, Department of Urology.

§ Assistant Professor, Department of Surgery.

Received from the Departments of Anesthesia, Urology and Surgery, Queen's University, Kingston, Ontario, Canada. Accepted for publication September 23, 1980. Supported by the Ontario Heart Foundation, Grant 2-4.

Address reprint requests to Dr. T. Salerno, Department of Surgery.

Key words: Embolism; thromboembolism. Kidney: disease; carcinoma. Lung: embolus. Complications: hypotension. Surgery: extracorporeal circulation.