

be prudent to consider supplementing high-dose fentanyl anesthesia with nitrous oxide (50 per cent), or halothane (0.3–0.5 per cent) at those times corresponding to intense surgical stimulation.

REFERENCES

1. Stanley TH, Webster LR: Anesthetic requirements and cardiovascular effects of fentanyl–oxygen and fentanyl–diazepam–oxygen anesthesia in man. *Anesth Analg (Cleve)* 57:411–426, 1978
2. Cherkin A, Harroun P: Anesthesia and memory process. *ANESTHESIOLOGY* 34:469–474, 1971
3. Eisele V, Weinreich A, Bartles S: Perioperative awareness and recall. *Anesth Analg (Cleve)* 55:513–518, 1976
4. Abouleish E, Taylor FH: Effect of morphine–diazepam on signs of anesthesia, awareness and dreams of patients under N₂O for cesarean section. *Anesth Analg (Cleve)* 55:702–705, 1976
5. Stoelting R, Gibbs P: Hemodynamic effects of morphine and morphine–nitrous oxide in valvular heart disease and coronary artery disease. *ANESTHESIOLOGY* 38:45–52, 1973
6. Lunn JK, Stanley TH, Eisele J, Webster L, Woodward A: High dose fentanyl anesthesia for coronary artery sur-

- gery: plasma fentanyl concentrations and influence of nitrous oxide on cardiovascular responses. *Anesth Analg (Cleve)* 58:390–395, 1979
7. Hess R, Herz A, Friedel K: Pharmacokinetics of fentanyl in rabbits in view of the importance of limiting the effect. *J Pharmacol Exp Ther* 179:474–484, 1971
8. Blacher, RS: On awakening paralyzed during surgery: a syndrome of traumatic neurosis. *JAMA* 234:67–68, 1975
9. Wilson SL, Vaughan RW, Stephen CR: Awareness, dreams and hallucinations associated with general anesthesia. *Anesth Analg (Cleve)* 54:609–617, 1975
10. Grell FL, Koons RA, Denson JS: Fentanyl in anesthesia—a report of 500 cases. *Anesth Analg (Cleve)* 49:523–532, 1970
11. Frumin MJ, Henkar VR, Jarvik ME: Amnesic actions of diazepam and scopolamine in man. *ANESTHESIOLOGY* 45: 406–412, 1976
12. Fragen RJ, Caldwell N: Lorazepam premedication: lack of recall and relief of anxiety. *Anesth Analg (Cleve)* 55: 792–796, 1976
13. Harris TJB, Brice DD, Heterington RR: Dreaming associated with anesthesia: the influence of morphine premedication and two volatile adjuvants. *Br J Anaesth* 43: 172–178, 1971

Anesthesiology
54:343–345, 1981

Ulnar Artery Occlusion Simulating Reflex Sympathetic Dystrophy

FRED J. SPIELMAN, M.D.,* JAWAHAR N. GHIA, M.D.,† EDWARD TEEPLE, M.D.,‡ VALERIE S. MANDELL, M.D.§

Diagnosis of intense burning pain in an extremity following trauma resulting from a high velocity impact of an object is caused by reflex sympathetic dystrophy (RSD).¹ It differs from true causalgia in that no demonstrable peripheral nerve injury has occurred. Most commonly, this type of pain follows fractures, sprains, or sharp and blunt trauma to soft tissues. In this report, we describe a case of ulnar artery occlusion simulating RSD. Systematic evaluation during a series of stellate ganglion nerve blocks helped establish the diagnosis which saved the patient from undergoing an unnecessary surgical sympathectomy.

REPORT OF A CASE

A 53-year-old man who worked as a textile machine operator sought treatment at the University of North Carolina Multidisciplinary Pain Clinic because of a two-month history of pain, paresthesias, and intermittent cyanosis in the fourth finger of his right hand. A throbbing and burning pain began a few seconds after he sustained an injury to the involved finger in a spinning frame (a high-velocity, low-weight object) at the mill where he worked. The pain worsened over the next several days, and was accompanied by swelling and cold sensations in the finger tip, with intermittent periods of paresthesias. One week after the injury, he noticed the right hand to be cold and cyanotic. The burning pain had spread to his right hand, and the entire right upper extremity experienced associated weakness. Treatments prior to arrival at the Multidisciplinary Pain Clinic consisted of acetylsalicylic acid and codeine for pain, and oral reserpine.

A summary of positive findings reported by the referring physician consisted of a history of smoking for sixty pack years. Roentgenogram of the right ring finger obtained after the initial injury showed no evidence of a fracture or foreign body. The patient's right hand was cool and showed a slow capillary refill. Doppler examination of the right radial and ulnar arteries were within normal limits. Plethysmographic flow studies of the right ring finger were consistent with sympathetic based arteriospasm. Intra-arterial reserpine was tried in an effort to improve circulation in the affected finger.² Following the injection of 1 mg reserpine in the right brachial artery, an immediate warming of the right hand was observed. Shortly after the injection, the patient de-

* Anesthesiology Resident, Department of Anesthesiology.

† Associate Professor of Anesthesiology, Department of Anesthesiology.

‡ Anesthesiology Fellow, Department of Anesthesiology.

§ Assistant Professor of Radiology, Department of Radiology.

Received from the Departments of Anesthesiology and Radiology, the University of North Carolina at Chapel Hill, North Carolina Memorial Hospital, Chapel Hill, North Carolina 27514. Accepted for publication October 21, 1980.

Address reprint requests to Dr. Spielman.

Key words: Anesthesia; diagnostic. Anesthetic techniques, regional; stellate; sympathetic block. Sympathetic nervous system; dystrophy. Arteries: ulnar.

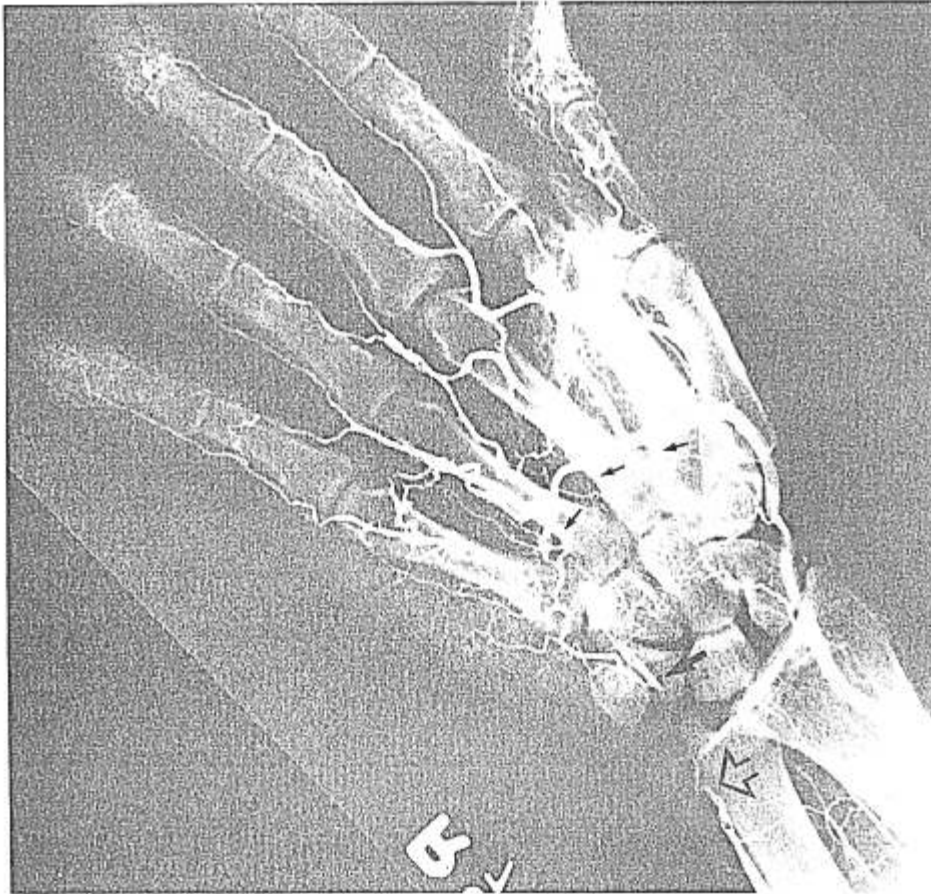


FIG. 1. A selective right brachial arteriogram showing an occlusion of the right distal ulnar artery proximal to the origin of the superficial volar arch (open arrow), a small segment of which (closed arrow) is retrogradely filled via the deep arch from the radial carpal artery (small arrows).

veloped a generalized erythema and a severe burning and itching sensation over the entire body which subsided spontaneously after eight hours. The work-up for collagen vascular disease consisting of laboratory results for antinuclear antibody titer, serum protein electrophoresis rheumatoid factor, and erythrocyte sedimentation rate, were all within normal limits. The burning pain in the right ring finger and the sequence of events which lead to progressive involvement of the right upper extremity were compatible with diagnosis of RSD; however, vasospastic component (Raynaud's-like phenomenon) secondary to repeated trauma resulting from his occupation could not be ruled out.

Physical examination at the Pain Clinic revealed a slight decrease in strength in his right hand. Pulses in his upper extremities were bilaterally equal on gross examination. The distal part of the affected finger had decreased sensation to pinprick, was cool, had poor capillary refill, and was hyperesthetic and cyanotic. No hair changes or sweating disturbance were observed. The skin had a smooth, shiny appearance.

Upon completion of history and physical examination, psychological evaluation was performed and results were within normal limits. A diagnostic right stellate ganglion block was then performed. Sympathetic function was evaluated by measuring skin temperature over the entire upper extremities bilaterally under standardized conditions. Color changes, flushing condition of the skin (dry or moist), vasodilatation, and any subjective feelings of warmth by the patient were recorded. Control temperature of the volar aspect of the affected finger showed a temperature of 27° C distal to the proximal interphalangeal joint when compared to

32.5° C on a corresponding point on the normal side. This temperature difference decreased from 5.5° C to 0.5° C at the bases of the fingers. Prior to any local anesthetic injection, a placebo injection using 2 ml of physiologic saline in the subcutaneous tissue superficial to the anatomic location of the stellate ganglion produced 50 per cent pain reduction with no significant change in temperature. Fifteen minutes after the first injection, the right stellate ganglion was blocked using 10 ml of 1 per cent lidocaine, employing the technique described by Löfström.³ This was followed by a temperature rise to 30° C in the affected finger, subjective report of warmth, and complete pain relief, which lasted six hours. Temperature in the ring finger on the normal side remained stable at 32° C following the block. Upon completion of the stellate ganglion block, a modified Allen's test⁴ revealed a significant decrease in the right ulnar filling with the right radial artery occluded at the wrist.

Complete pain relief which lasted for 4–6 hours following the first block, in face of objective findings compatible with vascular obstruction, was somewhat puzzling. Diagnosis of RSD could not be ruled out on the basis of the first block; therefore, further nerve blocks were performed. Another reason for performing additional blocks was to provide some relief of pain; however, the patient received decreasing pain relief with three subsequent stellate ganglion blocks which included one technical failure. These nerve blocks consistently failed to show any significant (more than 2° C) temperature rise in the affected finger and in the ulnar distribution of the right hand. Furthermore, with one block, in addition to temperature measurements, plethysmography was used

which failed to show an increase in right ulnar flow. With this information, we advised surgeons to obtain an arteriogram to rule out the right ulnar artery occlusion.

A selective right brachial arterial injection of a contrast media showed right distal ulnar artery occlusion proximal to the origin of the superficial volar arch. The injection of tolazoline hydrochloride, 12.5 mg, through the angiographic catheter just prior to contrast injection, did not alter the morphology of the lesions when compared to the baseline angiogram without the vasodilator, indicating that no significant spastic component was present (fig 1). Consulting surgeons felt that revascularization of the area was not feasible, and the patient underwent an amputation of his right ring finger under general anesthesia, with alleviation of his pain. At the time of discharge on the second postoperative day, the patient had a slight numb feeling persistent in the little finger of his right hand. His postoperative visit, four months following the surgery, revealed the patient to be free of pain.

DISCUSSION

Pain, hyperesthesia, vasomotor disturbances, and trophic changes in the affected finger secondary to trauma resulting from an object with a high velocity impact, and impaired function of the right upper extremity made a strong case in favor of RSD in this patient. This impression was further strengthened by complete pain relief which the patient reported following the first sympathetic block. However, absence of sweating disorder, lack of response to emotional stimuli, failure to note an increase in temperature in the affected finger following a sympathetic block, poor right ulnar filling on modified Allen's test, and a gradual decrease in effectiveness of the second, third and fourth blocks to relieve pain, strengthened the case against the diagnosis of RSD. With each subsequent block, temperature changes were studied bilaterally in the entire upper extremity which strengthened our impression of obstructive flow pattern in the right ulnar artery.

The etiology of the patient's vascular occlusion is unknown. Quite possibly, he suffered a compression

injury to the right ulnar artery at the time he injured his finger; however, chronic trauma from frequent use of hand tools (Jack-Hammer syndrome⁶) and/or possible role of concomitant peripheral vascular disease could not be ruled out. Pain, hyperesthesia, and vasomotor changes were felt to be caused by relative ischemia of the fourth and fifth fingers of the right hand which received blood only through the radial collateral supply. Pain relief following the block might have resulted from improvement of these collaterals to the ulnar distribution and/or placebo effects which gradually diminished with subsequent blocks. Prolonged relief after amputation of the affected finger, absence of psychological findings, and prompt settlement of injury-dependent disability, would suggest that the pain was due to the occlusion.

Finally, a common practice of gross clinical measurement of temperature in the affected extremity in a trauma patient can be misleading and a diagnosis of vascular occlusion may be missed even by the most astute physicians, as exemplified by this case. We recommend measuring skin temperature of the individual fingers or toes in diagnosis of every trauma patient who reports pain in the extremities.

REFERENCES

1. Bonica JJ: Causalgia and other reflex sympathetic dystrophies. *Postgrad Med* 53:143-148, 1973
2. Acevedo A, Reginato AJ, Schnell AM: Effect of intra-arterial reserpine in patients suffering from Raynaud's phenomenon. *J Cardiovas Surg* 19:77-84, 1978
3. Löfström B: Stellate ganglion block, *Illustrated Handbook in Local Anesthesia*. Edited by Eriksson E. Copenhagen, I SHR Sovensen and Company A/S, 1969, pp 137-139
4. Allen EV: Thromboangiitis obliterans: Methods of diagnosis of chronic occlusive arterial lesions distal to the wrist with illustrative cases. *Am J Med Sci* 178:237-244, 1929
5. Peters FA: A disease resulting from the use of the pneumatic tools. *Occup Med* 2:55-66, 1946