

Intranasal Administration of Nitroglycerin

ANNE B. HILL, M.B.,* C. JOHN BOWLEY, M.B.,† MICHAEL L. NAHRWOLD, M.D.,‡ PAUL R. KNIGHT, M.D., PH.D.*
M. M. KIRSH, M.D.,§ J. KENNETH DENLINGER, M.D.¶

Nitroglycerin (NTG) decreases myocardial workload and improves the distribution of coronary blood flow, thereby improving myocardial oxygen supply and relieving angina.^{1,2} NTG may be administered orally as sublingual tablets, topically as an ointment, or parenterally.^{3,4} Intravenous NTG is useful for its rapid action, but preparation, standardization and stabilization of such a solution is not without problems and can become expensive.⁵

During anesthesia, the presence of surgical drapes, an endotracheal tube, oral airway, esophageal stethoscope, and a temperature probe render topical or sublingual administration of NTG difficult. In addition, premedication with atropine or other anticholinergic may inhibit the dissolution and absorption of sublingual tablets.

Prior to this study, one of the authors (Dr. Denlinger) had occasionally administered a NTG solution intranasally. From a practical point of view, the solution could be quickly and freshly prepared by the anesthesiologist at the same time other induction agents were prepared. Clinical experience suggested that this route of administration of NTG provided a rapid onset of action with a predictable and consistent therapeutic effect. Therefore, the following study was designed to determine the pharmacokinetics of an intranasal NTG solution.

MATERIALS AND METHODS

The protocol was approved by the Committee to Review Grants for Clinical Research and Investigation

* Assistant Professor, Department of Anesthesiology, the University of Michigan Medical Center.

† Instructor, Department of Anesthesiology, the University of Michigan Medical Center.

‡ Associate Professor, Department of Anesthesiology, the University of Michigan Medical Center.

§ Professor, Department of Surgery, the University of Michigan Medical Center.

¶ Staff Anesthesiologist, Anesthesiology Associates of Lancaster, Lancaster, Pennsylvania 17601.

Received from the Department of Anesthesiology, the University of Michigan Medical Center, Ann Arbor, Michigan 48109. Accepted for publication October 31, 1980. Presented in part at the annual meeting of the American Society of Anesthesiologists, San Francisco, California, October, 1979.

Address reprint requests to Dr. Hill.

Key words: Pharmacokinetics; kinetics; intranasal. Pharmacology: nitroglycerin. Surgery: cardiac.

Involving Human Beings at the University of Michigan as regards informed consent. The NTG solution to be used was prepared by dissolving ten 0.4-mg NTG tablets in 5 ml normal saline in a glass syringe.^{6,7} Five patients undergoing elective coronary artery bypass surgery were studied. Prior to induction of anesthesia, a radial artery was cannulated with a 20-gauge catheter. A flow directional catheter (#7 Fr Swan-Ganz) was placed in the pulmonary artery via the internal jugular vein, and at least one peripheral venous catheter was placed. Anesthesia was then induced and maintained with either morphine, diazepam, nitrous oxide and oxygen, or with fentanyl and oxygen. The electrocardiogram (Leads II and V₅) and arterial and pulmonary artery pressures were continually recorded. If electrocardiographic evidence of myocardial ischemia was noted, or if pulmonary artery end-diastolic pressure increased by 5 torr, 1 ml of the NTG solution was instilled intranasally from the the glass syringe using a standard 16-gauge 2 in Teflon[®] intravenous catheter. Blood was then withdrawn simultaneously from the arterial catheter, the central venous port of the Swan-Ganz catheter, and a peripheral vein. These samples were drawn at 0.5, 1, 2, 4, 8, 16, and 32 minutes following intranasal administration of the NTG solution. Samples were drawn from the respective catheters directly into glass tubes using a Vacutainer[®] system.⁶

All samples were extracted with n-pentane and analyzed for plasma NTG levels using gas-liquid chromatography with electron capture detection.** To permit pharmacokinetic analysis of the data, we assumed that the intranasal dose of NTG was immediately distributed. Log NTG levels were plotted against time. From this relationship the plasma concentration (C_p⁰) and the half-life (T_{1/2}) were calculated. The apparent volume of distribution (AVD), and plasma clearance (Cl) were calculated according to the method of Ritschel.⁸

RESULTS

In all patients, the desired clinical effect, namely a lowering of the pulmonary artery end-diastolic pressure and/or improvement in S-T segment changes,

** Stetson PL: Personal communication.

was seen within two minutes of administration. No patient became hypotensive, tachycardic, or required therapeutic intervention to reverse the effect of NTG. NTG levels were found to be highest in central venous blood, reaching a peak at 1–2 min after administration (fig. 1). Arterial and peripheral venous levels were found to be progressively lower, peaking at 1–2 and 2 min, respectively. Blood levels fell rapidly as a monoexponential function and were barely detectable at 16 min. There were no differences between the levels observed at 16 and 32 min; therefore, the data were analyzed as an open one-compartment model. The apparent volume of distribution was large and clearance rates high at all three sites (table 1). Half-life was similar from all three sites of sampling (table 1). The decay curve could be described by the equation:

$$C_p = C_p^0 \cdot e^{-k_{el}t}$$

where C_p was the concentration of NTG (ng/ml) at time t (min), $k_{el}t$ the elimination rate constant, and C_p^0 the concentration at time zero.

DISCUSSION

Clearly, NTG is rapidly absorbed into the vascular space following intranasal instillation. The time course of absorption is similar to a bolus intravenous injection.³ The plasma levels observed in our study were higher than those observed following sublingual administration,⁹ and the half-life of 5.41 min compares favorably with the value of 4.4 min reported by Armstrong.⁹ The very high apparent volume of distribution indicates that NTG is stored or pooled or is bound to a specific biological material. Measurement of NTG levels is a difficult and time consuming process. Therefore, little is known about the bioavailability of NTG administered by different methods.^{9,10}

The intravenous administration of NTG has the advantage of a continuous infusion which can be maintained over a prolonged period but the preparation of a sterile solution is difficult and time con-

TABLE 1. Description of Decay Curves for Nitroglycerin

Site of Sampling	C_p^0	$-K_{el}$	$T_{1/2}$ (min)	r	AVD (l)	Cl (l/min)
Radial Artery	5.24	0.124	5.59	0.68*	152.7	18.9
Central Venous	6.48	0.128	5.41	0.63*	123.5	15.8
Peripheral Venous	2.56	0.119	5.82	0.60*	312.5	37.2

C_p^0 = plasma concentration (ng/ml) at time zero; $T_{1/2}$ = half life (min); $-K_{el}$ = elimination rate constant; r = correlation coefficient; AVD = apparent volume of distribution (l); Cl = clearance (l/min).

* $P < 0.05$.

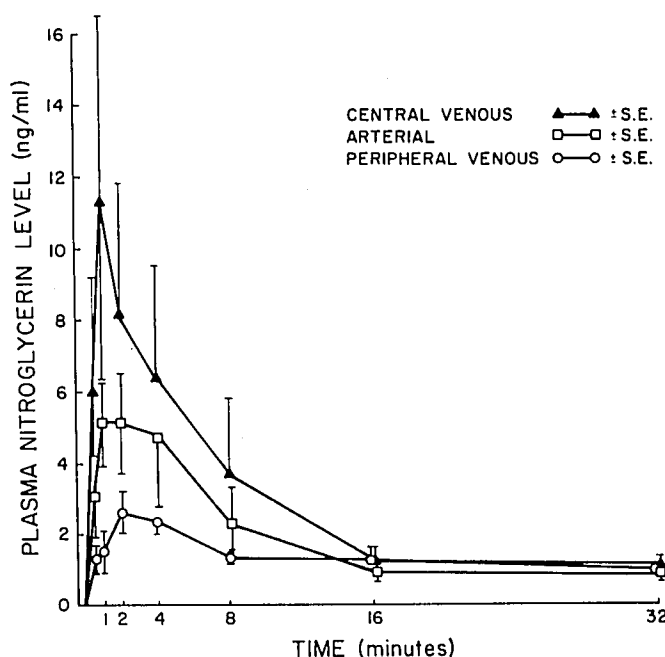


FIG. 1. Plasma levels of nitroglycerin following intranasal administration of an 0.8-mg dose.

suming. In addition, the cost of preparation of a sterile intravenous solution by our pharmacy is approximately \$20.00; whereas, the cost of preparation of a NTG solution for intranasal use is about \$0.22. Therefore, we suggest that intranasal administration of a nonsterile NTG solution is a safe, rapid, convenient, and economical alternative to intravenous administration, especially during induction of anesthesia, or if prolonged therapy is not anticipated.

The authors thank A. R. Tait, B.Sc., M. Taylor Busch, B.S., and A. A. Armstrong, B.S., for technical assistance. Nitroglycerin assays were performed by P. L. Stetson, M.D., Ph.D., at the Upjohn Center for Clinical Research, University of Michigan.

REFERENCES

- Kaplan JA, Dunbar RW, Jones EL: Nitroglycerin infusion during coronary-artery surgery. *ANESTHESIOLOGY* 45:14–21, 1976
- Chiariello M, Gold HK, Leinbach RC, et al: Comparison between the effects of nitroprusside and nitroglycerin on ischemic injury acute myocardial infarction. *Circulation* 54:766–773, 1976
- Stengert KB, Wilsey BL, Hurley EJ, et al: Incremental intravenous nitroglycerin for control of afterload during anesthesia in patient undergoing myocardial revascularization. *Anaesthetist* 27:223–227, 1978
- Taylor WR, Forrester JS, Magnusson P, et al: Hemodynamic effects of nitroglycerin ointment in congestive heart failure. *Am J Cardiol* 38:469–473, 1976
- Ward JW, Sandler AI, Tucker SV: Nitroglycerin for iv infusion. *Drug Intelligence and Clinical Pharmacology* 13: 14–15, 1979

6. Cossum PA, Galbraith AJ, Roberts MS, et al: Loss of nitroglycerin from intravenous infusion sets. *Lancet* 2:349-350, 1978
7. Sturek JK, Sokoloski TD, Winsley WT, et al: Stability of nitroglycerin injection determined by gas chromatography. *Am J Hosp Pharm* 35:537-541, 1978
8. Ritschel WA: *Handbook of Basic Pharmacokinetics*. Hamilton, Illinois, Drug Intelligence Publications, 1976, p 177
9. Armstrong PW, Armstrong JA, Marks GS: Blood levels after sublingual nitroglycerin. *Circulation* 59:585-588, 1979
10. Wei JY, Reid PR: Quantitative determination of trinitroglycerin in human plasma. *Circulation* 59:588-591, 1979

Anesthesiology
54:348-349, 1981

Cutaneous Cerebrospinal Fluid Leakage Following Attempted Extradural Block

S. R. JAWALEKAR, M.B.,* AND GERTIE F. MARX, M.D.†

Prolonged, post-lumbar puncture, cerebrospinal fluid (CSF) leakage through an arachnodural rent has been observed by radioisotope myelography,¹ by direct vision during laminectomy,² as well as during postmortem examination.³ Development of a sub-arachnoid-cutaneous fistula has also been reported after inadvertent dural penetration during extradural steroid injection in two patients who previously had lumbar laminectomies.^{4,5} In this study, we report a case of cutaneous CSF leakage following attempted lumbar extradural block in a healthy patient.

REPORT OF A CASE

A 30-year-old, female physician required emergency cesarean section because of cephalopelvic disproportion. To initiate epidural anesthesia, identification of the extradural space was attempted first at the L 2-3 and then at the L 3-4 interspace. Both were unsuccessful; there was some bleeding but no indication of a "wet" tap. A third attempt at the L 4-5 interspace led to positive identification of the extradural space, and an uneventful extradural block was achieved with 3 per cent 2-chloroprocaine, 18 ml. On the following day, the patient felt "wetness" on her back which she believed to be sweat. However, in the evening, her husband, also a physician, diagnosed cerebrospinal liquorrhea. Our advice was then sought.

Examination of the patient's back revealed three puncture marks between L 2 and L 5, the upper and lower were closed and healing, the middle had reddened borders. This mark had a distinct tract from which a clear colorless fluid exuded at a rate of approximately 6 drops/min at rest; the rate of flow increased when the patient was in the sitting position and even more so when she coughed. A sample of the fluid showed a pH of 7.3, glucose 2.5 mmol/l, two white and no red blood cells. The puncture wound was cleaned and covered with sterile gauze. The patient was then instructed to lie, with thighs flexed, on either side but *not* on her

back. A neurologic consultant advised against prophylactic antibiotic administration since temperature and white blood cell count were within normal limits. However, because of the potential for infection, an epidural blood patch was not administered.

The patient related that the "dripping" decreased notably after she abandoned the supine position. Forty-eight hours later, leakage had stopped completely, and the puncture track was almost closed. The moderate postural headache which had accompanied the leak abated at the same time.

Discussion of the extradural block technique with the anesthesiologist disclosed the following: 1) the non-healing puncture site was that of the second attempt; 2) a sharp needle had been used to pierce the skin at all three interspaces; and 3) the same Tuohy needle had been employed throughout, but had been cleared by flushing with local anesthetic between the second and third attempts only.

DISCUSSION

Subarachnoid-cutaneous fistulas have been associated with incapacitating headaches,^{1,2} and have led to the development of meningitis.⁴ Attempts to hasten closure of the fistula are therefore indicated. In one of the reported cases, surgical intervention was undertaken; two Cushing clips were applied to close the dural defect.² Another patient was treated with bed-rest in a slight Trendelenburg position to relieve CSF pressure on the rent, reduce the leakage, and thus promote spontaneous healing.¹ Brocker⁶ advocated the prone position for prevention and treatment of post-lumbar puncture headache. He proposed that "assumption of the prone position staggers the punctures in the dura and arachnoid, decreases the potential epidural space, and releases the tension of the dural and arachnoid tears; this would reduce the loss of spinal fluid."⁶ In his series of 894 patients lying on their abdomen for three hours following lumbar puncture, the incidence of postspinal headache was 0.45 per cent, whereas in 200 comparable patients kept supine after the puncture, the incidence was 36.5 per cent. Ash⁷ also reported a reduction in incidence and severity of postspinal headache when the block had been administered in the prone position. He postulated that this resulted from decreased tearing

* Assistant Professor of Anesthesiology.

† Professor of Anesthesiology.

Received from the Department of Anesthesiology, J-1226, Albert Einstein College of Medicine, 1300 Morris Park Avenue, Bronx, New York 10461. Accepted for publication October 31, 1980.

Address reprint requests to Dr. Marx.

Key words: Anesthetic techniques: epidural; lumbar. Cerebrospinal fluid: leak. Complications: cutaneous cerebrospinal fluid leakage.