

thalmologists to detect early abnormalities in the resistance to outflow of fluid from the eye is the Water Drinking Provocative Test.⁹ The test requires the patient to drink one liter of water after he has fasted four hours. Within 40–45 min of oral consumption of water, a rise in IOP occurs if outflow resistance is elevated as in glaucoma. As high as 94 per cent of patients with open angle glaucoma will have an increase in IOP and a decrease in the outflow facility of the eye, whereas only 6 per cent of normals experience such changes.⁹ A rise in IOP greater than 9 torr is pathological.¹⁰ The effects of induced ocular hypertension in responsive normal eyes and glaucomatous eyes are an enlargement of blind spots, the appearance of para central scotoma and a nasal step.¹⁰ These are pressure dependent visual field defects that vary in onset and occurrence. The absorption of large amounts of hypotonic solutions occur even more rapidly by the intravascular route in a TURP and such visual field changes could explain these visual disturbances. But none of our patients had increases in IOP large enough to be considered pathological. Thus, we agree with Defalque and Miller who felt that cerebral edema was the cause of visual disturbances.⁵

Anesthesiology
55:329–331, 1981

REFERENCES

1. Creevy CD, Webb EA: A fatal hemolytic reaction following transurethral resection of the prostate gland. *Surgery* 21: 56–66, 1947
2. Taylor RO, Maxson ES, Carter RH, et al: Volumetric, gravimetric and radioisotopic determination of fluid transfer in transurethral prostatectomy. *J Urol* 79:490–499, 1958
3. Marx GF, Orkin LR: Complications associated with transurethral surgery. *ANESTHESIOLOGY* 23:802–813, 1967
4. Ceccarelli FE, Mantell LK: Studies on fluid and electrolyte alterations during transurethral prostatectomy. *J Urol* 85: 75–82, 1961
5. Defalque RJ, Miller DW: Visual disturbances during transurethral resection of the prostate. *Can Anaesth Soc J* 22: 620–621, 1975
6. Harrison RH, Boren JS, Robison JR: Dilutional hyponatremic shock: Another concept of the transurethral prostatic resection reaction. *J Urol* 75:95–109, 1956
7. Taylor TH, Mulcahy M, Nightingale DA: Suxamethonium chloride in intraocular surgery. *Br J Anaesth* 40:113–118, 1968
8. Pandey K, Bandola RP, Kumar S: Time course of intraocular hypertension produced by suxamethonium. *Br J Anaesth* 44:191–195, 1972
9. Kolker AE, Hetherington J: *Becker-Shaffer's Diagnosis and therapy of the glaucomas*, Third edition. St. Louis, The C. V. Mosby Company, 1970, pp 78–79, 112–113
10. Bellows JG: *Glaucoma, contemporary international concepts*. New York, Masson Publishing Company, 1979, pp 129–130, 226

Hemodynamics, Plasma Histamine, and Catecholamine Concentrations during an Anaphylactoid Reaction to Morphine

NABIL R. FAHMY, M.D.*

Morphine is frequently given intravenously as the main anesthetic drug for cardiac surgery and as the narcotic component in nitrous oxide–narcotic–relaxant anesthesia because of minimal cardiovascular

effects.¹ In some patients, however, hypotension occurs usually secondary to histamine release.^{1,2} In the case report below, we describe a patient who had an anaphylactoid reaction to morphine in which changes in hemodynamic function were correlated with plasma histamine and catecholamines levels.

* Associate Professor of Anaesthesia, Harvard Medical School, Boston, Massachusetts.

Received from the Anesthesia Services of the Massachusetts General Hospital and the Department of Anaesthesia, Harvard Medical School, Boston, Massachusetts 02114.

Accepted for publication March 3, 1981. Supported in part by Grant GM 15904-14 from the National Institute of General Medical Sciences.

Address reprint requests to Dr. Nabil R. Fahmy: Department of Anesthesia, Massachusetts General Hospital, Boston, Massachusetts 02114.

Key words: Anesthetics, intravenous: morphine. Allergy: anaphylactoid reaction. Sympathetic nervous system: catecholamines. Histamine.

REPORT OF A CASE

A 45-year-old, 57-kg white woman was scheduled for a left total hip replacement. She gave no history of drug allergies and was not receiving medication prior to admission. The patient had no history or clinical evidence of cardiopulmonary disease and was enrolled in an ongoing study of intravenous narcotic drugs with her consent. She was given diazepam, 10 mg orally, 90 min prior to surgery. On arrival in the induction room, peripheral venous, arterial, and right atrial catheters were inserted under local anesthesia. Hemodynamic monitoring included measurement of heart rate, right atrial and systemic arterial blood pressures,

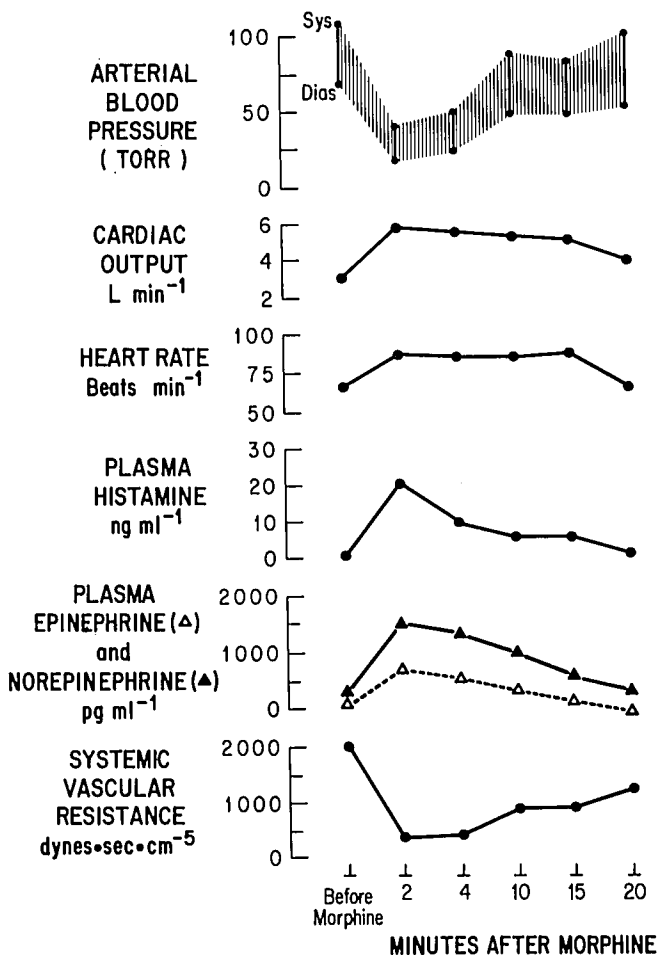


Fig. 1. Systemic hemodynamic variables and plasma histamine and catecholamines concentrations during an anaphylactoid reaction to intravenous morphine, 0.3 mg/kg.

and cardiac output while the patient was breathing 100 per cent oxygen. Arterial blood samples were drawn and the plasma was analyzed for concentrations of plasma histamine, epinephrine, norepinephrine and electrolytes. Morphine, 0.3 mg/kg, was administered intravenously at a rate of 10 mg/min. Immediately after morphine had reached the circulation, hypotension, tachycardia, and a generalized bright cutaneous flush developed (fig. 1). The patient complained of headache but never lost consciousness. Lactated Ringer's solution, 2,000 ml, was infused rapidly in an attempt to increase arterial blood pressure. No bronchoconstriction was evident clinically. The erythema disappeared after 20 min, at which time the arterial pressure and heart rate returned towards normal values. The operation proceeded, and the four-hour surgery was well tolerated. Nitrous oxide, *d*-tubocurarine (3- to 6-mg increments), and fentanyl (50- μ g increments) were employed for maintenance of anesthesia with no important cardiovascular sequelae. Recovery was uneventful.

Four weeks after the reaction, intradermal testing was carried out using small amounts (0.1 ml of 1:1000 solution) of thiopental, succinylcholine, *d*-tubocurarine, morphine, fentanyl, chlorambutal, and sodium bisulfite. The patient reacted only to morphine, with the rapid development of a wheal, 2 cm in diameter, which

persisted for about 30 min. It should be emphasized that a lack of response to intradermal testing does not indicate that the individual will not release histamine when the drug is given intravenously.

Pressures in the radial artery and right atrium were measured by Satham transducers and recorded continuously, together with lead 2 of the ECG. Heart rate was calculated from the ECG tracing. Mean arterial (MAP) and right atrial (MRAP) pressures were obtained by electrical integration. Cardiac output (CO) was determined by dye-dilution technique, with injection of 5 mg of indocyanine green (Cardio-green) into the right atrium and withdrawal from the radial artery catheter through the cardiocensitometer. Systemic vascular resistance (SVR) was calculated from the formula:

$$SVR = \frac{(MAP - MRAP) 80 \text{ dynes}\cdot\text{sec}\cdot\text{cm}^{-5}}{CO}$$

Plasma histamine levels were measured by a radioenzymatic assay that is specific and sensitive to 0.1 ng amounts.³ Intra- and interassay variations are less than 10 per cent. Plasma catecholamines concentrations were measured by the radioenzymatic method of Peuler and Johnson which is sensitive to amounts greater than 25 pg/ml.⁴ Intra- and interassay variations are within 5 per cent. IgE levels before and five hours after morphine administration were determined by radioimmunoassay using the same lot of reagents (normal 10–160 units/ml).⁵ All measurements and determinations were done in duplicate before and 2, 4, 10, 15, and 20 min after morphine administration.

The cardiovascular changes were associated with a 30-fold increase in plasma histamine concentration (fig. 1). Decreased systemic arterial blood pressure resulted from a substantial decrease in systemic vascular resistance. The increase in heart rate and stroke volume accounted for the augmented cardiac output. Plasma norepinephrine and epinephrine levels were increased. Twenty minutes after morphine administration, heart rate and plasma histamine and catecholamines concentrations had all returned towards premorphine values. IgE levels were within the normal range before (65 units/ml) and after (72 units/ml) this anaphylactoid reaction.

DISCUSSION

The patient experienced profound hypotension, tachycardia and a generalized cutaneous erythema following the intravenous administration of morphine, 0.3 mg/kg. These manifestations, together with an increased cardiac output and a decreased systemic vascular resistance, were associated with morphine-induced histamine release. Lorenz⁶ indicated that severe cardiovascular sequelae occur with plasma histamine concentrations of 6–10 ng/ml; in our patient, plasma histamine levels rose well above this value (fig. 1). The rate of administration of morphine was similar to that used clinically, 10 mg/min.¹ The preservatives in morphine sulfate (chlorambutal and sodium bisulfite) do not alter hemodynamic function;² they also did not elicit a response with intradermal testing.

Severe allergic-type reactions to opiates, which may be related to histamine release, have been reported by Birt and Nickerson.⁷ Histamine increases both the

rate and force of myocardial contraction as well as cardiac output.⁸ Histamine can produce indirect effects by releasing catecholamines from the adrenal medulla,⁹ sympathetic nerve endings,¹⁰ and the myocardium.¹¹ Our data indicate that the anaphylactoid reaction to morphine was associated with both histamine release and sympathoadrenal stimulation. The persistent decrease in arterial blood pressure and systemic vascular resistance suggest that massive sympathoadrenal discharge could not fully overcome the powerful vasodilator effect of histamine. The augmented cardiac output was primarily the result of an increase in both heart rate and stroke volume which, in turn, were probably a reflection of the synergistic effects of histamine and catecholamines on the heart.

An immune-mediated (Type I) hypersensitivity reaction is an unlikely mechanism for this response to morphine because 1) the patient had no previous exposure to morphine or related compounds, and 2) plasma IgE levels were not elevated. IgE is the reaginic antibody present in increased amounts in individuals with immune-mediated (Type I) anaphylactic reaction. Massive release of histamine in this patient was probably due to a direct pharmacological effect of morphine.¹² An alternative mechanism to explain histamine release is direct activation (alternate pathway) of complement C3. Adverse reactions to Althesin generally involve excessive activation of complement C3, leading to histamine release, and are not reagin-antibody mediated.¹³ Complement-mediated reactions can occur on first exposure without previous sensitization.¹³

In conclusion, some of the hemodynamic sequelae of an anaphylactoid reaction to morphine are described. Such a reaction was associated with massive histamine release and sympathoadrenal discharge. Since the effects of histamine are mediated via activation of H₁ and H₂ receptors, it seems logical that the prior administration of both H₁ (*e.g.*, diphenhydramine) and H₂ (*e.g.*, cimetidine) blockers would attenuate the effects of endogenously released histamine. Such a practice may be useful in situations where use of large doses of morphine is contemplated.¹⁴

The author acknowledges the technical assistance of Mr. Bruce Fish and Mr. John Butler.

REFERENCES

1. Stoelting RK, Gibbs PS: Hemodynamic effects of morphine and morphine-nitrous oxide in valvular heart disease and coronary artery disease. *ANESTHESIOLOGY* 38:45-52, 1973
2. Hsu HO, Hickey RF, Forbes AR: Morphine decreases peripheral vascular resistance and increases capacitance in man. *ANESTHESIOLOGY* 50:98-102, 1979
3. Shaff RE, Beaven MA: Increased sensitivity of the enzymatic isotopic assay of histamine: Measurement of histamine in plasma and serum. *Anal Biochem* 94:425-430, 1979
4. Peuler JD, Johnson GA: Simultaneous single isotope radio-enzymatic assay of plasma norepinephrine, epinephrine and dopamine. *Life Sci* 21:625-636, 1977
5. Spitz E, Gelfand EW, Sheffer AL, et al: Serum IgE in clinical immunology and allergy. *J Allergy Clin Immunol* 49: 337-347, 1972
6. Lorenz W, Doenicke A, Meyer R, et al: Histamine release in man by propanidid and thiopentone: Pharmacological effects and clinical consequences. *Br J Anaesth* 44:355-369, 1972
7. Birt AR, Nickerson M: Generalized flushing of the skin with urticaria pigmentosa. *Arch Dermatol* 80:311-317, 1959
8. Lorenz W, Doenicke A: Histamine release in clinical conditions. *Mt Sinai J Med* 45:357-386, 1978
9. Staszewska-Barczak J, Vane JR: The release of catecholamines from the adrenal medulla by histamine. *Br J Pharmacol* 25: 728-742, 1965
10. Euler US von: Relationship between histamine and the autonomic nervous system, Histamine: Its chemistry, metabolism and physiological and pharmacological actions. Edited by Rocha e Silva M. *Handbuch der Experimentellen Pharmakologie*. Vol 18, Pt 1. Berlin, Springer-Verlag, 1966, pp 318-333
11. Altura BM, Halevy S: Cardiovascular actions of histamine, Histamine H₁ and anti-histaminics: Chemistry, metabolism and physiological and pharmacological actions. Edited by Rocha e Silva M. *Handbuch der Experimentellen Pharmakologie*, Vol 18 Pt 2. Berlin, Springer-Verlag, 1978, pp 1-39
12. Paton WDM: Histamine release by compounds of simple chemical structure. *Pharmacol Rev* 9:269-328, 1959
13. Watkins J: Anaphylactoid reactions to I.V. substances *Br J Anaesth* 51:51-60, 1979
14. Philbin DM, Moss J, Akins C, et al: The use of H₁ and H₂ histamine antagonists with morphine anesthesia: A double blind study. *ANESTHESIOLOGY* 55:292-296, 1981