

- back pressure, intraoperative shunting, ulcerated atheromata, and the incidence of stroke during carotid endarterectomy. *Surgery* 83:306-312, 1978
11. Jasper HH: The ten twenty electrode system of the International Federation. *Electroencephal Clin Neurophysiol* 10:371-375, 1958
  12. Sanderson AC, Segen J, Richey E: Hierarchical modeling of EEG signals. *IEEE Transactions on Pattern Analysis and Machine Intelligence PAMI* 2:405-415, 1980
  13. Gibbs FA, Gibbs EL, Lennox WG: Effect on the electroencephalogram of certain drugs which influence nervous activity. *Arch Int Med* 60:154-166, 1937
  14. Smith NT: Monitoring the electroencephalogram in the operating room, *Monitoring Surgical Patients in the Operating Room*. Edited by Gravenstein JS, Newbower RS, Ream AK, et al Springfield, Charles C Thomas, 1979, pp 119-141
  15. Levy WJ, Shapiro HM, Maruchak G, et al: Automated EEG processing for intraoperative monitoring: A comparison of techniques. *ANESTHESIOLOGY* 53:223-236, 1980
  16. Heros RC, Nelson PB: Intracerebral hemorrhage after microsurgical cerebral revascularization. *Neurosurgery* 6:371-375, 1980

## APPENDIX

*Off-line Methods of EEG Signal Analysis*

These methods, not yet available for real time use in the operating room can be developed for on-line monitoring if they prove clinically useful.

*Method 1.* Hierarchical modeling and pattern analysis by the method of Sanderson.<sup>12</sup>

This technique is based on an autoregressive method of analysis. It recognizes specific power spectral patterns and formulates models for each of these patterns (fig. 1A). Once models have been constructed for a particular EEG record, the com-

puter tracks the EEG signal and detects each change in pattern. A sequence of time segmented power spectral models is shown for each five-minute epoch of EEG (fig. 1B). The sequence of model segments for two symmetrical EEG channels is then depicted graphically (fig. 1C) to show pattern changes that might not otherwise be apparent. Sanderson's method may be more sensitive to subtle changes in EEG than other available methods of analysis because it adapts to time-varying EEG patterns.

*Method 2.* Power and frequency ratios in specific frequency bands.

The power spectral analysis performed on-line by the Nicolet MED 80 prints numerical power and frequency data as well as plotting the compressed spectral array. Ratios of the values from symmetrical channels on either side of the head are plotted to make subtle EEG asymmetries apparent. Numerical values for total power and predominant frequency in each of four specific frequency bands (theta, 4-8 Hertz; alpha, 8-13 Hertz; beta, 13-25 Hertz; and theta plus alpha, 4-13 Hertz) are compared by dividing values obtained from the EEG channel ipsilateral to the side of operation (C3-P3) by values obtained from the symmetrical contralateral EEG channel (C4-P4). Figure 2A shows numerical values for relative alpha power in each of these channels plotted against time. Figure 2B shows the derived ratios for alpha power and frequency.

*Method 3.* Power and frequency ratios derived from Cerebral Function Monitors.

Ratios are derived from digital values displayed on the two CFM 870® monitors by dividing values for the EEG channel ipsilateral to the side of operation (C3-P3) by values from the symmetrical contralateral channel (C4-P4).

Anesthesiology  
55:466-469, 1981.

## Coronary Artery Spasm during General Anesthesia

CHARLES W. BUFFINGTON M.D.,\* AND TOM D. IVEY, M. D.\*

Coronary artery spasm abruptly reduces coronary blood flow and oxygen delivery to the myocardium. The systemic hemodynamic pattern associated with this condition differs from that associated with effort-induced ischemia. Myocardial ischemia caused by coronary spasm occurs suddenly and without provocative increases in

blood pressure or heart rate. Often recurrent, the episodes of ischemia are brief and paroxysmal in nature. Spontaneous, rapid resolution of ischemia may be accompanied by an overshoot in blood pressure and heart rate. Recognition of this pattern allows correct diagnosis and successful treatment. This is a report of coronary vasospasm during general anesthesia.

\* Assistant Professor.

Received from the Departments of Anesthesiology and Surgery, University of Washington, Seattle, Washington. Accepted for publication March 20, 1981. Dr. Buffington is supported by Clinical Investigator Award HL 00695 from the National Heart, Lung and Blood Institute.

Address reprint requests to Dr. Buffington: University of Washington School of Medicine, Department of Anesthesiology, RN-10, Seattle, Washington 98195.

Key Words: Heart: coronary artery spasm. Surgery: cardiac.

## REPORT OF A CASE

A 55-year-old white man presented for coronary bypass surgery with a six-month history of angina pectoris. The pain occurred primarily during exertion but occasionally occurred at rest. He was selected for surgery because his angina was refractory to medical management with 60 mg propranolol, four times daily, 20 mg isosorbide dinitrate, every four hours, and sublingual nitroglycerin as needed. Coronary arteri-

ography demonstrated stenoses which reduced the diameter of the left anterior descending artery by 95 per cent, the second obtuse marginal branch of the circumflex artery by 80 per cent, and the distal right coronary artery by 100 per cent. A ventriculogram showed hypokinesis of the inferior and posterior left ventricular wall, and an ejection fraction of 0.37 (normal  $0.67 \pm 0.08$ ) was computed. The electrocardiogram indicated an old, inferior wall myocardial infarction. An exercise tolerance test was not performed. The history and physical examination failed to reveal signs or symptoms of congestive heart failure, and no other medical problems were identified.

Following medication with 12 mg morphine sulfate, sc, intravenous and intra-arterial catheters were inserted and electrocardiographic leads attached. Arterial and venous pressures were transduced by calibrated strain gauges. The amplified pressure signals and electrocardiogram were displayed on an oscilloscope and recorded.

Anesthesia was induced over a 10 min period with intravenous morphine sulfate (50 mg) and diazepam (17.5 mg) while the patient breathed 100 per cent oxygen. Following loss of consciousness, pancuronium (8 mg, iv) was administered, and the trachea was intubated. Anesthesia was maintained with halothane in oxygen. Ventilation was controlled to maintain  $P_{aCO_2}$  between 35 and 44 torr. The tip of a Swan-Ganz catheter was inserted into the pulmonary artery via the right internal jugular vein. Pulmonary artery pressure of 20/8 torr and a balloon-occluded pulmonary artery pressure of 6-8 torr were noted. Heart rate gradually increased from 50 to 85 beats/min during the period following induction but small doses of propranolol (total 3 mg, iv) resulted in a gradual slowing to 60-65 beats/min.

While the legs were elevated so that an antiseptic solution could be applied, we noted a sudden, progressive depression of the S-T segment of the V5 electrocardiogram. Simultaneously, pulmonary artery pressure rapidly increased from 20/6 to 35/15 torr. These changes resolved abruptly, without treatment, three minutes later. Because this episode of myocardial ischemia and acute left ventricular failure seemed atypical, we sought to identify the cause. No rise in heart rate or arterial

pressure preceded the event, and the rate-pressure product was 40 per cent lower than during induction of anesthesia. These facts argued against increased myocardial oxygen demand as the cause. Because the hematocrit was 40 per cent and unchanged following induction of anesthesia, and the arterial oxygen tension was greater than 200 torr, a decrease in arterial oxygen content could be excluded. We were suspicious that leg elevation had increased the return of venous blood and precipitated acute left ventricular failure. Rapid intravenous infusion of 500 ml of a balanced salt solution increased pulmonary artery diastolic pressure from 8 to 14 torr but failed to produce S-T segment depression. We thought low coronary perfusion pressure might have reduced myocardial oxygen delivery, but halothane, 2 per cent inspired, administered until mean arterial pressure decreased from 90-95 to 75-78 torr resulted in no signs of ischemia. Papillary muscle dysfunction resulting in acute mitral valve regurgitation could have produced the observed elevation of pulmonary artery pressure. However, the phasic, balloon-occluded pulmonary artery pressure trace showed no "V" waves during an episode of ischemia.

These considerations ruled out the more conventional causes of myocardial ischemia, and a tentative diagnosis of coronary artery spasm was made. Four similar episodes occurred before a nitroglycerin solution was available. One of these episodes is presented in figure 1. No episodes occurred while nitroglycerin was administered intravenously at a rate of  $0.25 \mu\text{g}\cdot\text{kg}^{-1}\cdot\text{min}^{-1}$  for 55 min but two further episodes occurred after nitroglycerin was stopped.

Five aorto-coronary bypass grafts were installed without incident. The postoperative period was complicated by systemic hypertension requiring nitroprusside and ventricular extrasystoles requiring lidocaine. On the first postoperative day, a supraventricular tachycardia with ventricular response of 140-160 beats/min developed and was treated with digoxin and propranolol. The myocardial component of serum creatine phosphokinase was slightly elevated on the first postoperative day (13 units/l compared to normal 0-6 units/l), a finding consistent with mild myocardial tissue damage.

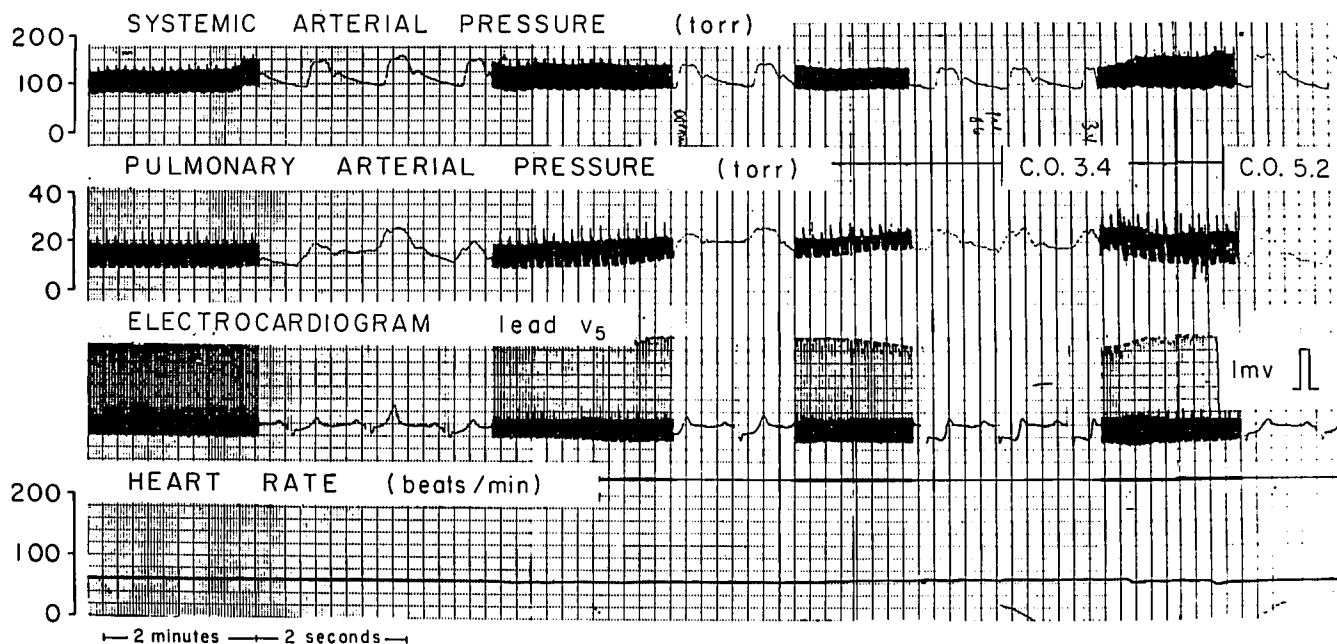


FIG. 1. Episode of myocardial ischemia. The abrupt appearance of S-T segment depression in electrocardiographic lead V5 is accompanied by evidence of acute left ventricular failure: reduced arterial pressure and increased pulmonary artery pressure. These changes are rapidly reversed and cardiac output rises during the spontaneous resolution of ischemia.

## DISCUSSION

The episodes of myocardial ischemia observed during general anesthesia in this patient were probably caused by coronary artery spasm. Although proof that spasm was the proximate cause would require arteriographic demonstration of reversible coronary obstruction, the hemodynamic and electrocardiographic evidence suggests spasm. The lack of antecedent rise in heart rate or systolic blood pressure, the elevation of pulmonary artery pressure, and the paroxysmal nature of the episodes all support the diagnosis. A similar hemodynamic and electrocardiographic pattern occurs during spasm in patients with variant angina.<sup>1</sup> These patterns differ from those observed during classic, effort-induced angina. The differences aid recognition of coronary spasm during anesthesia, an essential aspect of proper management.

Effort-induced myocardial ischemia in patients with fixed coronary stenoses results when myocardial oxygen demand is increased by an increase in blood pressure, heart rate, or contractility. Oxygen delivery through the stenotic vessel fails to meet this augmented demand, and tissue hypoxia results.<sup>2</sup> In contrast, coronary vasospasm partially or totally reduces blood flow and oxygen delivery to the section of myocardium served by the affected vessel.<sup>3-5</sup> Although an increase in heart rate or blood pressure precedes and causes effort-induced myocardial ischemia, no such hemodynamic changes foreshadow ischemia caused by coronary spasm. Instead, the onset of spasm-induced ischemia is sudden and without warning.<sup>6,7</sup> S-T segment changes and evidence of acute left ventricular failure occur simultaneously and develop rapidly.<sup>1,8-11</sup> Systemic arterial pressure and cardiac output fall, and left ventricular end-diastolic pressure increases. The average time from onset to maximum change is 35-45 s, and most episodes resolve within 2-5 min.<sup>9</sup> The resolution phase is characterized by rapid return of S-T segments to baseline and recovery of left ventricular function. Hypertension and an increase in heart rate frequently occur during this recovery period and may represent sympathetic compensation for the hemodynamic impairment caused by myocardial ischemia.<sup>7</sup>

During spasm, the electrocardiogram demonstrates S-T segment elevation in the leads monitoring the affected myocardium if ischemia is transmural; however, if vessel occlusion is incomplete or sufficient collateral flow exists, ischemia may be limited to the more vulnerable subendocardium, and S-T segment depression results.<sup>7,12</sup>

The only clue that coronary spasm might occur in this patient was the history of chest pain at rest.<sup>13</sup> Chest pain at rest with preserved exercise capacity is characteristic of variant angina.<sup>14</sup> The diagnosis of spasm was obscured in this case, however, because of coexisting severe arteriosclerosis which limited exercise capacity and led to

exertional angina. That coronary spasm can occur in patients with no, moderate, or severe coronary stenosis has been demonstrated.<sup>9,10</sup>

Anesthetic management of a patient with proven coronary spasm should include ready access to nitroglycerin. The response of our patient to intravenous nitroglycerin was dramatic. The efficacy of nitrates in preventing or aborting attacks of variant angina has been recognized since Prinzmetal's first report,<sup>6</sup> and continuous nitrate infusion has been used in the management of vasospastic angina.<sup>15</sup> A nitroglycerin solution, administered intravenously at a rate of 0.25-1.0  $\mu\text{g}\cdot\text{kg}^{-1}\cdot\text{min}^{-1}$  should decrease the likelihood of spasm.<sup>16</sup> The dose of nitroglycerin should be adjusted to avoid arterial hypotension in patients with severe stenoses. Although the prophylactic use of nitroglycerin in patients with coronary spasm seems cogent in light of the high incidence of ventricular arrhythmias and acute ventricular failure during attacks, this hypothesis has not been tested during general anesthesia. Hypotension accompanying myocardial ischemia would normally suggest cautious administration of a vasodilator drug such as nitroglycerin, yet aggressive therapy may be required in cases of ischemia caused by coronary spasm. Sodium nitroprusside, a drug which might also be used to treat myocardial ischemia accompanied by elevated ventricular filling pressures, has not been tested in the treatment of coronary spasm.

Several investigational drugs promise to control coronary spasm. Nefepidine and verapamil are coronary vasodilators which act by antagonizing the uptake of calcium into vascular smooth muscle cells. Without calcium ions, these cells relax. These calcium channel blocking drugs have decreased the frequency of variant angina attacks in several clinical trials.<sup>17-19</sup>

In summary, we have described a patient undergoing surgery and general anesthesia who had multiple episodes of myocardial ischemia most likely caused by coronary artery spasm. The lack of an antecedent rise in blood pressure or heart rate, the accompanying left ventricular failure, and the paroxysmal course are similar to the hemodynamic pattern observed in patients with proven coronary spasm. The dramatic response of our patient to intravenous nitroglycerin underscores this drug's usefulness in preventing coronary spasm during general anesthesia.

## REFERENCES

1. Gaasch WH, Adyanthaya AV, Wang VH, et al: Prinzmetal's variant angina: hemodynamic and angiographic observations during pain. *Am J Cardiol* 35:683-690, 1975
2. Epstein SE, Redwood DR, Goldstein RE, et al: Angina pectoris: pathophysiology, evaluation, and treatment. *Ann Int Med* 75:263-296, 1971
3. Berman ND, McLaughlin PR, Huckell VF, et al: Prinzmetal's angina with coronary artery spasm. *Angiographic, pharmaco-*

- logic, metabolic and radionuclide perfusion studies. *Am J Med* 60:727-732, 1976
4. Chierchia S, Brunelli C, Simonetti I, et al: Sequence of events in angina at rest: primary reduction in coronary flow. *Circulation* 61:759-768, 1980
  5. Ricci DR, Orlick AE, Doherty PW, et al: Reduction of coronary blood flow during coronary artery spasm occurring spontaneously and after provocation by ergonovine maleate. *Circulation* 57:392-395, 1978
  6. Prinzmetal M, Kennamer R, Merliss R, et al: Angina pectoris I. A variant form of angina pectoris. *Am J Med* 27:375-388, 1959
  7. Guazzi M, Polese A, Fiorentini C, et al: Left and right heart haemodynamics during spontaneous angina pectoris. Comparison between angina with ST segment depression and angina with ST segment elevation. *Br Heart J* 37:401-413, 1975
  8. Maseri A, Mimmo R, Chierchia S, et al: Coronary artery spasm as a cause of acute myocardial ischemia in man. *Chest* 68:625-633, 1975
  9. Maseri A, Severi S, de Nes M, et al: "Variant" angina: one aspect of a continuous spectrum of vasospastic myocardial ischemia. *Am J Cardiol* 42:1019-1035, 1978
  10. Wiener L, Kasparian H, Duca PR, et al: Spectrum of coronary arterial spasm. Clinical, angiographic and myocardial metabolic experience in 29 cases. *Am J Cardiol* 38:945-955, 1976
  11. Chierchia S, Marchesi C, Maseri A: Evidence of angina not caused by increased myocardial metabolic demand and patterns of electrocardiographic and hemodynamic alterations during "primary" angina, Primary and Secondary Angina Pectoris. Edited by Maseri A, Klassen GA, Lesch M. New York, Grune and Stratton, 1978, pp 145-156
  12. Luchi R J, Chahine RA, Raizner AE: Coronary artery spasm. *Ann Intern Med* 91:441-449, 1979
  13. Hillis LD, Braunwald E: Coronary-artery spasm. *New Engl J Med* 299:695-702, 1978
  14. MacAlpin RN, Kattus AA, Alvaro AB: Angina pectoris at rest with preservation of exercise capacity. Prinzmetal's variant angina. *Circulation* 47:946-958, 1973
  15. Distanto A, Maseri A, Severi S, et al: Management of vasospastic angina at rest with continuous infusion of isosorbide dinitrate. *Am J Cardiol* 44:533-539, 1979
  16. Waller JL, Kaplan JA, Jones EL, et al.: Anesthesia for coronary revascularization, Cardiac Anesthesia. Edited by Kaplan JA. New York, Grune and Stratton, 1979, pp 241-280
  17. Antman E, Muller J, Goldberg S, et al: Nifedipine therapy for coronary-artery spasm. Experience in 127 patients. *New Engl J Med* 302:1269-1273, 1980
  18. Previtelli M, Salerno JA, Tavazzi L, et al: Treatment of angina at rest with nifedipine: a short-term controlled study. *Am J Cardiol* 45:825-830, 1980
  19. Solberg LE, Nissen RG, Vlietstra RE, et al: Prinzmetal's variant angina—response to verapamil. *Mayo Clin Proc* 53:256-259, 1978

Anesthesiology  
55:469-470, 1981

## The Value of Fluoroscopy before Performing a Phrenic Nerve Block

HONORIO T. BENZON, M.D.,\* YALAMANCHILI S. PRASAD, M.D.,† DAVID A. BARTHWELL, M.D.‡

Phrenic nerve blocks with local anesthetics have been used to terminate hiccups after medical management has failed, but the need for fluoroscopy before this procedure has not been stressed. This case report illustrates the value of fluoroscopy.

### REPORT OF A CASE

A 73-year-old male physician with unresectable Class IV adenocarcinoma of the right lung had been treated with external radiation to the mediastinum and to the tumor in the right lower lobe. He also had coronary heart disease an angina pectoris that was treated with 10 mg propranolol, orally four times a day. He was hospitalized for severe back pain with radiation to his right leg. Tomograms showed

bony destruction to the anterior and lateral margins of the body of the fourth lumbar vertebra on the right side, compatible with metastatic disease. Radiation treatments were administered to the lumbar spine. Two metastatic lesions were identified on tomography of the head, one in the right posterior fosa and the other at the left posterior frontal region. Medications included dilaudid and dexamethasone, orally, and morphine, intramuscularly. He developed hiccups, eructation, and abdominal distention. Dexamethasone was gradually decreased and finally discontinued. Chlorpromazine, 100 mg, im, was followed by 25 mg orally every 4 hours but failed to relieve the hiccups. Simethicone, cimetidine, magnesium and aluminum hydroxide suspension and carbamazepine were also ineffective. The frequency of hiccups increased to as often as four per minute. On the eighth day, a phrenic nerve block was requested. Fluoroscopy of the patient's diaphragm was performed before the block was attempted. The left hemidiaphragm was hyperactive but the right side did not move on its own. With normal inspiration, between hiccups, the left hemidiaphragm descended 1-2 interspaces. The right hemidiaphragm followed passively. The stomach was very dilated and the fundus was in contact with the undersurface of the left hemidiaphragm. A phrenic nerve block was not done. A nasogastric tube insertion was attempted to reduce the gastric distention but this was unsuccessful. The patient subsequently refused most of his narcotic medication. Abdominal cramps and constipation of which he had complained since hospital admission subsided and his hiccups became infrequent and finally terminated five days after narcotics were discontinued.

\* Assistant Professor of Clinical Anesthesia.

† Fellow, Pain Clinic.

‡ Resident.

Received from the Department of Anesthesia, Northwestern University Medical School, 303 East Chicago Avenue, Chicago, Illinois 60611. Accepted for publication April 17, 1981.

Address reprint requests to Dr. Benzon.

Key words: Complications: hiccups. Anesthetic techniques, regional: phrenic nerve. Monitoring: fluoroscopy.