

10. Terrill JB, Montgomery RR, Reinhardt CF: Toxic gases from fires. *Science* 200:1343-1347, 1978
11. Nieman CF, Clark WR, Wax SD, et al: The effects of smoke inhalation on pulmonary surfactant. *Ann Surg* 191:171-181, 1980

12. Zawacki BE, Jung RC, Joyce J, et al: Smoke burns and the national history of inhalation injury in fire victims: A correlation of experimental and clinical data. *Ann Surg* 185:100-110, 1977
13. Stephenson SF, Esrig BC, Polk HC, et al: The pathophysiology of smoke inhalation injury. *Ann Surg* 182:652-660, 1975

Anesthesiology  
55:585-586, 1981

## The Failure of Nasal Plethysmography to Estimate Cerebral Blood Flow during Carotid Occlusion

ROY F. CUCCHIARA, M.D.,\* AND JOSEPH M. MESSICK, M.D.\*

There are several ways of monitoring the adequacy of cerebral blood flow during carotid endarterectomy. The electroencephalogram (EEG) is the standard functional monitor of cerebral ischemia. Various computerized EEG signals (*e.g.*, compressed spectral array) and filtered EEG signals (*e.g.*, cerebral function monitor) have been developed. Measurements of cerebral blood flow (CBF) directly with radioactive tracers (*e.g.*, xenon) or by inference via pressure (*e.g.*, stump pressure measurements) have also been used to detect the occurrence of cerebral ischemia during carotid artery occlusion for endarterectomy. The anterior ethmoidal artery is a distal branch of the internal carotid artery and emerges into the nose high along the septum. By measuring pulsations of the ipsilateral anterior ethmoidal artery during carotid occlusion, CBF to the affected hemisphere can be estimated by whatever collateral circulation might be present.<sup>1,2</sup> This work examines the effectiveness for the light-emitting-diode nasal plethysmograph† as a method of estimating CBF during carotid artery occlusion.

### METHOD

Nineteen patients undergoing carotid endarterectomy with EEG monitoring and CBF determinations by <sup>133</sup>Xe washout were studied. This study was approved by our local Committee on Human Research. The nasal probe was covered with its disposable plastic condom and in-

serted high along the nasal septum until a clear large pulse wave could be recorded with a Gould® 2400 pen recorder.

Pulse height was continuously recorded before carotid occlusion, during occlusion of the external carotid, during occlusion of both external and internal carotid, and after restoration of flow in both vessels. Pulse height with the external carotid artery occluded was used as a control value, and the pulse height during internal carotid occlusion was used to calculate per cent change in pulse height. Simultaneous CBF measurements were made in these two circumstances. Normocarbica was maintained and anesthetic circumstances (enflurane/N<sub>2</sub>O/pancuronium) were in a steady state during the measurements.

### RESULTS

The change in pulse height is compared to CBF in figure 1. There is no close correlation between the two. Furthermore, the patients who exhibited critically low CBF (<18 ml/100 g/min) and EEG changes during carotid occlusion could not be identified by a characteristic change in the nasal plethysmograph. Thus, the nasal plethysmograph failed to estimate reductions in CBF and failed to help identify patients with critically low CBF producing EEG changes of ischemia.

The only technical problem encountered with the device was the occurrence of epistaxis in five patients probably due to the systemic heparinization associated with this surgical procedure rather than the device or its placement.

### DISCUSSION

Otorhinolaryngologists and anatomists have long appreciated the rich anastomatic vasculature of the nasal mucosa. Attempts to reduce the difficulty and increase the success rate for surgical treatment of severe arterial epistaxis have been the subject of many papers.<sup>3</sup> We

\* Associate Professor, Mayo Medical School and Mayo Clinic.

Received from the Department of Anesthesiology, Mayo Medical School and Mayo Clinic, Rochester, Minnesota 55901. Accepted for publication May 1, 1981.

Address reprint requests to Dr. Roy F. Cucchiara: Department of Anesthesiology, Mayo Clinic, 200 First Street SW, Rochester, Minnesota 55901.

Key words: Monitoring: nasal plethysmography. Brain: blood flow, oxygenation. Surgery: endarterectomy, carotid.

† Biotronex Laboratory, 4225 Howard Avenue, Kensington, Maryland 20795.

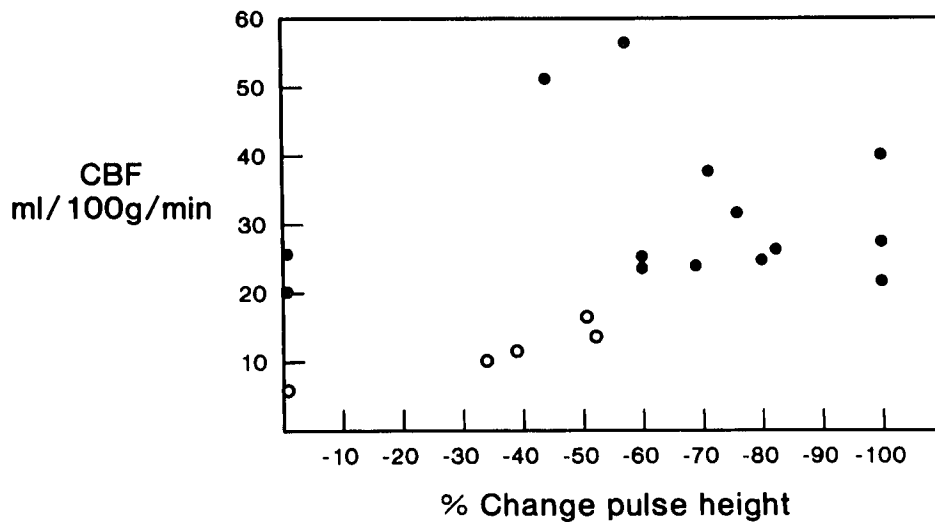


FIG. 1. There is poor correlation between per cent change in pulse height and cerebral blood flow. Open circles represent patients in whom CBF was  $\leq 18$  ml/100 g/min and in whom EEG signs of ischemia developed before a shunt could be placed. Note one patient who had no change in pulse height with a reduction in CBF sufficient to produce EEG signs of cerebral ischemia.

believe it is this rich arterial anastomotic network of the face and nose which is responsible for the lack of correlation between pulse height in the anterior ethmoidal artery distribution and CBF. Measuring pulse height in the anterior ethmoidal distribution by this nasal plethysmograph yielded no data which were clinically useful in monitoring cerebral ischemia during carotid endarterectomy.

#### REFERENCES

1. Albert SN, Kim C, Gargour G, et al: Abstracts of Scientific Papers, annual meeting of the American Society of Anesthesiologists, 1977, pp. 383-384
2. Groveman J, Cohen DD, Dillon JG: Rhinoplethysmography: Pulse monitoring at the nasal septum. *Anesth Analg (Cleve)* 45:63-68, 1966
3. Pearson BW, MacKenzie RG, Goodman WS: The anatomical basis of transantral ligation of the maxillary artery in severe epistaxis. *Laryngoscope* 79:969-984, 1969

Anesthesiology  
55:586-589, 1981

## Perioperative Anesthetic Management of a Patient with Long Q-T Syndrome (LQTS)

MORRIS BROWN, M.D.,\* RICHARD R. LIBERTHSON, M.D.,† HASSAN H. ALI, M.D.,‡  
EDWARD LOWENSTEIN, M.D.§

Hereditary prolongation of the Q-T interval associated with ventricular tachyarrhythmia and sudden death has

been recognized for about 25 years.<sup>1-13</sup> It is often familial,<sup>5</sup> occurs both with<sup>1</sup> or without congenital neural deafness,<sup>2,3</sup> and often is associated with a family history of syncope and sudden death secondary to ventricular tachyarrhythmia.<sup>5</sup> Only one description of the anesthetic management of these patients has been published.<sup>7</sup> In the present communication we describe the intra- and perioperative management of a patient with LQTS undergoing suction dilatation and curettage and laparoscopic tubal ligation, review the related literature,<sup>1-13</sup> and present our current management guidelines.

\* Senior Resident in Anesthesia, Massachusetts General Hospital.

† Assistant Physician in Medicine and Associate Pediatrician, Massachusetts General Hospital; Assistant Professor in Pediatrics and Medicine, Harvard Medical School.

‡ Associate Professor of Anesthesia, Harvard Medical School; Associate Anesthetist, Massachusetts General Hospital.

§ Anesthetist, Massachusetts General Hospital; Professor of Anesthesia, Harvard Medical School.

Received from the Department of Anesthesia and Cardiac Anesthesia Group, Massachusetts General Hospital, the Anesthesia Laboratory of the Harvard Medical School at the Massachusetts General Hospital, and the Departments of Medicine and Pediatrics, Massachusetts General Hospital and Harvard Medical School, Boston, Massachusetts 02114. Accepted for publication May 11, 1981.

Address reprint requests to Dr. Lowenstein: Department of Anesthesia, Massachusetts General Hospital, Boston, Massachusetts 02114.

Key Words: Heart: electrocardiography, long Q-T syndrome. Anesthesia: obstetric.