

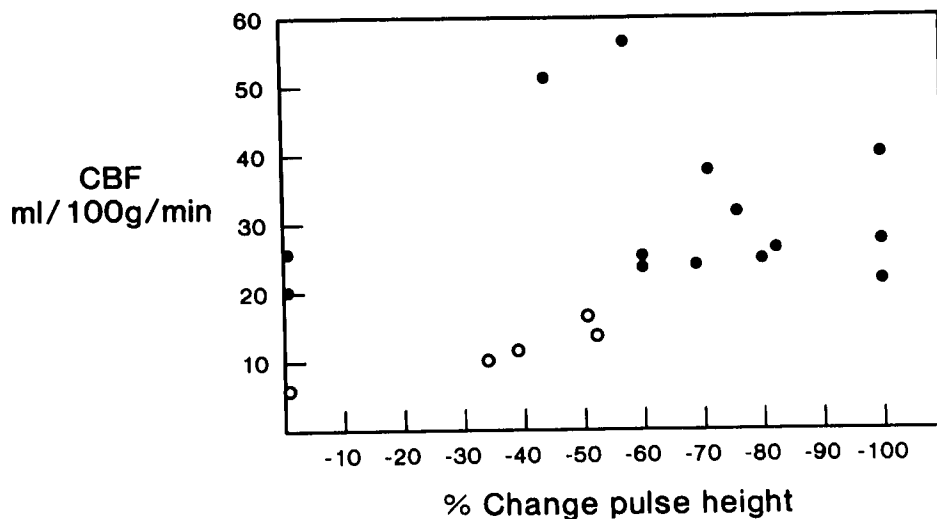FIG. 1. There is poor correlation between per cent change in pulse height and cerebral blood flow. Open circles represent patients in whom CBF was ≤ 18 ml/100 g/min and in whom EEG signs of ischemia developed before a shunt could be placed. Note one patient who had no change in pulse height with a reduction in CBF sufficient to produce EEG signs of cerebral ischemia.

believe it is this rich arterial anastomotic network of the face and nose which is responsible for the lack of correlation between pulse height in the anterior ethmoidal artery distribution and CBF. Measuring pulse height in the anterior ethmoidal distribution by this nasal plethysmograph yielded no data which were clinically useful in monitoring cerebral ischemia during carotid endarterectomy.

Anesthesiology
55:586-589, 1981

REFERENCES

1. Albert SN, Kim C, Gargour G, et al: Abstracts of Scientific Papers, annual meeting of the American Society of Anesthesiologists, 1977, pp. 383-384
2. Groveman J, Cohen DD, Dillon JG: Rhinoplethysmography: Pulse monitoring at the nasal septum. *Anesth Analg (Cleve)* 45:63-68, 1966
3. Pearson BW, MacKenzie RG, Goodman WS: The anatomical basis of transantral ligation of the maxillary artery in severe epistaxis. *Laryngoscope* 79:969-984, 1969

Perioperative Anesthetic Management of a Patient with Long Q-T Syndrome (LQTS)

MORRIS BROWN, M.D.,* RICHARD R. LIBERTHSON, M.D.,† HASSAN H. ALI, M.D.,‡
EDWARD LOWENSTEIN, M.D.§

Hereditary prolongation of the Q-T interval associated with ventricular tachyarrhythmia and sudden death has

been recognized for about 25 years.¹⁻¹³ It is often familial,⁵ occurs both with¹ or without congenital neural deafness,^{2,3} and often is associated with a family history of syncope and sudden death secondary to ventricular tachyarrhythmia.⁵ Only one description of the anesthetic management of these patients has been published.⁷ In the present communication we describe the intra- and perioperative management of a patient with LQTS undergoing suction dilatation and curettage and laparoscopic tubal ligation, review the related literature,¹⁻¹³ and present our current management guidelines.

* Senior Resident in Anesthesia, Massachusetts General Hospital.

† Assistant Physician in Medicine and Associate Pediatrician, Massachusetts General Hospital; Assistant Professor in Pediatrics and Medicine, Harvard Medical School.

‡ Associate Professor of Anesthesia, Harvard Medical School; Associate Anesthetist, Massachusetts General Hospital.

§ Anesthetist, Massachusetts General Hospital; Professor of Anesthesia, Harvard Medical School.

Received from the Department of Anesthesia and Cardiac Anesthesia Group, Massachusetts General Hospital, the Anesthesia Laboratory of the Harvard Medical School at the Massachusetts General Hospital, and the Departments of Medicine and Pediatrics, Massachusetts General Hospital and Harvard Medical School, Boston, Massachusetts 02114. Accepted for publication May 11, 1981.

Address reprint requests to Dr. Lowenstein: Department of Anesthesia, Massachusetts General Hospital, Boston, Massachusetts 02114.

Key Words: Heart: electrocardiography, long Q-T syndrome. Anesthesia: obstetric.

REPORT OF A CASE

A 26-year-old gravida 3 para 2 woman, eight weeks pregnant, was scheduled for therapeutic abortion and laparoscopic tubal ligation. The diagnosis of LQTS was made at age 23 years, after a three-year-old nephew with this entity was successfully resuscitated from ventricular fibrillation. The patient denied chest pain, shortness of breath, palpitations, paroxysmal nocturnal dyspnea, orthopnea, or dizziness. Three other members of the family also have the LQTS. There was no family or personal history of deafness. The patient had tolerated two prior full term pregnancies with vaginal delivery under spinal anesthesia, as well as full mouth dental extraction under general anesthesia. No perioperative cardiac evaluation was available from these procedures. The patient smoked two packs of cigarettes per day, had no known allergies, and was taking no medications. Physical examination revealed a healthy young woman in no distress. Blood pressure was 132/72 torr with no orthostatic change. Heart rate was 88 beats/min and regular. There was no extrasystolic activity at rest or with exercise; the respiratory rate was 18 breaths/min. Examination of the heart, chest, abdomen, and central nervous system was normal. Chest roentgenogram, blood urea nitrogen, and serum creatinine, sodium, potassium, and calcium were normal. Standard 12 lead electrocardiogram revealed normal sinus rhythm with a heart rate of 80 beats/min. The Q-T interval was prolonged at 0.52 seconds. (fig. 1A) Echocardiogram was normal.

Morphine, 10 mg, im, and diazepam, 10 mg, orally were given one hour before anesthesia. The patient arrived in the operating suite well-sedated with a heart rate of 60 beats/min. Additional sedation was provided by incremental intravenous doses of Innovar® (total 5 mg fentanyl and 12.5 mg droperidol) under continuous electrocardiographic monitoring (lead V₄). A central venous catheter was inserted and the right radial artery cannulated. The oropharynx was sprayed with 4 per cent lidocaine, 3 ml, and the trachea anesthetized transtracheally with 4 per cent lidocaine, 2 ml. Thiopental, 50 mg, was administered intravenously, direct laryngoscopy was performed, and the trachea intubated during continuous electrocardiographic and arterial blood pressure monitoring. No change was observed in these variables. Anesthesia was maintained with 60 per cent nitrous oxide and 0.5-1 per cent inspired concentration of enflurane with controlled ventilation. Two transient episodes of junctional rhythm, unaccompanied by changes in arterial blood pressure, reverted spontaneously to sinus rhythm. During the remainder of the operation, blood pressure remained stable at 100/60 torr, and normal sinus rhythm was maintained at a rate of 72 beats/min without change in Q-T interval. Intraoperatively PaO₂ was 274 torr, PaCO₂ 32 torr and pH_a 7.44 at an FI_{O₂} of 40 per cent. After termination of the surgical procedure, the oropharynx was suctioned and all anesthetic agents discontinued. Five minutes later, the patient opened her eyes, adequate spontaneous respiration resumed, and the endotracheal tube was removed. Following tracheal extubation, the heart rate increased to 100 beats/min and the blood pressure to 125/70 torr, and unifocal ventricular premature beats (VPB) were observed (fig. 2A). The VPBs increased in frequency whenever the patient was aroused from light sleep by verbal stimulation. Increments of intravenous propranolol to a total dose of 1.5 mg were administered when ventricular bigeminy was observed. Following a run of ventricular tachycardia lasting 4 seconds (fig. 2B), 50 mg lidocaine, iv was administered and lidocaine infusion at a rate of 2 mg/min was initiated. Additional propranolol, 1 mg, was administered to a total dose of 4 mg. Ventricular ectopic activity abated following the lidocaine. The patient was transferred with a cardiac rhythm monitor to the postoperative recovery room. Laboratory values on arrival in the recovery room were PaO₂ 123 torr, PaCO₂ 40 torr, pH_a 7.36 on FI_{O₂} 0.4 via face mask, serum sodium 136 mEq/l, serum potassium 4.0 mEq/l, and hematocrit 33 per cent. Lidocaine infusion was decreased to 1 mg/min and no arrhythmias were observed with continuous

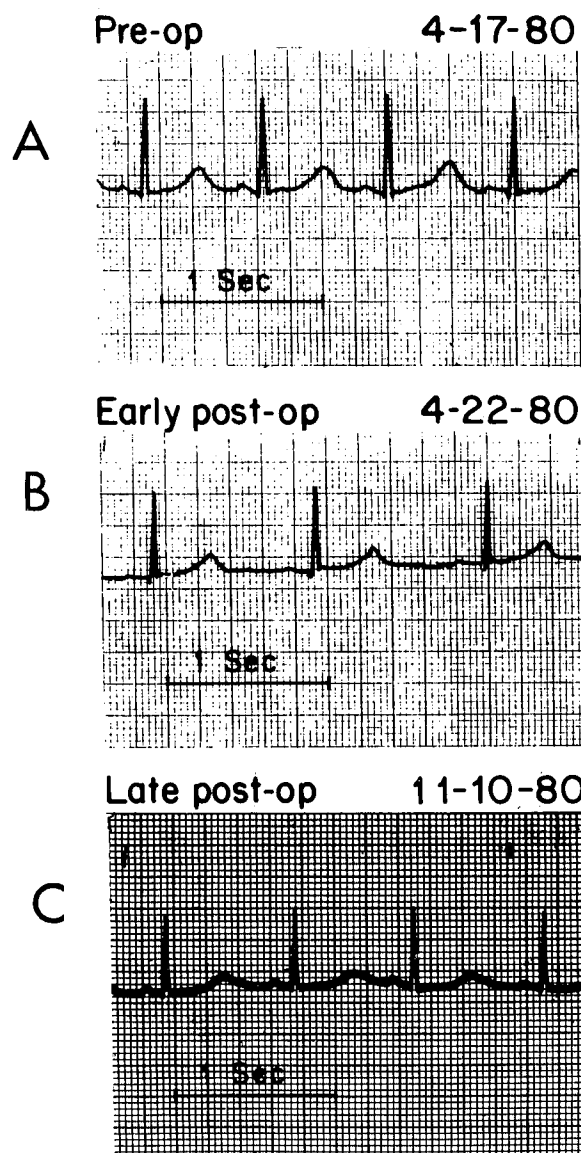


FIG. 1. A is the preoperative lead II rhythm strip demonstrating abnormal Q-T interval prolongation to 0.52 seconds. B illustrates slight shortening of the early postoperative Q-T interval on the lead II rhythm strip to 0.48 seconds, despite mild slowing of the heart rate to 56 beats/min. C is the late postoperative lead II rhythm strip which shows persisting prolongation of the Q-T interval to 0.53 seconds.

rhythm monitoring. The patient was transferred to the medical intensive care unit. Lidocaine administration was discontinued 24 hours after the operation. Ventricular ectopic activity occurred 3 hours later. (fig. 2C) Lidocaine was reinstated with cessation of ectopic activity. Administration of phenytoin was started (1.2 g, po followed by 200 mg, po, bid) No further VPBs were noted during continuous cardiac rhythm monitoring, despite discontinuation of the lidocaine infusion for 72 hours. The patient was discharged on the sixth postoperative day, taking a maintenance dose of phenytoin 200 mg twice daily. The Q-T interval after four days of oral phenytoin was 0.48 s (fig. 1B). Four weeks after discharge the electrocardiogram revealed normal sinus rhythm with a Q-T interval of 0.53 seconds and no ventricular ectopic activity (fig. 1C).

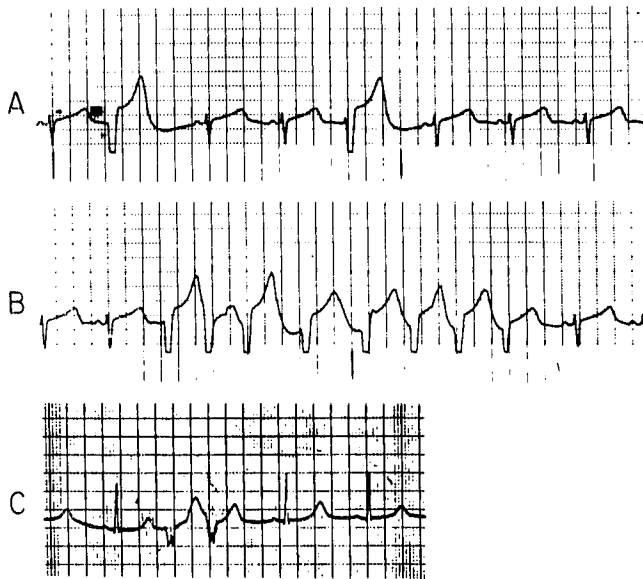


FIG. 2. *A* is a rhythm strip recorded from the right precordial intraoperative monitoring lead which illustrates normal sinus rhythm and unifocal ventricular premature beats. The heart rate was 70 beats/min and the Q-T interval was 0.50 seconds. *B* illustrates an eight beat run of ventricular tachycardia which was preceded and followed by normal sinus rhythm. The Q-T interval was 0.49 seconds and the heart rate was 80 beats/min. *C* is a lead II rhythm strip which shows normal sinus rhythm interrupted by a couplet of premature ventricular beats. The Q-T interval was 0.50 seconds and the heart rate 64 beats/min.

DISCUSSION

Because of the increased awareness of this entity, increasing numbers of patients with LQTS are now being identified prior to anesthesia and surgery. At present there are no guidelines for perioperative management of these patients, and only rare cases have been described.⁷ Our patient illustrates some of the problems associated with the LQTS and highlights the need for additional such descriptions.

Despite the many advances made in the understanding of the LQTS, the precise pathogenesis remains unclear. At present, imbalance of adrenergic influences on the myocardium is considered the most tenable etiology. Prolongation of the Q-T interval is associated with either stimulating the left stellate ganglion or ablating the right stellate ganglion in dogs.⁸

Continuous cardiac rhythm monitoring, including monitoring during the perioperative period, is essential and has not been stressed previously. Preoperative sudden death of a hospitalized patient with this entity has been described.⁵ Only perioperative electrocardiographic monitoring allowed recognition of high grade ventricular ectopy in our patient. Ventricular ectopy first occurred with arousal following tracheal extubation, a time when such ectopy might not be anticipated, though precipitation of ectopy by increased heart rate and blood pres-

sure has previously been reported.⁴ Rhythm monitoring during transport to the recovery unit would thus appear mandatory, even for asymptomatic patients. Interestingly, patients with LQTS have developed ventricular ectopy with auditory stimuli.⁹ Indeed, physical, as well as mental, stresses may provoke ventricular ectopic activity.¹³

Once ventricular ectopy develops, management is controversial. Lidocaine has been reported to be ineffective in the control of ectopy in patients with LQTS. However, in our patient, lidocaine was twice associated with relief of ventricular ectopy, including ventricular tachycardia. We therefore recommend a trial of lidocaine for perioperative ventricular ectopic activity in patients with LQTS.

Currently, oral propranolol is widely used for chronic management of LQTS.^{3-5,10} Our initial therapy of ventricular ectopic activity consisted of intravenously administered propranolol. Propranolol exerts its beneficial effect by suppressing the effects of sympathetic discharge, rather than by shortening the Q-T interval. In fact, in LQTS, intravenously administered propranolol has been shown to prevent epinephrine-induced ventricular fibrillation.⁴ However, since propranolol by itself did not prevent progression of the ventricular ectopy in our patient, we administered lidocaine. Because it is possible that the propranolol effect was delayed or the dosage was too small in our patient, we feel that further experience with propranolol in the acute setting is needed before conclusions may be drawn.

Bradycardia is not uncommon in the LQTS,⁵ and beta-blockade may further decrease heart rate, which may predispose to ventricular ectopic escape rhythms. Thus, in patients with underlying bradycardia, we believe propranolol should be avoided.

Phenytoin was given orally in our patient for control of late postoperative ventricular ectopy. Experience with perioperative phenytoin for controlling ectopy is minimal, although intravenous phenytoin has been reported to decrease the Q-T interval. In addition to its direct myocardial effect, phenytoin has a primary antiarrhythmic effect thought to be related to an action upon the midbrain.¹¹

We elected to start the patient on chronic phenytoin when ectopic activity recurred 30 hours postoperatively. That episode may have been secondary to perioperative stress or other transient unknown factors. Therefore, the decision to initiate chronic antiarrhythmic medication in this patient is open to question, and emphasizes the lack of guidelines for antiarrhythmic management of the LQTS in general.

Quinidine and procainamide should be avoided in LQTS because both increase the duration of repolarization. Digoxin has been reported to decrease the Q-T

interval,¹ but has been ineffective in decreasing ventricular ectopy.^{4,10} If electrolyte imbalance exists, rapid intravenous digitalization may itself cause ventricular ectopy.

Primidone, a barbiturate, has recently been described to be an effective drug for treatment of LQTS.¹² Numerous earlier reports have attributed efficacy to other phenobarbital preparations as well.² Thus, further evaluation of rapid acting anticonvulsant drugs would be useful as they may be helpful during the perioperative period.

Surgical ablation of the left stellate ganglion is reported to decrease both the Q-T interval and ventricular ectopy in some patients with LQTS.⁶ However, this has not been the uniform experience,^{5,11} and some patients have not been improved. Nevertheless, temporary pharmacologic blockade of the left stellate ganglion may be an alternative therapy for suppression of otherwise refractory malignant ventricular ectopy encountered in the perioperative period.

REFERENCES

1. Jervell A, Lange-Nielsen F: Congenital deaf-mutism, functional heart disease with prolongation of the QT interval, and sudden death. *Am Heart* 54:59-68, 1957

2. Romano C, Gemme G, Pongiglione R: Aritmie, cardiache rare dell'eta pediatrica. Accessi sincopali per fibrillazione ventricolare parossistica. *Clin Pediatr* 45:656-683, 1963
3. Ward OC: New familial cardiac syndrome in children. *J Intern Med Assoc* 54:103-106, 1964
4. Garza LA, Vick RL, Nora JJ, et al: Heritable Q-T prolongation without deafness. *Circulation* 41:39-48, 1970
5. Schwartz PJ, Periti M, Malliani A: The long Q-T syndrome. *Am Heart J* 89:378-390, 1975
6. Moss AJ, McDonald J: Unilateral cervicothoracic sympathetic ganglionectomy for the treatment of long Q-T interval syndrome. *N Engl J Med* 285:903-904, 1971
7. Owitz S, Pratilas V, Pratilas MG, et al: Anesthetic considerations in the prolonged Q-T interval. A case report. *Can Anaesth Soc J* 26:50-54, 1979
8. Yanowitz F, Preston JB, Abildskov JA: Functional distribution of right and left stellate innervation to the ventricles: production of neurogenic electrocardiographic changes by unilateral alteration of sympathetic tone. *Circ Res* 18:416-428, 1966
9. Wellens HJJ, Vermeulen A, Dyrer D: Ventricular fibrillation occurring on arousal from sleep by auditory stimuli. *Circulation* 46:661-665, 1972
10. Gale GE, Bosman CK, Tucker RB, et al: Hereditary prolongation of Q-T interval-study of two families. *Br Heart J* 32:505-509, 1970
11. Ratchin RA, Hunt D, et al: Q-T interval prolongation; paroxysmal ventricular arrhythmias, and convulsion syncope. *Ann Intern Med* 75:919-924, 1971
12. De Silvey DL, Moss AJ: Primidone in the treatment of the long Q-T syndrome: Q-T shortening and ventricular arrhythmia suppression. *Ann Intern Med* 93:53-54, 1980
13. Chaudron JM, Heller F, et al: Attacks of ventricular fibrillation in a patient with prolonged Q-T interval. A family study. *Am Heart J* 91:783-791, 1976

Anesthesiology
55:589-591, 1981

Pneumocholethorax: A Rare Complication of Stellate Ganglion Block.

K. J. THOMPSON, M.B., CH.B., FFARACS,* P. MELDING, M.B., CH.B., FFARCS,† AND V. S. HATANGDI, M.D. (ANAES.), FFARACS, D.A.‡

The following is a report of a rare complication of stellate ganglion block.

REPORT OF A CASE

A 24-year-old woman had pain in her left wrist for one year. She had been treated by manipulation under anesthesia and an intra-articular injection of hydrocortisone. This relieved the pain for only three

weeks. Roentgenograms of the wrist were normal and the orthopedic surgeon did not feel that surgical exploration was justified.

The patient complained of severe pain in the back of her left hand and wrist and at the base of her thumb. The pain was disabling as she was left-handed and a clerical worker. On examination tenderness was at the base of the first metacarpal from both light and deep palpation. Sensation was diminished over the dorsal surface of the thumb, index and middle fingers and palmar surfaces of the terminal phalanges of the same digits. A loss of abduction of the thumb was also present.

To exclude a peripheral neuropathy, hemoglobin, white blood count and differential, peripheral blood smear, a glucose tolerance test, serum folate and vitamin B₁₂ levels and nerve conduction were determined and found to be normal. To determine whether a sympathetic dystrophy was present, a diagnostic left stellate ganglion block was attempted, employing the standard anterior paratracheal approach.¹

No abnormalities were noted on positioning the patient except the suprasternal notch appeared to be low. After infiltration with a local anesthetic, a 22-gauge 5-cm needle was inserted 3 cm above the sternoclavicular joint in the groove between the trachea and the belly of the sternomastoid muscle. There was no resistance to passage of the

* Anaesthetic Specialist.

† Director, Pain Clinic.

‡ Visiting Anaesthetic Specialist.

Received from the Auckland Hospital, New Zealand. Accepted for publication May 11, 1981.

Address reprint requests to Dr. K. J. Thompson: Hong Kong Government, Queen Elizabeth Hospital, Wylie Road, Kowloon, Hong Kong.

Key words: Anesthetic/techniques, regional: stellate. Complications: pneumocholethorax.