

technique, no posterior spread was seen in six patients when the transcrural technique was used.

Boas,⁹ in a technique using fluoroscopy, was the first to note the difference between transcrural *celiac* block and retrocrural *splanchnic* block. However, the precise needle positioning relative to soft tissue landmarks, necessary to ensure proper placement of the tips at the location of the celiac ganglia, was not described, and the necessarily asymmetric insertion of the left and right needles was not noted. While the difference in soft tissue definition between fluoroscopic and computed tomographic radiography is perhaps a minor additional advantage, it is one which may assume great importance when considering the proximity of the thoracic duct, aortic wall, inferior vena cava, and renal parenchyma to the site of injection of a tissue-destructive substance. In addition, tumor enlargement may significantly alter the anatomic relationship of soft tissue structures. The use of CT scans to delineate this anatomy may increase the incidence of successful blockade.

The transcrural path of the needle is the essential alteration of Moore's technique.⁵ This technique requires the use of computed tomography for determining needle depth and avoiding perforation of the aorta or vena cava,

and, therefore, cannot be recommended as the method for routine blockade of the celiac plexus. The classic technique has worked well, and is still used for surgery and diagnostic blockade prior to neurolysis.

REFERENCES

1. Warren KW: The control of acute and chronic pancreatic pain. *Surg Clin North Am* 30:873-883, 1950
2. Jones RR: A technique for injection of the splanchnic nerves with alcohol. *Anesth Analg (Cleve)* 36:75-77, 1957
3. Bridenbaugh LD, Moore DC, Campbell DD: Management of upper abdominal cancer pain. *JAMA* 190:877-880, 1964
4. Thompson GE, Moore DC, Bridenbaugh LD, et al: Abdominal pain and alcohol celiac plexus nerve block. *Anesth Analg (Cleve)* 56:1-5, 1977
5. Moore DC, Bush WH, Burnett LL: Celiac plexus block: a roentgenographic, anatomic study of technique and spread of solution in patients and corpses. *Anesth Analg (Cleve)* 60:369-379, 1981
6. Moore DC: *Regional Block; a Handbook for Use in the Clinical Practice of Medicine and Surgery*. Third edition. Springfield, Illinois, C. C. Thomas, 1961, pp 121-137
7. Ward EM, Rorie DK, Naus LA, et al: The celiac ganglia in man: Normal anatomic variations. *Anesth Analg (Cleve)* 58:461-465, 1979
8. Gray H: 1901 Edition. *Anatomy, Descriptive and Surgical*. Edited by Pick TP. Philadelphia, Running Press, 1974, pp 806-809
9. Boas RA: Sympathetic blocks in clinical practice. *Int Anesthesiol Clin* 16:149-157, 1978

Anesthesiology
56:141-143, 1982

Tracheomegaly

WINSTON C.V. PARRIS, M.D.,* AND A. C. JOHNSON, M.D.†

Tracheomegaly, or tracheobronchiomegaly, is a rare syndrome consisting of marked dilatation of the trachea and major bronchi usually due to a congenital defect of the elastic and muscle fibers of the tracheo-bronchial tree. The diagnosis follows roentgenological investigation and is associated frequently with chronic respiratory infection and partial airway obstruction. Most of the symptoms usually appear during childhood.^{1,2}

In this report we present a case of adult onset tracheomegaly, probably secondary to intensive radiotherapy. This entity is of importance to anesthesiologists because of a predisposition to aspiration pneumonitis

during general endotracheal anesthesia and to tracheal trauma by endotracheal tubes, suction catheters, and tracheal instrumentation.

REPORT OF A CASE

A 67-year-old man developed carcinoma of the base of the tongue approximately three years ago, and this was managed with a series of 37 radiotherapy treatments to his neck area. Although his cancer was controlled adequately, he developed radionecrosis of the mandible. A hemimandibulectomy was scheduled under general anesthesia. He was a heavy smoker with a chronic cough associated with production of copious purulent sputum and chronic pulmonary parenchymal changes as evidenced by both auscultation findings and chest radiographs (fig. 1). Pulmonary function tests were not obtained, but pH_a was 7.43, Pa_{CO_2} 36 mmHg, and Pa_{O_2} 98 mmHg on room air. There were no other significant positive findings except emaciated appearance (weight 58 kg) due to the associated anorexia from the carcinoma.

Anesthesia was induced with 0.4 mg intravenous atropine, 3.0 mg *d*-tubocurarine, 150 mg thiopental, 5 mg diazepam, and 80 mg succinylcholine. The trachea was intubated with an 8.5-mm nasal endotracheal tube. Anesthesia was maintained with nitrous oxide, and halothane and ventilation was controlled. Besides the initial dose of succinylcholine, no other muscle relaxants were used. After securing

* Assistant Professor, Department of Anesthesiology.

† Assistant Professor, Department of Radiology.

Received from the Departments of Anesthesiology and Radiology, Vanderbilt University Medical Center, Nashville, Tennessee 37232. Accepted for publication August 7, 1981.

Address reprint requests to Dr. Parris: Assistant Professor, Anesthesiology, Vanderbilt University, Nashville, Tennessee 37232.

Key words: Airway; tracheomegaly. Equipment: tubes, endotracheal. Complications: aspiration.

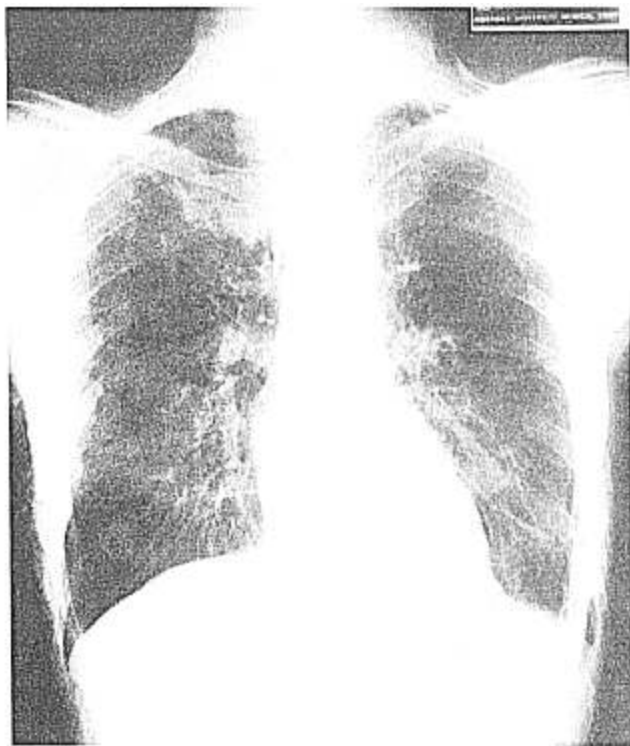


FIG. 1. Chest roentgenogram showing a fusiform dilatation of the trachea above the aortic knob.

the endotracheal tube, chest auscultation revealed symmetrical but distant breath sounds and a significant peritubal leak was evident. This leak was never eliminated completely despite reinflation of the cuff of the endotracheal tube with air. The leak became so significant that we assumed that the cuff had ruptured during endotracheal intubation. Consequently, we decided to replace the endotracheal tube. After the second endotracheal intubation, a leak was still present, although it was less than the leak in the first tube. Surprisingly, we observed that the cuff of the first endotracheal tube had not ruptured.

To proceed with surgery, the laryngopharynx was packed with moist sponges to minimize the risk of aspiration of blood. Throughout the 9.5-hour procedure, there were minor problems all related to the persistent leak around the cuff of the endotracheal tube. Following surgery, the trachea was not extubated and positive pressure ventilation with intermittent mandatory ventilation (IMV) was continued. The length of the procedure, preoperative chronic pulmonary disease, the possibility of intra-operative aspiration, and the option to wean the patient slowly from the ventilator influenced our decision to use intermittent mandatory ventilation. Postoperatively his pulmonary status was stable as evidenced by normal arterial blood gases and satisfactory tidal volume, vital capacity, and negative inspiratory force measurements. His cardiovascular system was stable and chest roentgenogram was unremarkable. He was weaned from the ventilator, and the trachea was extubated approximately 40 hours after surgery. He continued to receive 40 per cent oxygen via face mask and secretions were controlled by frequent suctioning of the pharynx through a soft and flexible nasopharyngeal airway.

With repeat roentgenograms, the trachea was noted to be markedly enlarged and review of all the previous roentgenograms confirmed fusiform tracheomegaly in all cases. To evaluate the exact nature of this lesion more fully, xeroradiograms (A-P and lateral of neck and upper chest) were done in order to visualize and delineate more fully the soft tissue structures.⁴ Bronchoscopy, tracheogram or bronchogram

would have been hazardous because his jaws were wired together, and thus were not considered. Xeroradiograms showed extensive dilatation of the thoracic trachea extending to the carina, but not involving the bronchi. In the mid-tracheal region, an area of collapse of the tracheal lumen was demonstrated (fig. 2). Notwithstanding, the patient made good progress and treatment consisted of intensive physiotherapy with percussion, postural drainage, and frequent suctioning. His pulmonary status improved and returned to the preoperative level.

Follow-up chest radiographs and xeroradiographs three months after the patient was discharged from hospital showed that the trachea was still dilated significantly, but that the area of collapse was not as complete as was visualized previously. The patient has since undergone two procedures (debridement of necrotic bone graft) but this was done with local stand-by anesthesia and intravenous sedation with diazepam and butorphanol, and his trachea was not intubated. Presently, the patient is at home and is relatively asymptomatic.

DISCUSSION

Radiotherapy is an acceptable means of controlling and/or treating certain malignant tumors of the head and neck. Radiotherapy can result in many acknowledged complications including radiation pneumonitis, indirect tissue effects due to vascular endothelial damage

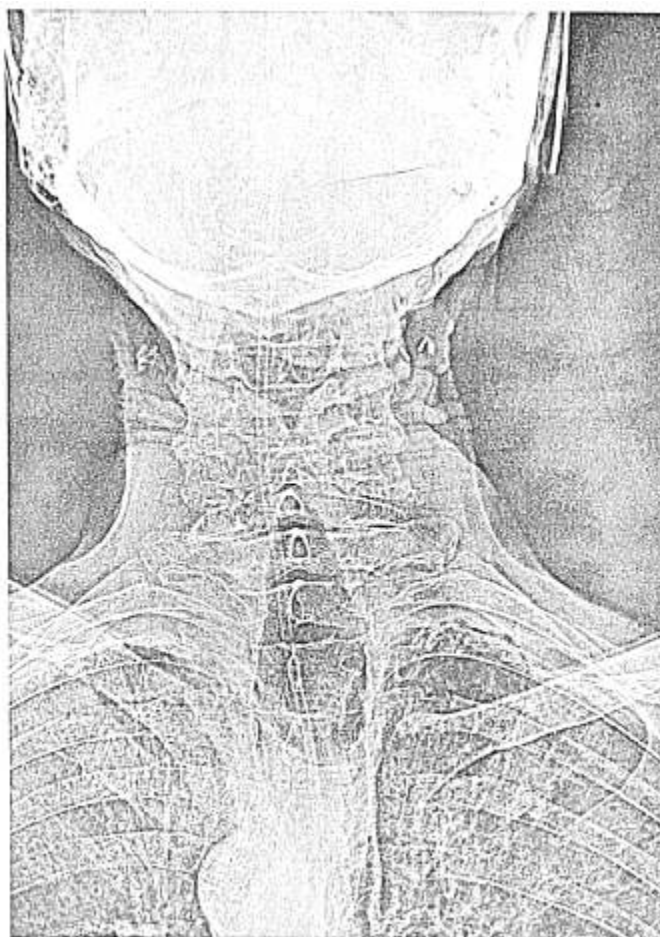


FIG. 2. Xeroradiogram in expiration (AP view) showing collapse of the upper segment of the trachea.

and interstitial fibrosis, chronic inflammatory changes in the nasopharynx, esophageal stenosis, bronchio-esophageal fistula, mandibular osteoradionecrosis, and tracheomegaly.⁵

Actually, any exposed organ or tissue in the neck and face can be affected by the chronic inflammatory and fibrotic changes that follow radiation. While tracheomegaly has not been mentioned specifically as a complication of radiotherapy, our case report illustrates it can occur following radiation-induced fibrosis and atrophic changes in both the elastic and cartilaginous tissues of the trachea. Although he was a heavy smoker, the patient was asymptomatic prior to his illness and had no clinical evidence of pulmonary disease. His chest roentgenograph approximately three years prior to his illness was normal and there was no evidence of tracheomegaly.

As observed in this case, tracheomegaly can occur following radiotherapy. We base our conclusions on the fact that the patient had no clinical or roentgenological evidence of pulmonary disease prior to radiotherapy and on the knowledge that radiotherapy can result in tracheomalacia which itself can lead to tracheomegaly. This is characterized by a fusiform dilatation of the trachea or tracheobronchial tree. This condition, if unrecognized, can lead to a persistent peri-tubal leak in anesthetized patients whose tracheas are intubated even though the cuff of the tube is inflated maximally. Aspiration pneumonia is therefore a potential problem intraoperatively since the gastrointestinal tract is not isolated from the tracheobronchial tree.

Tracheomegaly may be completely asymptomatic. However, the usual clinical features include chronic cough productive of copious and purulent sputum, low grade fever, and symptoms consistent with chronic respiratory tract infection (dyspnea, hoarseness, and loud cough). Tracheomegaly is usually diagnosed by chest roentgenogram and the upper limit of normal for the tracheal diameter of an adult is approximately 30 mm. A measurement of greater than 30 mm is considered to be diagnostic of tracheomegaly.⁶

In this condition, the compliance of the tracheal and bronchial walls is increased markedly resulting in abnormal flaccidity and easy collapsability, especially during forced expiration and cough.⁷ Campbell and Young⁷ described 25 cases of tracheomegaly in which tracheobronchial collapse was observed bronchoscopically during cough or forced expiration. In our patient the xeroradiograph (anterior-posterior view) demonstrated very clearly that there was complete collapse in the region of the proximal one-third and the distal two-thirds of the trachea. This collapse was more significant during expiration (fig. 2).

Tracheomegaly is misdiagnosed frequently, especially in the asymptomatic patient. Documentation of previous radiotherapy to the head and neck region should alert one to the possibility of tracheal problems including tracheomegaly. If tracheomegaly is suspected, the following measures may minimize the anesthetic complications that could result: application of moist oropharyngeal packs to reduce or eliminate the leak - aspiration problem; avoidance of the use of esophageal stethoscopes; careful use of suction catheters to minimize trauma to the thin and fibrotic tissue; the use of positive pressure ventilation to minimize peri-tubal leaks and awareness of the possibility that barotrauma can occur in patients with tracheomegaly receiving positive pressure ventilation.

REFERENCES

1. Bateson EM, Woo-Ming M: Tracheobronchiomegaly. *Clin Radiol* 24:354-358, 1973
2. Hunter TB, Kuhns LR, Roloff MA, et al: Tracheobronchiomegaly in an 18-month-old child. *Am J Roentgenol* 123:687-690, 1975
3. Katz I, LeVine M, Herman P: Tracheobronchiomegaly. The Mounier-Kuhn Syndrome. *Am J Roentgenol* 88:1084-1093, 1962
4. Wolfe JN: Zeroradiography of the bones, joints and soft tissues. *Radiology* 93:583-587, 1969
5. Chacko DB: Considerations in the diagnosis of radiation injury. *JAMA* 245:1255-1258, 1981
6. Fraser RG, Paré FAP: *Diagnosis of Diseases of the Chest*. Philadelphia, W. B. Saunders Co., 1979, pp 1322-1328
7. Campbell AH, Young IF: Tracheobronchial collapse, a variant of obstructive respiratory disease. *Br J Dis Chest* 57:174-181, 1963