

## Enflurane Suppression of Complex Ventricular Dysrhythmias

MYLES SMITH, M.B., B.S., F.F.A.R.C.S.,\* DONALD KROLL, M.D., PH.D.,† JAMES BRECKENRIDGE, M.D.‡

Although disturbances of cardiac rhythm occur commonly under general anesthesia, the incidence of cardiac rhythm disturbances may be lower with enflurane anesthesia than with halothane anesthesia.<sup>1-3</sup> Enflurane also results in less myocardial sensitization to the effects of exogenous catecholamines than halothane.<sup>4,5</sup> Although these data support the conclusion that enflurane is less dysrhythmogenic than halothane, whether or not this effect can truly be termed an antidysrhythmic effect is debatable. The usual usage of this term implies activity in suppressing dysrhythmias, not simply causing fewer dysrhythmias. It is believed, however, that the following case report demonstrates a possible antidysrhythmic effect of enflurane.

## REPORT OF A CASE

A 57-year-old man weighing 65.9 kg was scheduled for a vagotomy and antrectomy. He had a one-year history of increasing post-prandial nausea and vomiting. Eight years earlier, a peptic ulcer, hiatal hernia, and esophagitis were diagnosed following a hematemesis. He responded well to medical treatment at that time.

The relevant past medical history consisted of an episode of palpitations and exertional dyspnea one year previously. An electrocardiogram showed sinus rhythm and left anterior fascicular block. The patient was started on 100 mg disopyramide, t.i.d., and the palpitations and dyspnea ceased. The chest roentgenogram taken at the same time revealed a calcified nodule in the left lower lobe close to the diaphragm. In view of a history of prolonged exposure to asbestos, the diagnosis of asbestosis was made. There was no historical or physical evidence suggesting ischemic heart disease.

Three weeks prior to surgery his disopyramide was discontinued as it was thought to be contributing to his nausea and vomiting. He was started on 200 mg cimetidine, t.i.d., and 10 mg prochlorperazine, p.r.n., and his nausea and vomiting lessened.

Laboratory data including hemoglobin, hematocrit, white cell count, coagulation screen, serum electrolytes, and liver function tests, were all within normal limits. The chest roentgenogram showed no further changes. Electrocardiography again showed sinus rhythm and left an-

terior fascicular block. However, in view of the history of palpitations and the clinical finding of an irregular pulse, the cardiac rhythm was evaluated by Holter monitoring. Over a 20-h period there were 5,099 premature ventricular beats, including rare to frequent multifocal premature contractions, rare episodes of bigeminy, two episodes of ventricular tachycardia, and a small number (37) of premature atrial contractions. An episode of "quadrageminy" was also noticed which may in fact have represented a parasystolic mechanism.

Diazepam, 10 mg, was given orally, 1.5 h preoperatively. He was also given a bolus of 125 mg lidocaine, followed by an infusion of lidocaine at the rate of 2 mg/min. Despite this, the preinduction electrocardiogram showed 10-15 premature ventricular contractions (PVCs) per minute. The lidocaine was discontinued since it was thought to be ineffective.

Anesthesia was induced with 250 µg fentanyl, and 250 mg thiamylal sodium, intravenously. Pancuronium, 7 mg, was administered intravenously and the patient was ventilated via a mask with 50 per cent nitrous oxide and 2 per cent enflurane until paralysis was established. After spraying the cords with 4 ml 4 per cent lidocaine, the trachea was intubated. Monitoring consisted of an EKG incorporating a V<sub>5</sub> electrode, an esophageal stethoscope, and a sphygmomanometer attached to the arm. After ventilation was controlled, the frequency of PVCs decreased steadily, so that at the time of endotracheal intubation less than two per minute were observed.

Anesthesia was maintained with 70 per cent nitrous oxide and 0.5 per cent enflurane. No further PVCs were seen for 60 min. After this time the enflurane was discontinued because the blood pressure had fallen to 100/55 torr with a heart rate of 85 beats/min; 15 min later the PVCs returned in excess of 10 per minute (fig. 1). There were no signs to suggest decreased depth of anesthesia such as significant tachycardia or hypertension, sweating, or increased pupillary activity. The blood pressure was 110/60 mmHg and heart rate of 80 beats/min. Enflurane, 0.5 per cent, was recommenced and within 5 min no PVCs were observed (fig. 1), the blood pressure was stable at 110/60 mmHg with a heart rate of 75 beats/min. The operation proceeded uneventfully. Paralysis was reversed fully with 0.6 mg glycopyrrolate, and 2.5 mg neostigmine. One hundred per cent oxygen was administered and the trachea extubated. Soon after extubation, despite breathing on 100 per cent oxygen via a mask with apparent adequate ventilation, the PVCs returned at the preoperative frequency. They were treated in the postoperative recovery ward, by a further bolus 75 mg of lidocaine, and an infusion of lidocaine at a rate of 2 mg/min. This was continued for 24 hours and the PVCs were suppressed partially but were not abolished fully. No underlying cardiac disease was discovered to account for the patients ventricular dysrhythmias and he was discharged home nine days postoperatively taking no antidysrhythmic medications.

## DISCUSSION

The preoperative Holter monitoring evaluation of this patient demonstrated a wide variety of disturbances in cardiac rhythm. The patients only symptom was intermittent palpitations. The etiology of the dysrhythmias has not been established clearly despite extensive non-invasive evaluation. Initial therapy with lidocaine was

\* Instructor of Anesthesiology, University of Michigan Medical Center, Ann Arbor, Michigan 48109.

† Burroughs Wellcome Fellow, Department of Anesthesiology, University of Michigan Medical Center, Ann Arbor, Michigan 48109.

‡ Resident, Department of Anesthesiology, University of Michigan Medical Center, Ann Arbor, Michigan 48109.

Received from the University of Michigan Medical Center, Ann Arbor, Michigan 48109. Accepted for publication August 11, 1981.

Address all reprint requests to Dr. Smith: Department of Anesthesiology, University of Michigan Medical Center, Room S6344, Ann Arbor, Michigan 48109.

Key words: Anesthetics, volatile; enflurane. Heart: dysrhythmia; treatment.

not effective in suppressing ventricular ectopy in this patient. Effective antidysrhythmic therapy with disopyramide could not be resumed until surgical correction of the peptic ulcer disease and delayed gastric emptying because of the exacerbation of his symptoms attributed to this drug. Therefore, it was decided to proceed with surgery despite the high frequency of PVCs. The administration of enflurane and induction of general anesthesia restored a normal sinus rhythm. Pancuronium was chosen to avoid bradycardia and minimize the rate related slowing of AV nodal conduction associated with enflurane in the hope of facilitating overdrive suppression of ectopic beats. Although, the beneficial effects of other drugs cannot be ruled out completely, the return of ventricular ectopy following the discontinuation of enflurane argues against a major contributing factor of the other drugs administered.

In this patient enflurane appears to have suppressed ventricular dysrhythmias which may have arisen from two different mechanisms. The first type of ectopic beat included those beats with a constant coupling interval to the preceding normal sinus beat. The coupling interval of these beats was on the order of 460 ms with a range of 440–480 ms during a run of bigeminy. There was slight variability in the coupling interval at different times during the entire period of Holter monitoring from 380–500 ms but during each run of activity the variability was within 40 ms. When this type of dysrhythmia occurred after discontinuation of enflurane, the coupling interval was prolonged to 600 ms and the dysrhythmia was abolished by further administration of enflurane (fig. 1). Although the reappearance of these dysrhythmias was not related to any significant change in heart rate or blood pressure, a lighting of anesthetic depth or enhanced autonomic activity can not be ruled out with certainty.

The second type of ventricular activity noted in this patient was indicative of a parasystolic focus. This type of activity is suggested by a variable coupling interval of the ectopic to the preceding normal sinus beat, the presence of fusion beats and a relatively constant interectopic interval of just over 1400 ms. After extubation the trachea and the discontinuation of enflurane the parasystolic focus did return although the interectopic interval was on the order of 1860 ms, somewhat prolonged from the interectopic interval noted preoperatively.

Although the cardiac electrophysiologic effects of enflurane have not been evaluated fully, enflurane does suppress both automaticity and conduction.<sup>6-8</sup> The presence of ventricular ectopic beats occurring with a constant coupling interval to the preceding normal sinus beats suggests that the probable genesis of these dysrhythmias was reentrant in origin. There are two possible mechanisms for parasystolic dysrhythmias. The ectopic focus

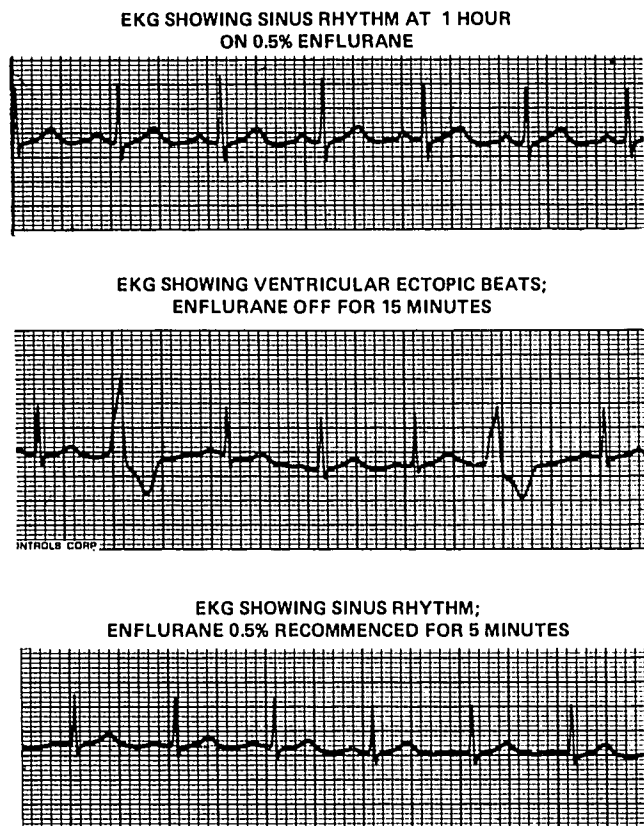


FIG. 1. The establishment of sinus rhythm under anesthesia with enflurane (Panel 1), the recurrence of ventricular ectopy after this was discontinued (Panel 2), and the restoration of sinus rhythm after enflurane was recommenced (Panel 3).

(with automatic or reentrant impulse origin) may be protected from depolarization by the more proximal propagating wavefront by a unidirectional entrance block. Alternately, the parasystolic focus may represent a concealed latent tachycardia which is protected by its own rapid firing rate which ensures refractoriness to oncoming impulses. In such a case the slow manifest discharge rate is a result of exit block.<sup>9</sup>

Thus, disordered cardiac conduction is required for both of these types of dysrhythmias observed in this patient. The return of normal sinus rhythm following the administration of enflurane provides at least presumptive evidence that the beneficial effect of enflurane in this patient was related to depression of conduction. Depression of cardiac conduction could have led to the abolition of the reentrant pathway resulting in the suppression of the reentrant dysrhythmias, as well as to the formation of exit block leading to the suppression of the parasystolic dysrhythmias. Suppression of abnormal automaticity could also have been a factor in abolishing the parasystole.

Although further controlled studies will be necessary to clarify the direct electrophysiologic effects and possible

indirect autonomic effects of enflurane, we speculate on the basis of this case report that enflurane may possess antidysrhythmic activity and that this could possibly be related to a depression of cardiac conduction.

## REFERENCES

1. Reinsner LS, Lippmann M: Ventricular arrhythmias after epinephrine injection in enflurane and in halothane anesthesia. *Anesth and Analg (Cleve)* 54:468-470, 1975
2. Williams HD, Law S: Cardiac arrhythmias during coronary-artery operations with halothane or enflurane anesthesia. *ANESTHESIOLOGY* 50:551-553, 1979
3. Pratiła MG, Pratiła V, Smith H: Dysrhythmias and enflurane anesthesia. *Mt Sinai J of Med* 46:500-504, 1979
4. Lippmann M, Reinsner LS: Epinephrine injection with enflurane anesthesia: incidence of cardiac arrhythmias. *Anesth Analg (Cleve)* 53:886-889, 1974
5. Konchigeri HN, Shaker MH, Winnie AP: Effect of epinephrine during enflurane anesthesia. *Anesth Analg (Cleve)* 53:894-897, 1974
6. Merlos JR, Bosnjak ZJ, Purtock RV, et al: Halothane and enflurane effects of SA node cells. *ANESTHESIOLOGY* 53:S143, 1980
7. Atlee JL, Rusy BF: Atrioventricular conduction times and atrioventricular nodal conductivity during enflurane anesthesia in dogs. *ANESTHESIOLOGY* 47:498-503, 1977
8. Atlee JL, Rusy BF, Krueel JF, et al: Supraventricular excitability in dogs during anesthesia with halothane and enflurane. *ANESTHESIOLOGY* 49:407-413, 1978
9. Hurst JW: *The Heart, Volume 1*, New York, McGraw Hill, 1978, pp 686

Anesthesiology  
56:150-151, 1982

## Use of Two Epidural Catheters to Provide Analgesia of Unblocked Segments in a Patient with Lumbar Disc Disease

SANDY M. SCHACHNER, M.D.,\* AND STEPHEN E. ABRAM, M.D.†

The insertion of lumbar and caudal epidural catheters in the same patient to provide pain relief for labor and delivery has been described previously.<sup>1,2</sup> In this case, a second lumbar epidural catheter was inserted to provide adequate analgesia of unblocked segments for labor and delivery in a patient with lumbar intervertebral disc disease.

## REPORT OF A CASE

A 28-year-old woman (gravida 3, para 0) was admitted in early labor with ruptured membranes. The past medical history included a back injury two years previously resulting in damage to the L4-5 intervertebral disc and a chronic right L5 radiculopathy. She frequently had sharp pain radiating deep to her right hip and down the medial aspect of her right leg, and numbness of the medial aspect of her foot and decreased position sense of her right great toe. The numbness and pain increased as her pregnancy progressed.

Sixteen hours after admission her cervix had dilated to 4-5 cm. At that time she was complaining of abdominal, low back, and right hip and leg pain with contractions. A 20-gauge epidural catheter was inserted into L2-3 interspace and threaded 5 cm cephalad without difficulty. After a test dose of 3 ml 1 per cent lidocaine, the patient was placed in the supine position and 11 ml 0.25 per cent bupivacaine was injected. Anesthesia extended superiorly to T7 bilaterally. Anesthesia extended downward through the sacral segments on the left, but did not extend below L4 on the right. Uterine contractions were not felt

on the left, but produced deep pain referred to the right hip. Over the next two hours additional doses of 0.25 per cent bupivacaine were given in an attempt to provide adequate right-sided analgesia. Ten ml of 0.25 per cent bupivacaine were given in the right lateral decubitus position, 12 ml were given in the sitting position, and 14 ml were given in the sitting position after withdrawing the catheter 1-2 cm, without altering the level of analgesia on the right.

At this point a second epidural catheter was threaded up 4 cm through the L4-5 interspace without complication. Eight ml of 0.25 per cent bupivacaine injected through this catheter produced profound analgesia of the unblocked segments including the sacral segments bilaterally. Two subsequent doses (6 and 12 ml) given through the lower catheter over the next 4-h period provided continued complete analgesia with hypesthesia to pinprick extending from T7 through the lower sacral segments bilaterally. Midline episiotomy and outlet forceps delivery of a male infant with an APGAR of 8 and 10 were accomplished without maternal discomfort. The mother's recovery was uneventful with no neurologic sequela.

A follow-up six weeks after delivery revealed a decrease in her symptoms of pain and numbness. These were only present occasionally and appeared to be positional.

## DISCUSSION

The presence of unblocked segments during continuous lumbar epidural analgesia has been reported to occur in 6.7 per cent of patients and to be persistent in 1.5 per cent.<sup>3</sup> This presumably occurs because of failure of the local anesthetic to reach the unblocked nerve roots in sufficient concentrations.<sup>2,3</sup> Perhaps epidural adhesions, scarring or fibrous bands, which result from the healing process following intervertebral disc injury,<sup>4</sup> can interfere with the spread of local anesthetics in the epidural space.<sup>2</sup> Unilateral anesthesia or patchy deficits may, however, occur in otherwise normal patients or as a result of catheter malposition.<sup>2</sup>

\* Resident Physician.

† Associate Professor.

Received from the Department of Anesthesiology, The Medical College of Wisconsin, 8700 West Wisconsin Avenue, Milwaukee, Wisconsin 53226. Accepted for publication August 14, 1981.

Address reprint requests to Dr. Abram.

Key words: Anesthesia: obstetric. Anesthetic techniques: epidural; lumbar. Pain: sciatica. Equipment: catheters, peridural.