

Anesthesiology
56:157, 1982

Airway Management in Patients with Acromegaly

To the Editor:—Anatomical changes involving the airway in patients with acromegaly and the potential problems these airway abnormalities may pose for the anesthesiologist have been reviewed by Southwick and Katz,¹ Ovassapian *et al.*,² and us.³ Southwick and Katz suggested that patients with glottic abnormalities or both glottic and soft-tissue abnormalities “. . . should probably undergo tracheostomy either preoperatively or prior to removal of the endotracheal tube.”¹ They did not mention use of the fiberoptic bronchoscope to facilitate endotracheal intubation in acromegalic patients in whom conventional laryngoscopy would be difficult. We agree with Venus⁴ and Ovassapian *et al.*² that, although tracheostomy may be required for postoperative as well as intraoperative airway management in some advanced acromegalic patients, tracheostomy has its own risks and complications.^{5,6} Fiberoptic laryngoscopy can facilitate what otherwise would be a difficult endotracheal intubation and may prevent unnecessary tracheostomies in patients with acromegaly.

We recently reviewed our experience with 94 acromegalic patients who underwent transsphenoidal hypophysectomy between November 1972 and January 1980. No patient required a tracheostomy. Oral tracheal intubation with the fiberoptic bronchoscope was required in six patients, four on an elective basis (topical anesthesia, intravenous sedation) and two because previous attempts at direct laryngoscopy had been unsuccessful. In our institution difficulty of endotracheal intubation is graded on a scale of 0–1–2, 2 indicating marked difficulty in visualizing and intubating the trachea. In the

88 patients not requiring fiberoptic endotracheal intubation, difficulty of intubation was graded 0 in 55 patients, 1 in 27 patients, and 2 in 6 patients. Thus, our experience does not support the recommendations of Southwick and Katz regarding routine tracheostomy in selected patients.

JOSEPH M. MESSICK, JR, M.D.
Associate Professor of Anesthesiology

ROY F. CUCCHIARA, M.D.
Associate Professor of Anesthesiology

RONALD J. FAUST, M.D.
Assistant Professor of Anesthesiology

*Mayo Clinic
Rochester, Minnesota 55905*

REFERENCES

1. Southwick JP, Katz J: Unusual airway difficulty in the acromegalic patient—indications for tracheostomy. *ANESTHESIOLOGY* 51:72–73, 1979
2. Ovassapian A, Doka JC, Romsa DE: Acromegaly—use of fiberoptic laryngoscopy to avoid tracheostomy. *ANESTHESIOLOGY* 54:429–430, 1981
3. Messick JM, Laws ER, Abboud CF: Anesthesia for transsphenoidal surgery of the hypophyseal region. *Anesth Analg (Cleve)* 57:206–215, 1978
4. Venus B: Acromegalic patient—indication for fiberoptic bronchoscopy but not tracheostomy. *ANESTHESIOLOGY* 52:100–101, 1980
5. McClelland RMA: Complications of tracheostomy. *Br Med J* 2:567–569, 1965
6. Selecky PA: Tracheostomy: a review of present day indications, complications, and care. *Heart Lung* 3:272–283, 1974

(Accepted for publication August 20, 1981.)

Anesthesiology
56:157–158, 1982

Severe Skin Damage from EKG Electrodes

To the Editor:—With improved care in the use of electrocautery, the incidence of electrical burn has decreased; however, it still presents a hazard as illustrated by the following case.

A 50-year-old white woman with no known allergies had surgery performed on her right knee. A dispersive electrocautery electrode (NDH-Silvon) was placed on the left thigh. For cardiac monitoring, EKG electrodes were applied. The anesthesia sequence was thiopental, succinylcholine, and endotracheal administration of enflurane and nitrous oxide; recovery was uneventful.

On the first postoperative day, the three sites where the electrodes were applied showed signs of redness with the precordial area having damaged skin. On the fifth postoperative day, an ulcer had formed, approximately 3 cm in diameter. Its central area showed complete loss of skin and a black eschar. Unlike the precordial area, the central areas on the right and left shoulder showed normal skin; however, there were red circles matching the size and the site of EKG electrode adhesive (fig. 1). Another definite red line with denuded skin showing the adhesive tape marks was noted at the precordium.

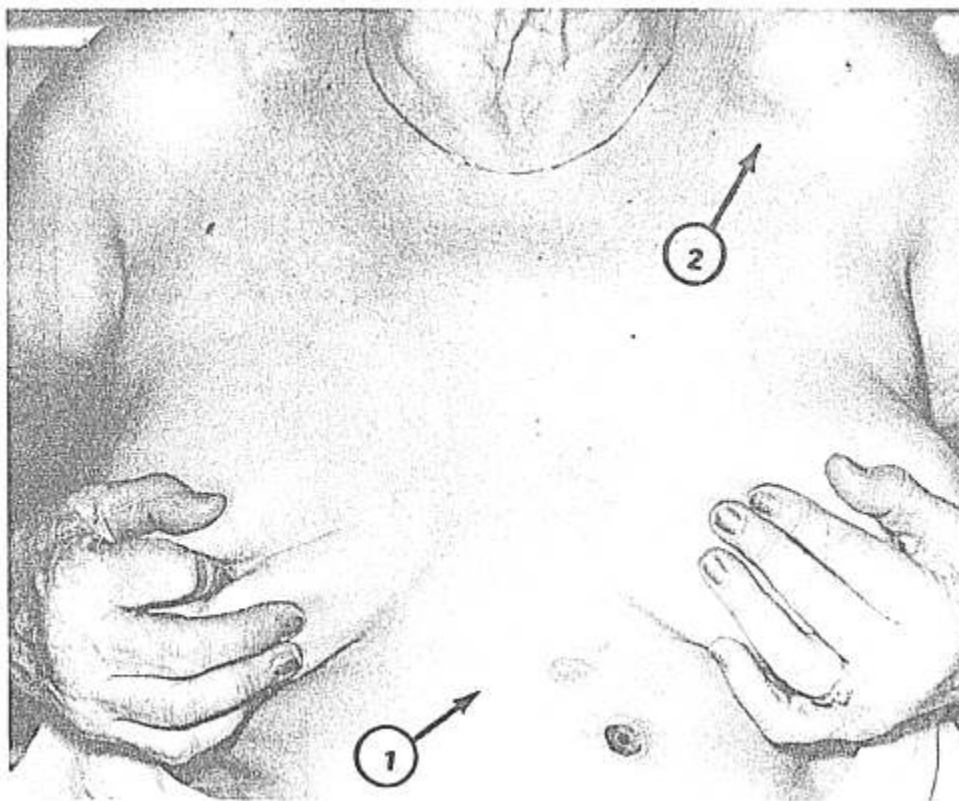


FIG. 1. The precordial ulcer with a circular affected area at the site of EKG lead. *Arrow 1* points to epidermal loss due to adhesive tape. *Arrow 2* shows the normal skin in the middle of the affected area on the shoulder.

The patient was scheduled for amputation three weeks later. In view of the complication with EKG electrodes and to exclude any suspected allergic response, we tested small pieces of two types of electrodes (NDM and Red dot GM) on the patient's forearm for 2.5 hours. There was no adverse reaction on test or after application for surgery on the second occasion. A 24-hour patch test also proved negative.

The etiology of such a lesion can be either severe allergic reaction or electrical burn.^{1,2} During surgery the electrodes were free from any pressure and there was no other preparation of skin which could cause the chemical burn. We used Tektronix® EKG monitor, an isolated unit (ESV Valley Lab), SSE-K Electrocautery Machine, Disposable Valley Lab dispersive electrode, and (NMD) EKG electrodes, which were all in good working order.

The possibility of allergic reaction is worth consideration for these reasons: 1) Sensitivity to adhesive tape was evident (fig. 1, arrow 1). 2) Unlike burns the injury was not apparent at the end of the operation in the recovery room. Instead, it was noted the next day. 3) The precordial ulcer and tissue damage seemed to cover the whole electrode area, while the electrical burn mainly effects the center only. 4) The central area of skin on the right and left shoulder showed normal skin (fig. 1, arrow 2.).

This patient possibly was sensitive to elements in adhesive material³ or the gel; however, the sensitivity test from the following adhesive components were negative:

Triethylamine salt of carboxypolyethylene, ECG gel, isopropyl alcohol, de-ionized water, and P-chloro-m-xylene sodium chloride solution.

There was no medical or drug history. Therefore, with repeated negative allergic tests, we concluded that this represented a case of electrical burn, as electrocoagulation had been used extensively. The sensitivity reaction could be explained as mere coincidence.

We conclude that to prevent such burns⁴ electrically isolated equipment with a safety choke* device, frequently checked and well-maintained should be used. More significantly, indiscriminate use of high-frequency current for extended durations must be avoided.

PHOOL CHANDRA, M.D.

*Associate Professor of Anesthesiology
Texas Tech University Health Sciences Center
El Paso, Texas 79905*

* Radio Frequency Choke.

REFERENCES

1. Block EC, Burton LW: Electrosurgical burn using a battery operated Doppler Monitor. *Anesth Analg (Cleve)* 58:339-342, 1979
2. Finlay B, Crouchie D, Boyce L, et al: Electrosurgery burns resulting from use of miniature ECG electrodes. *ANESTHESIOLOGY* 41:263-269, 1974
3. Bushnell LL, Neils RE: (Tape) Dermatitis associated with acquired zinc deficiency. *Arch Dermatol* 115:1287-1288, 1979
4. Aronow S, Bruner JM: Electrosurgery. *ANESTHESIOLOGY* 42:525-526, 1979

(Accepted for publication August 27, 1981.)