

- setts General Hospital. Edited by Lebowitz PW. Boston, Little Brown and Company. 1978, pp 10-29
5. Mather LE, Tucker GT: Meperidine and other basic drugs: General method for their determination in plasma. *J Pharm Sci* 63:306-307, 1974
 6. Shaw TJI: The Swan-Ganz pulmonary artery catheter. Incidence of complications, with particular reference to ventricular dysrhythmias and their prevention. *Anaesthesia* 34:651-656, 1979
 7. Sprung CL, Jacobs LJ, Caralis PV, et al: Ventricular arrhythmias during Swan-Ganz catheterization of the critically ill. *Chest* 79:413-415, 1981

8. Katz JD, Cronau LH, Barash PG, et al: Pulmonary artery flow-guided catheters in the perioperative period. Indications and complications. *JAMA* 237:2832-2834, 1977
9. Sprung CL, Jacobs LJ, Caralis PV, et al: Hazards of pulmonary artery catheterization. *N Engl J Med* 302:807, 1980
10. Bernstein V, Bernstein M, Griffiths J, et al: Lidocaine intramuscularly in acute myocardial infarction. *JAMA* 219:1027-1031, 1972
11. Foldes FF, Molloy R, McNall PG, et al: Comparison of intravenously given local anesthetic agents in man. *JAMA* 172:1493-1498, 1960

Anesthesiology
56:212-214, 1982

Coronary Air Embolism during Venous Cannulation

JAN CHARLES HORROW, M.D.,* AND STEPHEN O. LAUCKS, M.D.†

Venous air embolism during insertion of intravascular catheters rarely presents a significant hazard in most patients. When intracardiac shunts are present, systemic air embolism may occur. We report a case of venous air embolism leading to air in the coronary arteries.

REPORT OF A CASE

A 60-year-old woman was scheduled for total correction of a tetralogy of Fallot. She had no previous surgery. She suffered from decreasing exercise tolerance over many years and was admitted following an episode of hemoptysis. Several days following recovery from this episode, physical examination revealed a cyanotic woman with arterial blood pressure 110/80 mmHg, heart rate 95 beats/min, and respiratory rate 28/min. While breathing room air, Pa_O, and Pa_{CO}, were each 35 mmHg, and pH_a was 7.51. The hematocrit was 46 per cent. Cardiac catheterization demonstrated a 4.2 l/min right-to-left shunt at the ventricular level, infundibular pulmonic stenosis, overriding aorta, and normal coronary anatomy without intraluminal obstructions.

The patient was brought to the operating room without premedication. Oxygen was administered nasally at 4 l/min. A five lead electrocardiogram monitor was used. A 1-mV calibration pulse in the diagnostic mode spanned 22 mm on the recorder (fig. 1A). Peripheral intravenous and radial artery cannulae were inserted. With the patient tilted head down 10°, a 20-gauge catheter was inserted into the right internal jugular vein. Visualization of venous waveforms by pressure transduction confirmed venous cannulation,¹ an important feature in patients with cyanotic heart disease. A 0.025-inch diameter spring

guide wire passed through the catheter easily and an 8-Fr dilator-introducer was inserted over the wire into the vein.

The patient was instructed to hold her breath and the dilator was removed and replaced with a 16-gauge 5/4-inch catheter. However, she inspired deeply while the introducer was open to atmosphere. At that instant, an assistant at the patient's side heard a churning "mill wheel" sound coming from the patient's precordium. No attempt was made to change the patient's position. Within a minute, the patient complained of heavy precordial pressure. Mean arterial blood pressure then dropped from 90 to 45 mmHg. ECG lead V₅ demonstrated severe ST segment elevation and intermittent second degree AV block (fig. 1B). Her chest pain resolved over several minutes, accompanied by an increase in mean arterial pressure to 90 mmHg and improvement in the ECG (figs. 1C, 1D, and 1E). Her mentation and her sensory and motor functions were assessed throughout this episode; they did not change from baseline. Anesthesia and surgery proceeded without difficulty. High-dose fentanyl with 100 per cent oxygen provided acceptable anesthetic conditions. Several postoperative visits disclosed no myocardial, neurologic, or other sequelae of the embolic episode.

DISCUSSION

This woman sustained venous air embolism massive enough to allow detection without ultrasound or even a stethoscope. This occurred despite several precautions which minimize the likelihood of air entrainment into the circulation: head-down tilt to increase central venous pressure (CVP), occlusion of the introducer to prevent continuity with the atmosphere, and asking the patient to hold her breath while the introducer was exposed to air. Conahan² detected air embolism in one of twelve patients monitored with precordial Doppler ultrasound units during placement of 8-Fr pulmonary artery catheter introducer sheaths. In that patient, there were no hemodynamic alterations. The same study² showed that a pressure gradient of 4 mmHg causes flows of 90 ml/s, enough to result in fatal venous air embolism.³ Great

* Assistant Professor of Anesthesia.

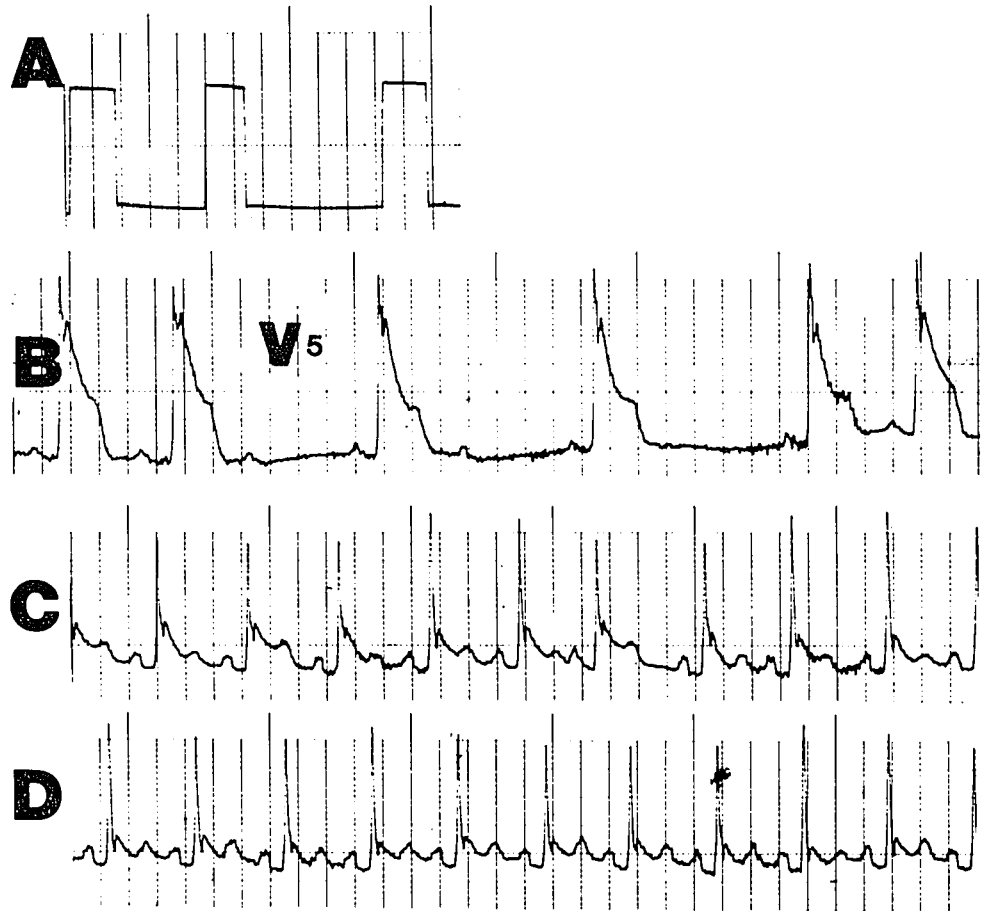
† Assistant Clinical Instructor of Anesthesia.

Received from the Department of Anesthesia, University of Pennsylvania School of Medicine, Philadelphia, Pennsylvania 19104. Accepted for publication August 24, 1981.

Address reprint requests to Dr. Horrow: Department of Anesthesia, Brigham and Women's Hospital, 75 Francis Street, Boston, Massachusetts 02115.

Key words: Embolism: air coronary. Surgery: cardiac.

FIG. 1. ECG recordings during an episode of air entrainment through a CVP catheter. *A.* calibration pulses of 1 mV. *B.* tracing soon after air entered. Lead V_5 demonstrates ST segment elevation of 1 mV and transient second degree AV block. *C.* Two minutes later, ST elevations have decreased to 0.3 mV. *D.* Three minutes after recording B, ST segments approach baseline.



care obviously is needed to prevent air entrainment when inserting large bore introducers.

In particular, dyspneic patients may be unable to execute commands designed to control the respiratory cycle. Patients are confused easily by directions to alter respirations. Meticulous attention to the respiratory pattern during cannulation is essential. It may be preferable to time placement of the catheter or introducer based on these observations without requesting alterations by the patient in his ventilatory pattern. Had this patient been managed so, air embolism probably would not have occurred. When dyspnea is secondary to congestive heart failure with high CVP, a slight amount of head-up tilt or maintenance of a neutral position may prevent exacerbation of the dyspnea while still precluding air entry. In this patient, without congestive failure, head-down tilt was indicated.

Patients with intracardiac shunts present the additional risk of systemic embolism of air or clot during cannulation. We avoided placement of a pulmonary artery catheter in this patient for fear of systemic thromboembolism⁴ and of obliterating pulmonary flow with the catheter. Instead, the 8-Fr sheath was to serve as a conduit for postoperative insertion of a pulmonary artery

catheter, and to secure the 16-gauge CVP cannula intraoperatively.

Treatment of air embolism includes placing the patient in the left lateral decubitus position,⁵ and eliminating nitrogen from the body by administering 100 per cent oxygen. Both of these measures are less useful in the presence of tetralogy of Fallot. In a patient with an overriding aorta, turning the right side up may facilitate air transit from the right ventricle to the aorta. Administration of 100 per cent oxygen will accomplish denitrogenation more slowly in a patient with markedly diminished pulmonary blood flow.

Paradoxical air embolism during neurosurgery has occurred in several patients with patent foramina ovale.⁶ Those patients had no ECG abnormalities despite profound hemodynamic changes. This patient, however, demonstrated marked ST segment elevation (1 mV) soon after air entry. Several facts indicate that these ischemic ECG changes were due to intracoronary air and not merely to pulmonary arterial air embolism with secondary coronary hypoperfusion. First, due to her large right-to-left shunt, blood or air in the right ventricle is more likely to exit via the aorta than the pulmonary artery. The nondependent position of the overriding aorta in-

creases the likelihood of air exiting to it. Second, even though awake and unседated, the patient did not cough during the episode. Third, the hemodynamic difficulties occurred after the ECG began to change. This sequence would be expected if compromise of coronary flow initiated the problem; the alternate sequence occurs during pulmonary embolism. Fourth, such large ST segment elevations occur in patients when air trapped in saphenous vein aortocoronary grafts is forced distally at the termination of cardiopulmonary bypass.⁷ Fifth, coronary insufficiency due to hypotension should begin as ST segment depression, whereas this patient showed ST elevation soon after air entrainment. Fortunately, this patient suffered no CNS sequelae of systemic air embolism.

This case emphasizes the extreme care necessary to prevent air embolism during venous cannulation, especially in dyspneic patients. In patients with intracardiac shunts, air can travel into the coronary arteries, producing marked ST segment elevation and hypotension.

Anesthesiology
56:214-216, 1982

A Correctable Complication of Cardiopulmonary Bypass

CHARLES H. McLESKEY, M.D.,* AND FREDERICK W. CHENEY, M.D.†

The inflow cannula returning oxygenated blood from the pump oxygenator to the patient during cardiopulmonary bypass has been inserted at several anatomic locations, including the subclavian,¹ femoral,² and iliac arteries.³ Currently, the ascending aorta is the most frequently selected anatomic site because of the following advantages: 1) easy access, 2) forward flow, 3) decreased incidence of atheromatous emboli, 4) possibility for in-

sertion of a larger cannula, 5) elimination of the need for a second operative site, and 6) avoidance of ischemia and necrosis of a cannulated extremity.⁴⁻⁷ However, cannula positioning in the ascending aorta is especially critical since inaccurate placement may result in cannula insertion either into or beyond the aortic arch vessels. This report describes a case in which accidental cannulation of the left subclavian artery occurred during cardiopulmonary bypass.

REPORT OF A CASE

A 47-year-old man with a history of two diaphragmatic myocardial infarctions and with severe three-vessel disease demonstrated by coronary angiography was scheduled for coronary artery bypass surgery. He was moderately obese, with blood pressure 100/60 mmHg, heart rate 60 beats/min, weight 93 kg, and height 173 cm.

One hour following premedication with 10 mg morphine sulfate, and 10 mg diazepam, im, intravenous catheters were inserted in each arm and in the superior vena cava; a 20-gauge catheter was inserted into the left radial artery. Arterial and central venous pressure traces were displayed continuously.

Anesthesia was induced with 0.5 mg/kg morphine sulfate, and 0.4 mg/kg diazepam, iv; tracheal intubation was facilitated by 0.1 mg/kg pancuronium, iv. Anesthesia was maintained with 50 per cent nitrous oxide and 0.5-2.0 per cent halothane (inspired) in oxygen. The patient

* Resident, Department of Anesthesiology and the Anesthesia Research Center. Currently Assistant Professor, Department of Anesthesia, Bowman Gray School of Medicine.

† Professor, Department of Anesthesiology and the Anesthesia Research Center.

Received from the University of Washington Hospital, Seattle, Washington. Accepted for publication August 26, 1981. All correspondence should be directed to Dr. McLeskey, whose current title and address are Assistant Professor, Department of Anesthesia, Bowman Gray School of Medicine, 300 S. Hawthorne Road, Winston-Salem, North Carolina 27103.

Address reprint requests to Dr. McLeskey: Department of Anesthesia, Bowman Gray School of Medicine, 300 S. Hawthorne Road, Winston-Salem, North Carolina 27103.

Key words: Surgery: cardiac; cardiopulmonary bypass. Monitoring: blood pressure.