

creases the likelihood of air exiting to it. Second, even though awake and unsedated, the patient did not cough during the episode. Third, the hemodynamic difficulties occurred after the ECG began to change. This sequence would be expected if compromise of coronary flow initiated the problem; the alternate sequence occurs during pulmonary embolism. Fourth, such large ST segment elevations occur in patients when air trapped in saphenous vein aortocoronary grafts is forced distally at the termination of cardiopulmonary bypass.<sup>7</sup> Fifth, coronary insufficiency due to hypotension should begin as ST segment depression, whereas this patient showed ST elevation soon after air entrainment. Fortunately, this patient suffered no CNS sequelae of systemic air embolism.

This case emphasizes the extreme care necessary to prevent air embolism during venous cannulation, especially in dyspneic patients. In patients with intracardiac shunts, air can travel into the coronary arteries, producing marked ST segment elevation and hypotension.

Anesthesiology  
56:214-216, 1982

## A Correctable Complication of Cardiopulmonary Bypass

CHARLES H. McLESKEY, M.D.,\* AND FREDERICK W. CHENEY, M.D.†

The inflow cannula returning oxygenated blood from the pump oxygenator to the patient during cardiopulmonary bypass has been inserted at several anatomic locations, including the subclavian,<sup>1</sup> femoral,<sup>2</sup> and iliac arteries.<sup>3</sup> Currently, the ascending aorta is the most frequently selected anatomic site because of the following advantages: 1) easy access, 2) forward flow, 3) decreased incidence of atheromatous emboli, 4) possibility for in-

sertion of a larger cannula, 5) elimination of the need for a second operative site, and 6) avoidance of ischemia and necrosis of a cannulated extremity.<sup>4-7</sup> However, cannula positioning in the ascending aorta is especially critical since inaccurate placement may result in cannula insertion either into or beyond the aortic arch vessels. This report describes a case in which accidental cannulation of the left subclavian artery occurred during cardiopulmonary bypass.

### REPORT OF A CASE

A 47-year-old man with a history of two diaphragmatic myocardial infarctions and with severe three-vessel disease demonstrated by coronary angiography was scheduled for coronary artery bypass surgery. He was moderately obese, with blood pressure 100/60 mmHg, heart rate 60 beats/min, weight 93 kg, and height 173 cm.

One hour following premedication with 10 mg morphine sulfate, and 10 mg diazepam, im, intravenous catheters were inserted in each arm and in the superior vena cava; a 20-gauge catheter was inserted into the left radial artery. Arterial and central venous pressure traces were displayed continuously.

Anesthesia was induced with 0.5 mg/kg morphine sulfate, and 0.4 mg/kg diazepam, iv; tracheal intubation was facilitated by 0.1 mg/kg pancuronium, iv. Anesthesia was maintained with 50 per cent nitrous oxide and 0.5-2.0 per cent halothane (inspired) in oxygen. The patient

\* Resident, Department of Anesthesiology and the Anesthesia Research Center. Currently Assistant Professor, Department of Anesthesia, Bowman Gray School of Medicine.

† Professor, Department of Anesthesiology and the Anesthesia Research Center.

Received from the University of Washington Hospital, Seattle, Washington. Accepted for publication August 26, 1981. All correspondence should be directed to Dr. McLeskey, whose current title and address are Assistant Professor, Department of Anesthesia, Bowman Gray School of Medicine, 300 S. Hawthorne Road, Winston-Salem, North Carolina 27103.

Address reprint requests to Dr. McLeskey: Department of Anesthesia, Bowman Gray School of Medicine, 300 S. Hawthorne Road, Winston-Salem, North Carolina 27103.

Key words: Surgery: cardiac; cardiopulmonary bypass. Monitoring: blood pressure.

was in the supine position, with his arms placed at his sides. The ascending aorta was identified through a median sternotomy incision, and following systemic heparinization it was cannulated, using a USCI† rattail, arterial-perfusion cannula with a single 6.0-mm ID distal beveled lumen. The right atrium was cannulated, using a single Sarns§ 51-Fr venous cannula. A Sarns 5000 pump was used for cardiopulmonary bypass. Pump prime was 20 ml/kg lactated Ringer's solution and 5 ml/kg 20 per cent mannitol; the pump flow was 2.4  $l \cdot min^{-1} \cdot m^{-2}$  body surface area. Gas flow through the bubble oxygenator was 2 per cent halothane and 3 per cent  $CO_2$  in 7.7  $l/min O_2$ .

Immediately after beginning full bypass, a sudden increase in mean arterial blood pressure from 95 to 110 mmHg was recorded from the left radial artery catheter. In addition, pressure waves with a 40 mmHg pulse pressure were seen to coincide with the roller movement of the pump. Incorrect cannula positioning was considered and the perfusionist was consulted but measured no abnormal line pressures in the pump. Recalibration of the strain gauge confirmed that the recorded arterial pressure was correct. To treat the hypertension, the halothane concentration in the bubble oxygenator was increased to 3 per cent. After one hour of full bypass, despite a mean left radial artery pressure of 100 mmHg, aortic palpation suggested a very low systemic perfusion pressure. No other extremity was available for confirmation of the blood pressure. The pupils were mid-size and nonreactive to light; urine output had been 155 ml during the first hour of bypass ( $1.7 ml \cdot kg^{-1} \cdot h^{-1}$ ). Because the adequacy of systemic perfusion was in question, halothane was discontinued immediately and intravenous fluids rapidly administered, which resulted in a gradual increase in the mean left radial artery pressure to 160 mmHg. Malposition of the aortic cannula was again suspected; therefore, it was slowly withdrawn 3 cm, which resulted in a sudden lowering of the mean arterial pressure from 160 to 105 mmHg, with immediate loss of the wide-swinging pressure waves (fig. 1). Halothane was reinstated, and surgery was completed without further complication. Total cardiopulmonary bypass time was 2 h; aortic cross-clamp time was 20 min. After the patient was rewarmed and the heart defibrillated, weaning from cardiopulmonary bypass was accomplished without difficulty. Subsequently, the pupils became progressively smaller, and urinary output increased.

Postoperatively, blood pressure and urine output were well-maintained, and no significant ECG changes occurred. The only abnormal CNS sign was a 3-hour period of combativeness on the first postoperative day.

### DISCUSSION

This complication was due to accidental cannulation of the left subclavian artery by the infusion cannula. This produced markedly increased perfusion of the left arm, resulting in a high mean pressure and wide-swinging pressure waves recorded from the left radial artery catheter (fig. 1), despite probable systemic hypoperfusion. Renal and cerebral hypoperfusion may have resulted, as demonstrated by unusually low urine output and mid-size, nonreactive pupils during bypass. However, the lack of postoperative CNS sequelae and the production of some urine during bypass indicate that at least minimal systemic perfusion was present during this time.

Despite the advantages of the ascending aorta for insertion of the inflow cannula for cardiopulmonary by-

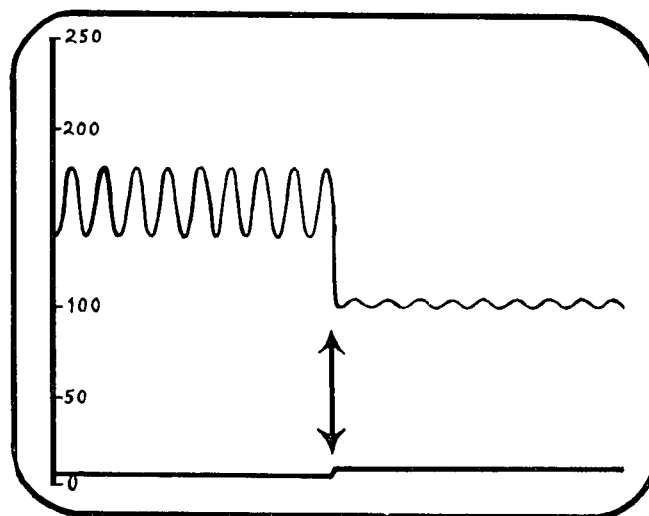


FIG. 1. A drawing of left radial arterial pressure (upper trace) and central venous pressure (lower trace) as displayed on a monitor. Initially, mean arterial pressure was 160 mmHg with wide-swinging, rapid pressure waves of 40 mmHg magnitude coinciding with the roller movement of the pump. The vertical arrows represent the point at which the aortic perfusion cannula was withdrawn 3 cm. Note that with repositioning of the cannula, the mean recorded arterial pressure abruptly decreased to 105 mmHg, with simultaneous termination of the wide-swinging pressure waves.

pass, significant complications unique to this site result from the fact that cannula positioning is extremely critical. The cannula may be inserted retrograde accidentally, with flow directed toward the aortic valve resulting in impeded systemic perfusion and marked ventricular distention on initiation of cardiopulmonary bypass.<sup>8</sup> If the cannula is advanced too far in the aorta, it may extend either beyond or into the arch vessels. Should the cannula tip lie distal to the arch vessels, decreased perfusion of the cerebral and coronary vessels may occur as a result of either blockage of the ostia of the vessels by the cannula itself or reduced pressure behind a jet stream (Bernoulli effect<sup>9</sup>). Should the cannula extend into the innominate or left common carotid artery, cerebral hemorrhage may result from the great pressures developed in these vessels during cardiopulmonary bypass.<sup>10-12</sup> Finally, as reported in this paper, the cannula may be inserted accidentally into the left subclavian artery. This complication has been reported only once previously. In that case, Magner<sup>6</sup> noted similar wide-swinging pressure waves on a left radial artery trace; however, as would be expected, increased pressure in the perfusion line of the pump was noted. In our patient, surprisingly, no pressure increase was observed by the perfusionist. This was possible only if the perfusion cannula did not completely occlude the ostium of the left subclavian artery, or if the resistance to outflow of the subclavian artery was not great enough to cause a pressure rise in the pump with the bypass flows used.

† USCI, Bellerica, Massachusetts.

§ Sarns Company, Ann Arbor, Michigan.

Malplacement of the aortic perfusion cannula is an infrequent, but potentially catastrophic problem, and must be detected immediately. To prevent occurrences similar to the one outlined above, we recommend that the anesthetist carefully observe insertion of the perfusion cannula by the surgeon, who should palpate the tip of the cannula prior to beginning cardiopulmonary bypass. If a flexible aortic inflow cannula is used, it should be advanced no farther than 2 cm into the aorta through a low aortotomy site, if possible. Newer Sarns cannulae are manufactured with only 2 cm of cannula extending beyond an enlarged flange or shoulder. This limits cannula insertion to 2 cm, making cannulation of the aortic arch vessels less likely. After beginning cardiopulmonary bypass, the quality of the arterial pulse should be observed. Any aberration from the normal drop in blood pressure immediately following the initiation of cardiopulmonary bypass should arouse suspicion of cannula malplacement. The head and the eyes of the patient should be monitored for venous or arterial distention, and urine output recorded. In addition, monitoring nasopharyngeal temperature may have advantage, since this determination most closely estimates brain temperature and allows a semi-quantitative assessment of the adequacy of brain perfusion during the initial cooling produced by cardiopulmonary bypass. Finally, abnormal pressure in the perfusion cannula during bypass suggests cannulation of one of the arch vessels or some other cause for outflow obstruction.

Cannula positioning is especially critical when the ascending aorta is selected as the site for insertion of the arterial perfusion cannula returning oxygenated blood from the pump to the patient during cardiopulmonary

bypass. Our case was one in which the cannula was inserted too far into the aorta, resulting in cannulation of the left subclavian artery, with near-disastrous results.

#### ACKNOWLEDGMENTS

The authors thank William F. Grancy, M.D., for preparation of the illustration.

#### REFERENCES

1. Warden HE, Cohen EM, Read RC, et al: Controlled cross circulation for open intracardiac surgery. *J Thorac Surg* 28:331-341, 1954
2. Lillehei CS, Cordozo RH: Use of median sternotomy with femoral artery cannulation in open cardiac surgery. *Surg Gynecol Obstet* 108:707-714, 1959
3. Kirklin JW, Lyone WS: Arterial cannulation for extracorporeal circulation utilizing the external or common iliac artery. *Surgery* 47:648-650, 1960
4. Nuñez LE, Bailey CP: New method for systemic arterial perfusion in extracorporeal circulation. *J Thorac Surg* 37:707-710, 1959
5. Dewall RA, Levy MJ: Direct cannulation of the ascending aorta for open heart surgery. *J Thorac Cardiovasc Surg* 45:496-499, 1963
6. Magner JB: Complications of aortic cannulation for open heart surgery. *Thorax* 26:172-173, 1971
7. Flick WF, Hallermann FJ, Feldt RH, et al: Aneurysm of aortic cannulation site. *J Thorac Cardiovasc Surg* 61:419-423, 1971
8. Taylor PC, Effer DB: Management of cannulation for cardiopulmonary bypass in patients with adult acquired heart disease. *Surg Clin North Am* 55:1205-1215, 1975
9. Magilligan DJ, Eastland MW, Lell WA, et al: Decreased carotid flow with ascending aortic cannulation. *Circulation* 45-46 (Suppl 1):1130-1133, 1972
10. Kulkarni MG: A complication of aortic cannulation. *J Cardiovasc Surg* 9:207-208, 1968
11. Krous HF, Mansfield PB, Sauvage LR: Carotid hyperperfusion during open heart surgery. *J Thorac Cardiovasc Surg* 66:118-121, 1973
12. Ross WT, Lake CL, Wellons HA: Cardiopulmonary bypass complicated by inadvertent carotid cannulation. *ANESTHESIOLOGY* 54:85-86, 1981