

Extremity Amputation Following Radial Artery Cannulation in a Patient with Hyperlipoproteinemia Type V

B. W. CANNON, D.O.,* AND W. T. MESHIER, M.D.†

Indwelling arterial catheters can lead to thrombosis and tissue necrosis. We recently faced this complication associated with severe pain in a woman with hemorrhagic pancreatitis and shock due to uncontrolled Type V hyperlipoproteinemia.

REPORT OF A CASE

A 44-year-old 111-kg woman presented to our Emergency Room with a chief complaint of chest pains complicated by dyspnea. Her past history included coronary artery disease, diabetes mellitus, and Type V hyperlipoproteinemia. Her hyperlipoproteinemia was poorly controlled (triglycerides greater than 2,000 mg/dl) due to her poor compliance with diet. The presumptive diagnosis was myocardial infarction. Her arterial blood pressure was 146/82 mmHg and heart rate 120 beats/min. ECG revealed sinus tachycardia with marked ST depression in the anterior chest suggestive of ischemia. Increasing abdominal pain, falling blood pressure, and a rising heart rate and hematocrit led to the re-diagnosis of pancreatitis. Following the intravenous infusion of 0.9 per cent saline, dopamine (up to $10 \mu\text{g} \cdot \text{kg}^{-1} \cdot \text{min}^{-1}$) was given iv, progressing to a combination with dobutamine in an attempt to restore adequate blood pressure. An Allen's test demonstrated palmar filling alternately via the ulnar and radial arteries in less than 3 seconds, and a 20-gauge arterial catheter was inserted percutaneously into the left radial artery following multiple attempts. A repeat glucose level was 700 mg/dl; an insulin infusion was begun. Soon after insertion of the arterial line, the left hand was noted to be cool and mildly cyanotic. At that time blood pressure was 95/55 mmHg. Insertion of a femoral arterial catheter permitted removal of the radial catheter; however, the hand remained cool, cyanotic, and extremely painful. Analgesia and sympathetic blockade for the extremity was attempted by blocking the left stellate ganglion using 0.25 per cent bupivacaine injected by the paratracheal approach. Although proximal sympathetic blockade was noted, analgesia and distal sympathetic blockade was not successful.

Analgesia was then provided by intermittent 40 ml injections of either 2 per cent 2-chloroprocaine or 0.5 per cent bupivacaine injected

through a percutaneous axillary catheter into the brachial plexus sheath using the technique of Selander.¹ When subjective pain reappeared, 30 ml 0.5 per cent bupivacaine was injected which produced prompt onset of analgesia and a partial motor block verifying the location of the catheter still within the neurovascular sheath.

This catheter remained in place for four days, requiring approximately 3-4 injections per 24-hour period. We alternated bupivacaine and a 2-chloroprocaine to avoid the possible appearance of tachyphylaxis. Good pain control was achieved, resulting in improved psychological state, improved patient cooperation, and minimal narcotic requirement.

In contrast with the successful pain management, persistent and well-demarcated cyanosis and gangrene of the wrist and forearm (fig. 1), prompted a below the elbow amputation on the twenty-fifth day of her hospitalization. The hospital course was further complicated by pancreatic pseudocyst formation, its resolution, chronic abdominal pain and narcotic dependency. One year after admission her weight was 55 kg. She is now pain-free and taking no medications. Her metabolic abnormalities are limited to a triglyceride level of 456 mg/dl.

DISCUSSION

Golbranson *et al.* described four cases which required amputation of extremities which followed dopamine infusion used for vascular support.² Dobutamine has not been reported to contribute to thrombosis and tissue necrosis. In 1975 Luscher found that increases in fatty acids increased thrombosis and platelet aggregation.³ Decreased capillary perfusion can result in sludging which also predisposes to thrombosis.⁴ This problem, worsened by an increasing osmotic pressure seen with hyperglycemia, can also accentuate the tendency to arterial occlusion. Presumably our patient was at significant increased risk for thrombosis due to: 1) indwelling arterial catheter, 2) use of dopamine, 3) hypertriglycerides, 4) serum hyperosmolarity, 5) capillary sludging, and 6) hypovolemic state. Although an Allen's test performed prior to catheter placement, revealed adequate collateral blood flow, the coolness of the hand soon after placement of the catheter gave clinical evidence of diminished perfusion. Due to the life-threatening situation requiring continuous arterial pressure monitoring, the radial arterial line was not removed immediately. Rather, an alternative site was located and a new catheter was placed into the femoral artery. The total time of indwelling radial catheter was approximately 2 hours.

Catheter placement for pain management in this case followed Selander's guidelines. He uses a catheter for axillary blocks to achieve operative anesthesia.¹ His

* Resident Anesthesiologist; Lieutenant, Medical Corps, U. S. Naval Reserve.

† Staff Anesthesiologist; Lieutenant Commander, Medical Corps, U. S. Naval Reserve.

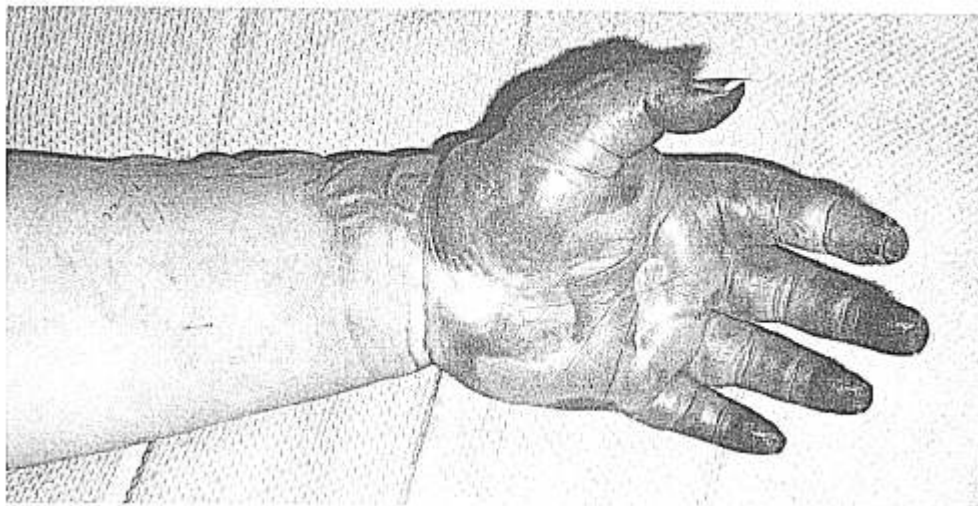
Received from the Department of Anesthesiology, Naval Regional Medical Center, Oakland, California 94627. Accepted for publication September 1, 1981.

The opinions and assertions contained herein are those of the authors and are not to be construed as official or as reflecting the views of the Navy Department or the naval service at large.

Address reprint requests to Dr. Meshier: Department of Anesthesiology, Naval Regional Medical Center, Oakland, California 94627.

Key words: Arteries: radial. Complications: amputation, gangrene, thrombosis. Equipment: catheters, arterial.

FIG. 1. Palmar view of left hand. This picture taken 11 days after arterial cannulation demonstrates edema, distal digital gangrene and bulous formations.



stated advantages included the possibility of a continuous block by repeated injections via a very stable access route. The value of this simple approach permitted a pain-free interval during the critical initial days of our patient's care.

We believe this case illustrates two problems. First, a radial vessel must be considered less optimal as an intra-arterial catheter site than a large lumen vessel when the risk of thrombosis is high. Second, for situations requiring continuous sympathetic blockade and analgesia, our percutaneous technique offers the anesthesiologist an attractive alternative to repetitive needle injection techniques.

ACKNOWLEDGMENT

The authors acknowledge the assistance of CAPT Stephen B. Lewis for his assistance in preparation of this manuscript.

REFERENCES

1. Selander D: Catheter technique in axillary plexus block. *Acta Anesth Scand* 21:324-329, 1977
2. Golbranson FL: Multiple extremity amputations in hypotensive patients treated with dopamine. *JAMA* 243:1145-1146, 1980
3. Luscher EF: The effects of lipids and fatty acids on blood coagulation and platelets in relation to thrombosis. *Advances in Experimental Medicine and Biology* Vol 60, 1975, pp 107-118
4. Vaughn PB: Local cold injury-menace to military operations: A review. *Military Medicine* Vol 145, May 1980, pp 305-311