

Anesthesiology  
56:229-230, 1982

## Airway Obstruction after Nasal-Tracheal Intubation

DEREK GLINSMAN, R.R.T.,\* AND EDWARD G. PAVLIN, M.D.†

Obstruction of an endotracheal tube may occur for several reasons. Published reports include descriptions of compression of the tube by an inflated cuff,<sup>1</sup> herniation of the cuff over the end of the tube,<sup>2</sup> and retropharyngeal dissection by the nasotracheal tube and foreign material plugging of the tube's lumen.<sup>2</sup> We present a cause of obstruction following nasotracheal intubation utilizing an Endotrol™ tube.

### REPORT OF A CASE

A 53-year-old man had been discharged from the hospital for 24 hours following surgical treatment of traumatic facial fractures when an altercation led to further facial trauma and readmission for surgical management. Posterior pharyngeal swelling and the need for surgical intervention required the insertion of a nasotracheal tube. Blind awake nasotracheal intubation was attempted with a conventional 7-mm ID high-volume cuffed tube, but this was not successful. A second attempt was performed utilizing a #7 Endotrol™ tube. The design includes a pull ring at the opening of the tube which, when pulled, increases the tube's arc. This feature allowed greater control of the tip of the tube and resulted in a successful endotracheal intubation.

Although breath sounds were heard bilaterally, some obstruction to airflow appeared to be present. A suction catheter inserted down the tube failed to go beyond the tip. Deflating the cuff did not appear to remedy the situation. A chest roentgenogram (fig. 1) revealed the severe arcing of the tube within the trachea. We then discovered that, in the placement of the nasotracheal tube, the pull ring had been inserted into the nares creating tension on the pull wire and bringing the tip of the tube against the tracheal wall. Cutting the pull ring from the wire alleviated the tension and the airway obstruction allowing for a proper positioning of the tube and cuff in the trachea.

### DISCUSSION

With nasotracheal intubation, the Endotrol™ tube allows for altering the arc of the tube via a wire from a pull ring to the tip (fig. 2). Upon discovering the resistance to ventilation, various causes of endotracheal tube obstruction were considered but not until examination of the chest roentgenogram was the problem unique to this particular nasotracheal tube revealed.

\* Registered Respiratory Therapist.

† Associate Professor of Anesthesiology.

Received from the Departments of Respiratory Therapy and Anesthesiology, Harborview Medical Center, University of Washington School of Medicine. Accepted for publication September 8, 1981.

Address reprint requests to Dr. Edward G. Pavlin, Associate Professor of Anesthesiology, ZA-14, Harborview Medical Center, 325 9th Avenue, Seattle, Washington 98104.

Key words: Equipment: tubes, nasotracheal, Endotrol™. Airway: obstruction.

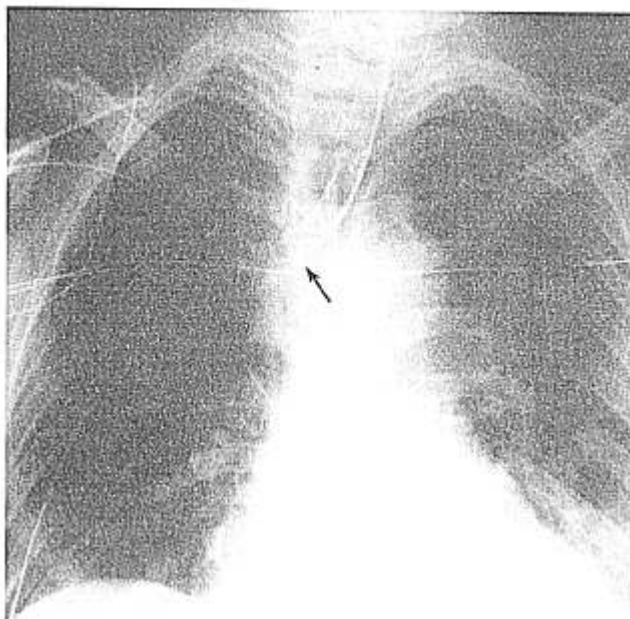


FIG. 1. Chest roentgenogram after successful nasotracheal intubation with the Endotrol™ tube. Note the severe arcing of the tube within the trachea.

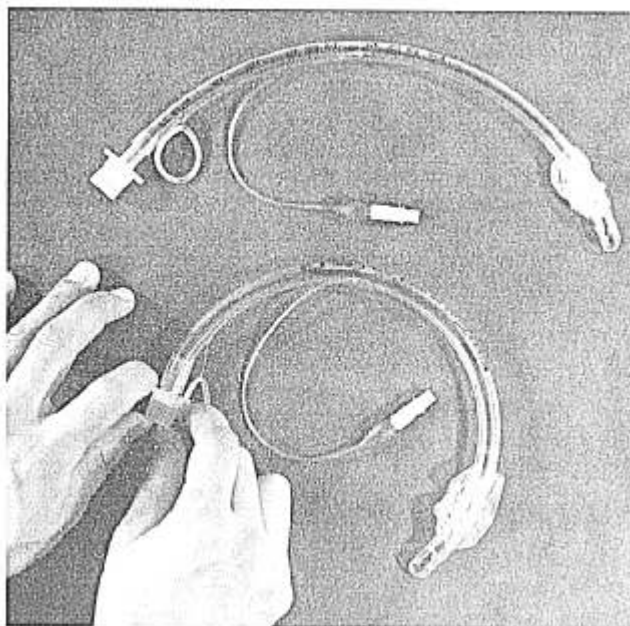


FIG. 2. The Endotrol™ nasotracheal tube. Traction on the pull ring results in anterior displacement of the tip.

Obviously, severing the wire from the pull ring resulted in relieving this displacement.

We recommend the routine cutting of the pull ring from the wire in this type of endotracheal tube following successful nasotracheal intubation to prevent this complication.

Anesthesiology  
56:230-232, 1982

## REFERENCES

1. Kefouer AK, Feingold A: Collapse of a disposable endotracheal tube by its high pressure cuff. *ANESTHESIOLOGY* 43:108-110, 1975
2. Kemmotsu O: Six cases of endotracheal tube obstructions. *Jpn J Anesthesiol* 20:259-264, 1971

## Long-acting Local Anesthetic Drugs and Convulsions with Hypoxia and Acidosis

DANIEL C. MOORE, M.D.,\* GALE E. THOMPSON, M.D.,\* ROBERT D. CRAWFORD, M.D.\*

Albright theorizes that, "The newer local anesthetic agents (bupivacaine, etidocaine) may result in almost simultaneous seizures and cardiovascular collapse without antecedent hypoxia from typical clinical doses administered inadvertently intravenously."<sup>1</sup> Conversely, we reported two cases of severe hypoxia and acidosis occurring prior to or concomitantly with convulsions and proposed that any delay in the proper treatment of associated hypoxia and acidosis can trigger cardiac arrest.<sup>2,3</sup>

We believe the following four cases of bupivacaine-induced convulsions with concomitant hypoxia and acidosis without cardiac arrest eliminates conjecture from our proposal.

### REPORTS OF FOUR CASES

All patients were female, aged 40-60 years, and weighed 53-79 kg. The specific details of each case are summarized in table 1. These cases had the following similarities. No patient was given a test dose. In all four cases, the required dose contained epinephrine. The convulsions occurred within two minutes of the injection in three of the patients who received single-injection epidural blocks through 19-gauge Quincke spinal needles, and 10 min after completion of an intercostal nerve block in the other patient. All had hypoxia and/or acidosis. Patient 2 had only respiratory acidosis, but others had both a respiratory and metabolic component. Patient 4 had the most severe acidosis initially being both respiratory and metabolic, while later only being metabolic acidosis. Within 15 s of the onset of the convulsions, all were ventilated with 100 per cent oxygen via bag and mask. Endotracheal intubation was not performed in any patient. After adequate ventilation had been

instituted, appropriate drugs were administered. None of the patients had evidence of cardiotoxicity as indicated by changes in blood pressure or heart rate. In Patient 2 the electrocardiogram showed that her heart rate almost doubled during the convulsion and that postictally it approximated the control rate. Furthermore, on recovery from anesthesia none had any sequelae.

Interestingly, all of the patients had sensory analgesia adequate for the operative procedure. In the first patient, the systemic toxic reaction was judged to be from absorption and, therefore, analgesia was expected. Conversely, in the other patients the reactions appeared to result from unintentional intravascular injections. Evidently, in these cases a relatively small intravascular volume of the drug triggered the reaction and the rest remained in the epidural space. Only in Patients 2 and 4 were arterial plasma levels of bupivacaine obtained which were low and thus confirms only a small volume was injected intravascularly. Patients 2 and 3 received 10 mg diazepam, po, for premedication approximately 45 min prior to the completion of the blocks, and still had convulsions.<sup>4</sup>

After recovering from the convulsions and being oriented as to time, place, and person, Patients 1, 2, and 3 underwent surgery. For 2-6 hours following surgery, they were pain-free. The surgery for Patient 4 was canceled and performed the next day under general anesthesia. None had any sequelae from the convulsions.

### DISCUSSION

Our experience from 1968 through 1980 with bupivacaine includes 20,748 regional blocks. Of these, 5,277 were intercostal nerve blocks, most of them bilateral, for surgical procedures using 290-400 mg bupivacaine in concentrations ranging from 0.375 to 0.5 per cent, with a final epinephrine content of 1:320,000 to 1:400,000. Another 11,839 were epidural blocks (7,393 lumbar, and 4,446 caudal), most with a final epinephrine content of 1:200,000. No cardiac arrests have followed the 28 convulsions from bupivacaine (25 epidural and 3 intercostal nerve). These experiences plus the now six documented cases of hypoxia and acidosis which occurred concomitantly with convulsions do not support Albright's pro-

\* Staff Anesthesiologists.

Received from the Department of Anesthesiology, the Mason Clinic, P.O. Box 900, Seattle, Washington 98111. Accepted for publication September 8, 1981.

Address reprint requests to Dr. Moore.

Key words: Anesthetics, local: bupivacaine; etidocaine. Toxicity: convulsions, cardiac.