

4. Glynn CJ, Mather LE, Cousins MJ, et al: Spinal narcotics and respiratory depression. *Lancet* 2:356-357, 1979
5. Onofrio BM, Yaksh TL, Arnold PG: Continuous low-dose intrathecal morphine administration in the treatment of chronic pain of malignant origin. *Mayo Clin Proc* 56:516-520, 1981
6. Coombs DW, Rizor R: Technique for continuous silastic epidural conduit placement. *Regional Anesthesia* 6:112-116, 1981
7. Baskoff JD, Watson RL, Muldoon SM: Respiratory arrest after intrathecal morphine. *Anesth Rev* 7:12-15, 1980
8. Stephen O'Dell: Personal communication. A.H. Robins Co., Richmond, VA, 1981
9. Scott J, Huskisson EC: Graphic representation of pain. *Pain* 2:175-184, 1976
10. Zung W: A self-rating depression scale. *Arch Gen Psychiatry* 12:63-70, 1965
11. Asari H, Inone K, Shibata T, et al: Segmental effects of morphine injected into the epidural space in man. *ANESTHESIOLOGY* 54:75-77, 1981

Anesthesiology  
56:473-476, 1982

## Relationship of Alveolar-Arterial Oxygen Tension Difference in Diaphragmatic Hernia of the Newborn

JEAN HARRINGTON, M.D.,\* RUSSELL C. RAPHAELY, M.D.,† JOHN J. DOWNES, M.D.‡

In congenital diaphragmatic hernia of the newborn, pulmonary hypoplasia and persistent fetal circulation cause acidosis, hypercapnia, and hypoxemia.<sup>1-5</sup> The magnitude of the cardiopulmonary shunt, as indicated by the alveolar-arterial oxygen tension difference (A-aD<sub>O<sub>2</sub></sub>) at an inspired oxygen concentration of 100 per cent (FI<sub>O<sub>2</sub></sub> 1.00), usually decreases immediately following reduction of the hernia. Preliminary data suggested that the A-aD<sub>O<sub>2</sub></sub> at that time may be an accurate predictor of ultimate outcome.<sup>5</sup> If this is true, the A-aD<sub>O<sub>2</sub></sub> then may identify those infants at greatest risk of respiratory failure following anesthesia and operation.

### METHODS

To delineate the relationship of the A-aD<sub>O<sub>2</sub></sub> to survival, we prospectively studied 39 newborns with diaphragmatic hernia. Prior to and during anesthesia and oper-

ation we treated the infant's acidemia and hypoxemia with: (1) tracheal intubation, (2) manually controlled hyperventilation at frequencies of 40 to 60 breaths per min and peak inspiratory pressures of 25 to 40 cmH<sub>2</sub>O in an effort to achieve a PaCO<sub>2</sub> of 25 to 30 mmHg, and (3) intermittent intravenous sodium bicarbonate in doses estimated to restore arterial pH to 7.40. In an effort to minimize barotrauma, we limited peak inspiratory pressures to 40 cmH<sub>2</sub>O. Despite these efforts, asphyxia of varying degrees persisted prior to hernia reduction. Under general anesthesia with neuromuscular blockade, at an FI<sub>O<sub>2</sub></sub> of 1.00, blood samples were obtained immediately before and after reduction of the hernia. The A-aD<sub>O<sub>2</sub></sub> was derived in the conventional manner.<sup>6</sup> Samples were collected from indwelling arterial catheters into heparinized syringes, iced, and analyzed within minutes for pH and blood-gas tensions on an Instrumentation Laboratories 113 or 213 System. All values were corrected for temperature, and pH values were converted to hydrogen ion concentrations (cH) for statistical analysis. Mean values were compared using the conventional student *t* test for differences.

We were concerned with the influence of the arterial sampling site on the A-aD<sub>O<sub>2</sub></sub>. Shunting through the ductus arteriosus could contaminate systemic arterial blood with pulmonary arterial blood, and has been observed in infants with diaphragmatic hernia.<sup>7</sup> Therefore, we analyzed the effect of the sampling site on gas tensions after reduction of the hernia by comparing values obtained from infants whose right radial or temporal artery were sampled with those infants whose umbilical artery was sampled.

\* Fellow in Pediatric Anesthesia and Critical Care, The Children's Hospital of Philadelphia and the University of Pennsylvania.

† Associate Professor of Anesthesia and Pediatrics, University of Pennsylvania School of Medicine.

‡ Professor of Anesthesia and Pediatrics, University of Pennsylvania School of Medicine.

Received from the Department of Anesthesia and Critical Care, The Children's Hospital of Philadelphia and the University of Pennsylvania. Accepted for publication December 8, 1981.

Address reprint requests to Dr. John J. Downes, Department of Anesthesia, The Children's Hospital of Philadelphia, One Children's Center, 34th Street and Civic Center Boulevard, Philadelphia, Pennsylvania 19104.

Key words: Surgery: pediatric, congenital diaphragmatic hernia. Ventilation: oxygen tension (gradients), shunting.

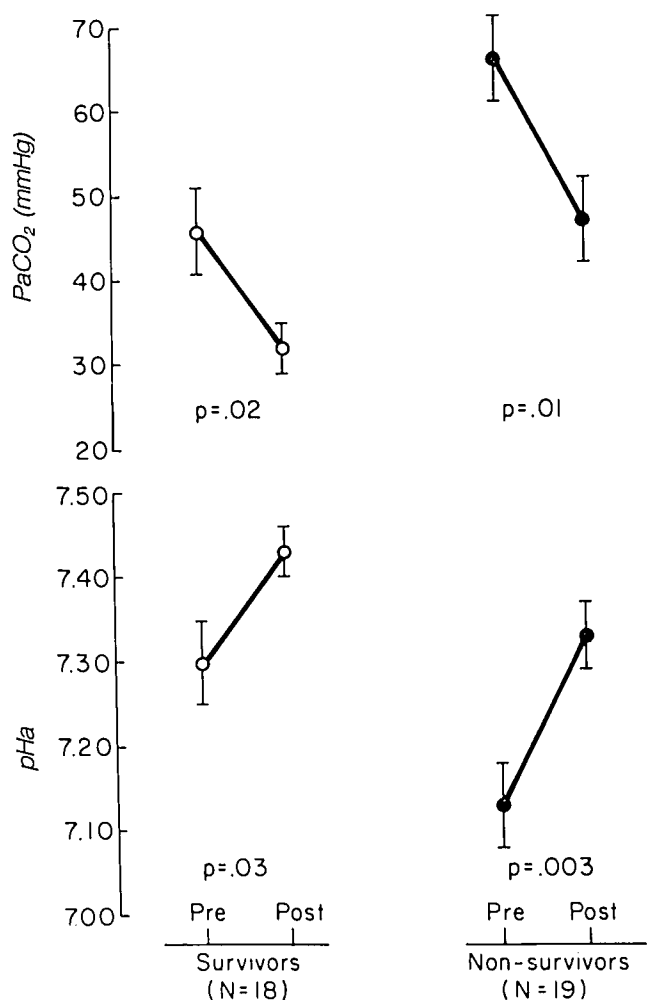


FIG. 1. Mean ( $\pm$ SE) arterial pH and PaCO<sub>2</sub> before and after reduction of the hernia in surviving and non-surviving newborns with diaphragmatic hernia.

## RESULTS

The 18 survivors and 21 non-surviving infants had comparable mean ( $\pm$  SE) birthweight ( $3.31 \pm 0.02$ ,  $2.88 \pm 0.14$  kg) and ages at operation  $10.8 \pm 2.1$ ,  $8.4 \pm 2.1$  h). Two non-surviving infants were not included in the data analysis of figures 1 and 2 because one had trisomy -13 and severe cardiac anomalies and the other survived for two years with bronchopulmonary dysplasia before succumbing. Non-surviving infants were significantly more acidotic than survivors (fig. 1), more hypercapnic (fig. 1), and had a lower mean PaO<sub>2</sub> at FI<sub>02</sub> 1.00 (fig. 2). Immediately following reduction of the hernia, mean arterial pH rose in non-survivors to a mean 7.33, significantly lower than the mean of 7.43 in survivors (fig. 1). This was associated with a decrease in mean PaCO<sub>2</sub> in non-survivors to 47 mmHg, significantly higher than the 32 mmHg observed in survivors. How-

ever, the rise in mean pH and fall in mean PaCO<sub>2</sub> after hernia reduction were significant in both groups (fig. 1).

The mean PaO<sub>2</sub> in survivors rose significantly, whereas an insignificant improvement in mean PaO<sub>2</sub> occurred in non-survivors (fig. 2). Although the response of PaO<sub>2</sub> following reduction of the hernia was strikingly different in survivors and non-survivors, the PaO<sub>2</sub> value may be altered by the PaCO<sub>2</sub>. This arterial oxygenation can be more precisely assessed by examining the A-aDO<sub>2</sub> at FI<sub>02</sub> 1.00. In surviving infants, the post-reduction mean A-aDO<sub>2</sub> of 319 mmHg was significantly less ( $P < 0.001$ ) than the 562 mmHg observed in the non-surviving infants (fig. 3). All of the non-surviving infants had a post-reduction A-aDO<sub>2</sub> greater than 400 mmHg with the exception of two patients mentioned previously: one infant with trisomy-13 and severe cardiac anomalies; another infant who survived for two years with bronchopulmonary dysplasia before succumbing (fig. 3). All survivors had an A-aDO<sub>2</sub> less than 500 mmHg. An A-aDO<sub>2</sub> between 400 and 500 mmHg represented a zone of uncertain prognosis.

We analyzed the effect of sampling sites on the post-reduction A-aDO<sub>2</sub>. When survivors' and non-survivors' data were pooled, no significant difference in mean post-reduction A-aDO<sub>2</sub> values from above ( $407 \pm 42$ ) vs. below ( $468 \pm 33$ ) the ductus could be shown. In surviving infants the mean ( $\pm$ SE) A-aDO<sub>2</sub> of  $309 (\pm 23)$  mmHg ( $N = 7$ ) sampled from the umbilical artery was not significantly greater than the  $247 (\pm 74)$  mmHg ( $n = 11$ ) from above the ductus. In non-surviving infants the opposite trend was observed, the mean A-aDO<sub>2</sub> of  $551 \pm 48$  mmHg ( $N = 7$ ) above the ductus being slightly, but not

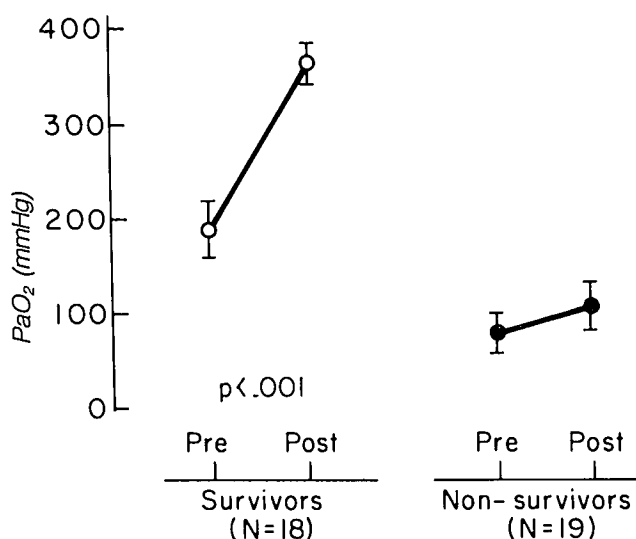


FIG. 2. Mean ( $\pm$ SE) PaO<sub>2</sub> at FI<sub>02</sub> 1.00 before and after reduction of the hernia in surviving and non-surviving newborns with diaphragmatic hernia.

significantly, larger than the 537 ( $\pm 33$ ) mmHg ( $N = 14$ ) sampled below the ductus. We conclude that, in this study, sampling site did not affect significantly the mean A-aD<sub>O<sub>2</sub></sub> data.

### DISCUSSION

Pulmonary hypoplasia previously has been considered the major factor in the mortality of infants with diaphragmatic hernia.<sup>8,9</sup> Recent observations in the fetal lamb model of diaphragmatic hernia<sup>10,11</sup> and in the human newborn indicate that high pulmonary vascular resistance,<sup>12-14</sup> increased pulmonary arteriolar media thickness,<sup>15</sup> and postnatal interstitial emphysema<sup>16</sup> may play important roles in the progressive hypoxemia and death of these infants. These factors should lead to an increased A-aD<sub>O<sub>2</sub></sub> and PaCO<sub>2</sub>.

Our observation that the A-aD<sub>O<sub>2</sub></sub> from blood sampled above and below the ductus did not differ significantly conflicts with the data of Murdock and Swyer<sup>7</sup> in newborns with congenital diaphragmatic hernia. They found at the time of simultaneous sampling from the right radial and umbilical arteries a significantly higher mean in PaO<sub>2</sub> from the radial artery, although in some infants the difference was negligible. The time of sampling for their study, however, did not correspond to ours, nor were treatment conditions as rigorously controlled. We think that reversal of ductal blood flow to the fetal pattern (pulmonary artery to aorta) tends to develop hours after hernia reduction, and most likely did not occur at the time of sampling in the infants in our study.

Our infants who failed to survive despite reduction of the hernia and intensive respiratory care manifested significantly greater hypoxemia and respiratory acidosis both before and after reduction of the hernia than did surviving infants. The A-aD<sub>O<sub>2</sub></sub> at FI<sub>O<sub>2</sub></sub> 1.00 immediately following reduction of the hernia provided the most reliable guide to ultimate prognosis and the need for extraordinary therapy. Two infants with an A-aD<sub>O<sub>2</sub></sub> over 400 mmHg who ultimately survived and recovered required high frequency mechanical ventilation (70-100 breaths/min) with neuromuscular blockade to achieve PaCO<sub>2</sub> levels below 30 mmHg with arterial pH above 7.40, catheterization of the pulmonary artery with assessment of pressure and flow, and the use of intravenous tolazoline and dopamine to maintain pulmonary blood flow and cardiac output. This experience suggests that increased survival of newborns with congenital diaphragmatic hernia whose post-reduction of A-aD<sub>O<sub>2</sub></sub> exceeds 400 mmHg may be facilitated by monitoring of pulmonary artery pressure and flow in conjunction with therapy to reduce pulmonary vascular resistance and improve alveolar gas exchange. Our experience and that of others<sup>17,18</sup> suggest that such therapy should include

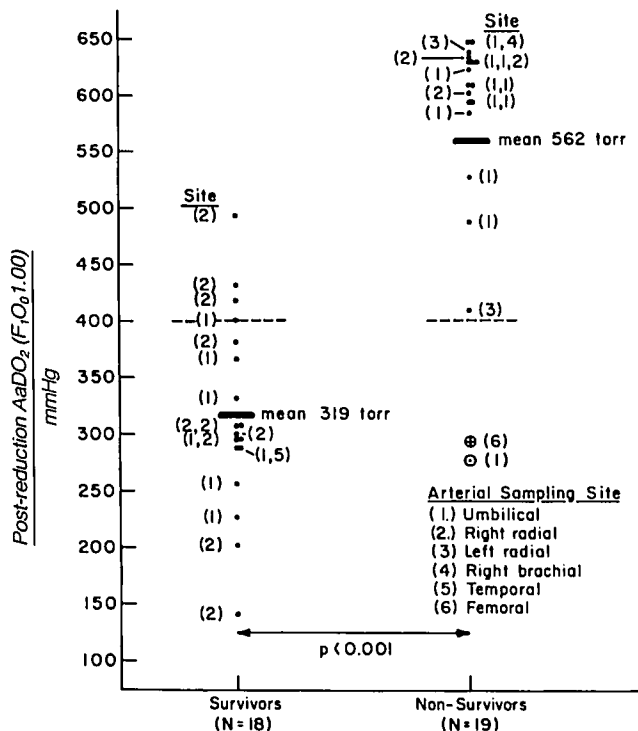


FIG. 3. Mean and individual A-aD<sub>O<sub>2</sub></sub> after reduction of the hernia in surviving and non-surviving newborns with diaphragmatic hernia. Numbers in parentheses indicate sampling site (see key). The symbol ⊕ indicates an infant with Trisomy 13 and severe congenital heart disease; ○ indicates an infant who succumbed from chronic pulmonary failure with bronchopulmonary dysplasia at age 24 months.

high frequency mechanical ventilation and the use of vasodilator and positive inotropic drugs.

In conclusion, survival of full term infants with congenital diaphragmatic hernia but no associated major anomalies seems likely if the post-reduction A-aD<sub>O<sub>2</sub></sub> is less than 400 mmHg, undetermined if between 400 to 500 mmHg, and unlikely if greater than 500 mmHg. This early prognostic indicator should enable the clinician to identify those infants most likely to need exceptionally close surveillance, mechanical hyperventilation, and vasoactive drug therapy before irreversible hypoxemia occurs.

### REFERENCES

1. Srouji MN: The acid-base status of the surgical neonate on admission to the hospital. *Surgery* 62:958-966, 1967
2. Rowe MI, Uribe FL: Diaphragmatic hernia in the newborn infant: blood gas and pH considerations. *Surgery* 70:758-961, 1971
3. Boix-Ocha G, Peguero G, Seijo G, et al: Acid-base balance and blood gases in prognosis and therapy of congenital diaphragmatic hernia. *J Pediatr Surg* 9:49-57, 1974
4. Dibbins AW, Wiener ES: Mortality from neonatal diaphragmatic hernia. *J Pediatr Surg* 9:653-660, 1974
5. Raphaely RC, Downes JJ: Congenital diaphragmatic hernia: prediction of survival. *J Pediatr Surg* 8:815-823, 1973

6. Comroe J, Forster R, Dubois A, et al: *The Lung*. Chicago, Year Book Medical Publishers Inc., 1974, p 339
7. Murdock AI, Burrington JB, Swyer PR: Alveolar to arterial oxygen tension difference and venous admixture in newly born infants with congenital diaphragmatic herniation through the foramen of Bochdalek. *Biol Neonate* 17:161-172, 1971
8. Areechon W, Reid L: Hypoplasia of the lung with congenital diaphragmatic hernia. *Br Med J* 1:230-233, 1963
9. Snyder WH, Greaney EM: Congenital diaphragmatic hernia: 77 consecutive cases. *Surgery* 57:576-588, 1965
10. Starrett RW, de Lorimier AA: Congenital diaphragmatic hernia in lambs: Hemodynamic and ventilatory changes with breathing. *J Pediatr Surg* 10:575-582, 1975
11. Olivet RT, Rupp WM, Telander RL, et al: Hemodynamics of congenital diaphragmatic hernia in lambs. *J Pediatr Surg* 13:231-235, 1978
12. Diggins AW: Neonatal diaphragmatic hernia: a physiologic challenge. *Am J Surg* 131:408-410, 1976
13. Levy RJ, Rosenthal A, Freed MD, et al: Persistent pulmonary hypertension in a newborn with congenital diaphragmatic hernia: successful management with tolazoline. *Pediatrics* 60:740-742, 1977
14. German JC, Gazzaniga AB, Ragnar A, et al: Management of pulmonary insufficiency in diaphragmatic hernia using extracorporeal circulation with a membrane oxygenator (ECMO). *J Pediatr Surg* 12:905-912, 1977
15. Naeye RL, Schochat SJ, Whitman V, et al: Unsuspected pulmonary vascular abnormalities associated with diaphragmatic hernia. *Pediatrics* 58:902-906, 1976
16. Srouji MN, Buck B, Downes JJ: Congenital diaphragmatic hernia: deleterious effects of pulmonary interstitial emphysema and tension extrapulmonary air. *J Pediatr Surg* 16:45-54, 1981
17. Bloss RS, Turmen T, Beardmore HE, et al: Tolazoline therapy for persistent pulmonary hypertension after congenital diaphragmatic hernia repair. *J Pediatr* 97:984-988, 1980
18. Drummond WH, Gregory GA, Heymann MA et al: The independent effects of hyperventilation, tolazoline, and dopamine on infants with persistent pulmonary hypertension. *J Pediatr* 98:603-611, 1981

Anesthesiology  
56:476, 1982

## The Fiberoptic Gastroscope for Difficult Endotracheal Intubation

MARK S. SHULMAN, M.D.,\* AND MICHAEL TROLLOPE, M.D.†

Several authors have described the successful use of the fiberoptic laryngoscope and bronchoscope for difficult endotracheal intubations.<sup>1-3</sup> We report a case of successful endotracheal intubation using a fiberoptic gastro-scope after repeated failures with both a fiberoptic bronchoscope and a fiberoptic laryngoscope.

### REPORT OF A CASE

A 60-year-old man was scheduled for repair of a gastric volvulus. Anesthesia was induced with 350 mg thiopental, iv, and 80 mg succinylcholine, iv, to facilitate endotracheal intubation. Multiple attempts at endotracheal intubation with various laryngoscope blades were unsuccessful and only the tip of the epiglottis could be seen on laryngoscopy. After resumption of spontaneous ventilation, 5 mg diazepam, iv, and enflurane 2 per cent via a mask were administered. Multiple blind attempts via the nares at endotracheal intubation were also unsuccessful. At this time there was a significant accumulation of blood and secretions in the oropharynx. Orotracheal and nasotracheal intubation were attempted first with a fiberoptic laryngoscope and then a fiberoptic bronchoscope. These attempts also were unsuccessful pri-

marily due to lack of adequate suction. An Olympus GIF P3® gastro-scope was then inserted orally, the pharynx and upper airway were suctioned through the gastro-scope, and the vocal cords were then clearly visualized. A 9.5 red rubber endotracheal tube was lubricated and passed over the gastro-scope and the trachea was intubated without difficulty.

### DISCUSSION

The technique of using a gastro-scope for difficult endotracheal intubations has been limited in the past, because of the large diameter of most gastroscopes. The smaller diameter Olympus GIF P3® gastro-scope is small enough to accept a 9.5-mm endotracheal tube. Furthermore, the gastro-scope provides four-way flexion, an excellent ability to suction blood and secretions under direct vision, and the tip can be cleaned easily. We do not advocate the gastro-scope as a first line instrument for endotracheal intubation, but with the use of a 9.5 endotracheal tube it may be a useful alternative to the fiberoptic bronchoscope, especially when large amounts of blood and secretions are present in the airway.

### REFERENCES

1. Murphy P: A fibre-optic endoscope used for nasal intubation. *Anaesthesia* 22:489-491, 1967
2. Taylor PA, Towey RM: The broncho-fiberscope as an aid to endotracheal intubation. *Br J Anaesth* 44:611-612, 1972
3. Conyers AB, Wallace DH, Mulder DS: Use of the fiberoptic bronchoscope for nasotracheal intubation. A case report. *Can Anaesth Soc J* 19:654-656, 1972

\* Acting Assistant Professor of Clinical Anesthesia, Department of Anesthesia.

† Clinical Instructor, Department of Surgery.

Received from the Departments of Anesthesia and Surgery, Stanford University Medical Center, Stanford, California 94305. Accepted for publication December 14, 1981.

Address reprint requests to Dr. Shulman.

Key words: Equipment: fiberoptic gastro-scope; fiberoptic bronchoscope. Intubation, endotracheal: complications, technique.