

Treatment of Severe Tracheobronchomalacia with Continuous Positive Airway Pressure (CPAP)

ROBERT K. KANTER, M.D.,* MURRAY M. POLLACK, M.D.,† WILLIAM W. WRIGHT, RRT,‡
KENNETH M. GRUNDFAST, M.D.§

Airway collapse from tracheal and bronchial wall weakness in patients with tracheobronchomalacia (TBM) may lead to life-threatening airway obstruction. Although continuous positive airway pressure (CPAP) has been recommended to improve respiratory distress in patients with TBM,^{1,2} the benefit of CPAP on pulmonary mechanics in such patients has not been documented. We confirmed the benefit of CPAP and demonstrated improved pulmonary mechanics with high level CPAP in a patient with TBM.

REPORT OF A CASE

A term infant was apneic and required endotracheal intubation and positive pressure ventilation at birth. On physical examination, he had the characteristic features of Larsen's syndrome,^{3,4} including wide set eyes, prominent forehead, flat nasal bridge, cleft posterior palate, dislocations bilaterally at the knees and elbows, deformities of both hands and feet, and spatulate thumbs.

At five days of age, severe respiratory distress followed extubation of the trachea. An emergency tracheostomy was performed. For the next 30 days he breathed comfortably and spontaneously through the tracheostomy tube. However, at 35 days of age, worsening retractions, tachypnea, and intermittent agitation began. The chest radiograph remained clear, and there was no evidence of infection. Bronchoscopy showed no intraluminal lesion below the tracheostomy. Chest fluoroscopy at 40 days of age demonstrated distal tracheal collapse with each expiration. Distress and compromised thoracic air exchange on

auscultation responded to muscle-relaxant-induced paralysis and mechanical ventilation.

Mechanical ventilation with positive end-expiratory pressure (PEEP) 2-5 cmH₂O was necessary for the next month. Spontaneous breathing between mandatory ventilator breaths was sometimes tolerated for several hours, but with agitation or coughing, his expiratory phase became prolonged, breath sounds decreased, and cyanosis and bradycardia often followed. Representative arterial blood-gas values during a typical episode were pH 7.19, P_{CO₂} 79, P_{O₂} 24. Severe episodes occurred 5-6 times each day and required manual positive pressure ventilation, sometimes with paralysis, to restore effective ventilation. External cardiac compression occasionally was needed to maintain circulation during severe hypoxia and bradycardia. Because of the persistent life-threatening expiratory airway obstruction, we attempted to improve ventilation by distending the collapsible airway walls with CPAP.

METHODS

CPAP was regulated with a Bourne infant ventilator. Pulmonary mechanics were measured and recorded at varying levels of CPAP by methods as described by Naulty *et al.*,⁵ including inspiratory and expiratory air flow rates, tidal volume, and transpulmonary pressure. Respiratory rate and minute ventilation were derived from these data. Transpulmonary pressure was measured as the difference between simultaneous airway and esophageal pressures. A latex balloon was placed in the distal third of the esophagus to measure esophageal pressure. End-tidal P_{CO₂} (PET_{CO₂}) was measured by a Cavitron/Anarad PM-20 CO₂ analyzer that had a 90 per cent response time of 300 ms. Pulmonary mechanics were assessed while the infant breathed spontaneously on CPAP = 0 cmH₂O and on CPAP = 8 cmH₂O. CPAP was subsequently raised to 14 cmH₂O to determine the benefit of higher levels. The effect of CPAP on ventilation was also assessed by tidal breathing of Krypton 81-m in which counts per time detected from lung is correlated with ventilation.⁶

RESULTS

During periods of respiratory distress, transpulmonary pressure, tidal volume, and flow rates varied considerably from breath to breath. Ranges observed for these measurements, as well as end-tidal P_{CO₂}, respiratory rate, and minute ventilation are presented in table 1 at indicated levels of CPAP, and representative tracings are presented in figure 1.

* Assistant Professor, Department of Pediatrics, State University of New York, School of Medicine, Upstate Medical Center, Syracuse, New York.

† Assistant Professor, Departments of Anesthesiology, and Child Health and Development, Children's Hospital National Medical Center and George Washington University School of Medicine, Washington, DC.

‡ Department of Respiratory Therapy, Children's Hospital National Medical Center, Washington, DC.

§ Assistant Professor, Department of Otolaryngology, Children's Hospital National Medical Center and George Washington University School of Medicine, Washington, DC.

Received from the Departments of Anesthesiology, Child Health and Development and Otolaryngology, Children's Hospital National Medical Center and George Washington University School of Medicine, Washington DC. Accepted for publication January 25, 1982.

Address reprint requests to Dr. Kanter: Department of Pediatrics, Upstate Medical Center, 750 East Adams Street, Syracuse, New York 13210.

Key words: Airway: obstruction; tracheobronchomalacia; Larsen's Syndrome. Ventilation: continuous positive airway pressure.

TABLE 1. Transpulmonary Pressure Change [P_{ip} (I-E)], Peak Flow Rate (PFR), Tidal Volume (TV), Respiratory Rate (RR), Minute Ventilation (VE), and End-tidal P_{CO_2} (P_{ETCO_2}) at Varying Levels of Continuous Positive Airway Pressure (CPAP)

CPAP (cmH ₂ O)	P_{ip} (I-E)*	PFR (I/E)†	TV (ml)	RR (breaths/min)	\dot{V}_E (ml/min)	P_{ETCO_2} (mmHg)	Comment
0	10-16.5	25-35/20-25	8-10	36	300	78	Agitated, distressed
8	2-9.5	30-70/15-50	10-38	54	832	68-76	Agitated, distressed
14	8-9.5	60-90/50-75	20-25	60	1267	49	2 min after CPAP changed to 14 cmH ₂ O, calm
14	1-2	50-60/50-70	25-38	45	1298	49	7 min after CPAP changed to 14 cmH ₂ O, calm

* P_{ip} (I-E) = change in transpulmonary pressure from inspiration to expiration where transpulmonary pressure = measured airway pres-

sure minus measured esophageal pressure (in cmH₂O).

† PFR (I/E) = Peak flow rate inspiratory/expiratory (in ml/s).

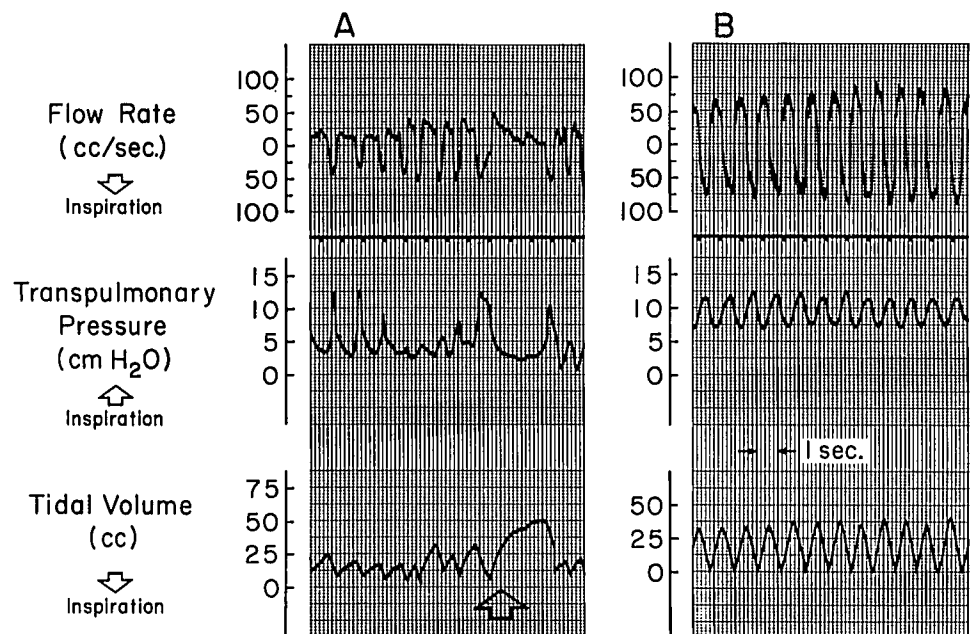
Breathing on zero or low CPAP, the patient became distressed with a prolonged expiratory phase (arrow in fig. 1) and decreased tidal volume. Expiratory flow decreased to near zero despite vigorous respiratory effort, reflected by large swings in transpulmonary pressure from inspiration to expiration. These episodes were clinically identical to those which often progressed to cyanosis and bradycardia. Raising CPAP to 14 cmH₂O relieved distress, increased flow rates, tidal volumes, and minute ventilation, and reduced work of breathing as shown by diminished swings in transpulmonary pressure. End-tidal P_{CO_2} reflected changes in minute ventilation. Esophageal pressure remained between -3 and +2.5 cmH₂O on CPAP as high as 19 cmH₂O.

The effectiveness of CPAP in improving ventilation was confirmed during breathing of Krypton 81-m. Lung

scan showed ventilation doubled with counts rising from 29,270/2 min at 0 cmH₂O CPAP to 59,212/2 min at 25 cmH₂O CPAP.

Because of the success of high CPAP trials in improving this infant's spontaneous ventilation, mechanical ventilation which had previously been maintained at 15 breaths/minute was discontinued. The infant then received 25 cmH₂O CPAP which prevented respiratory distress more consistently than did lower levels of CPAP during a prolonged period of observation. No alteration of hemodynamic status or intravascular fluid volume was noted, and no pneumothorax or pneumomediastinum occurred. His subsequent hospital course was lengthy but uneventful and he was discharged from the hospital at one year of age on a portable CPAP apparatus. He has been cared for successfully at home on 15 cmH₂O

FIG. 1. Tracings demonstrate air-flow in ml/s (top), transpulmonary pressure in cmH₂O (middle), and tidal volume in ml (bottom). (A) Shows patient with distressed breathing on CPAP = 8 cmH₂O. Note wide swings of transpulmonary pressure between inspiration and expiration with low tidal volume and air flow despite labored effort. Also note prolonged forced expiratory phase (arrow). (B) Recording 5 min later on CPAP = 14 cmH₂O with improved tidal volume and air flow and smaller swings of transpulmonary pressure.



CPAP tapering over ten months to 5 cmH₂O. He has had no episodes of severe respiratory distress while on CPAP. He was hospitalized briefly for treatment of pneumonia, but did not require mechanical ventilation. At 22 months of age he can now breathe comfortably for periods of 45 minutes without CPAP.

DISCUSSION

Congenital TBM may cause respiratory distress, stridor, or air trapping distal to a collapsing airway in the neonate or later in infancy.^{1,2} Acquired causes of TBM⁷ also may occur. Although the pathophysiology in Larsen's Syndrome is unknown, mesenchymal tissues are diffusely involved with widespread skeletal hypoplasia and lax cartilaginous structures associated in some cases with severe TBM,^{3,8-10} causing airway obstruction and death in infants.

Variations of airway diameter occur in normal subjects during quiet breathing, but even during forced expiration, airway collapse does not exceed 50 per cent of the lumen diameter in normal infants or adults.^{11,12} In TBM elevated pleural pressure causes greater degrees of tracheobronchial collapse. This airway obstruction may lead to agitation and greater expiratory effort which worsens airway narrowing. Expiratory obstruction with severe TBM is prevented by increasing transpulmonary pressure. This may be achieved either by preventing rises of pleural pressure with sedatives or muscle relaxants, or by maintaining an elevated airway pressure. We found that very high levels of CPAP were required to oppose elevated pleural pressure and maintain airway patency during episodes of forced expiration in this infant. We presume that this exceeded levels necessary in previously reported cases^{1,2} because of the greater severity of his airway laxity.

Although high levels of CPAP may impair cardiovascular function, no adverse hemodynamic effects were observed in our patient. Chapin *et al.*¹³ have demonstrated that the transmission of airway pressure to the pleural space is diminished by increased thoracic wall compliance. The diminished rigidity of skeletal and cartilaginous tissue in Larsen's Syndrome may have increased thoracic wall compliance explaining our finding

that esophageal pressure did not exceed 3 cmH₂O while on CPAP as high as 19 cmH₂O. Circulatory compromise did not occur in this infant because only a small fraction of airway pressure was transmitted to intrathoracic vascular structures.

We confirmed the clinical benefit of high levels of CPAP during episodes of airway obstruction due to TBM and documented improved pulmonary mechanics presumably by increasing transpulmonary pressure and maintaining airway patency. CPAP reduces the need for muscle relaxants and mechanical ventilation in infants with severe TBM.

The authors thank Drs. Gordon Avery and Alan Fields for their advice and technical expertise.

REFERENCES

1. Campbell AGM, Tunstall ME, Shearer AJ: Continuous positive airway pressure in congenital lobar emphysema. *Br Med J* 1:1322, 1977
2. Neijens HJ, Kerrebijn KF, Smalhout B: Successful treatment with CPAP of two infants with bronchomalacia. *Acta Paediatr Scand* 67:293-296, 1978
3. Larsen LJ, Schottstaedt ER, Bost FC: Multiple congenital dislocations associated with characteristic facial abnormality. *J Pediatr* 37:574-581, 1950
4. Robertson FW, Kozłowski K, Middleton RW: Larsen's syndrome. *Clin Pediatr* 14:53-60, 1975
5. Naulty CM, Horn S, Conry J, et al: Improved lung compliance after ligation of patent ductus arteriosus in hyaline membrane disease. *J Pediatr* 93:682-684, 1978
6. Fazio F, Jones T: Assessment of regional ventilation by continuous inhalation of radioactive Krypton 81m. *Br Med J* 3:673-676, 1975
7. Feist JH, Johnson TH, Wilson RJ: Acquired tracheomalacia: Etiology and differential diagnosis. *Chest* 68:340-345, 1975
8. Ronningen H, Bjerkreim I: Larsen's syndrome. *Acta Orthop Scand* 49:138-142, 1978
9. O'Herlihy C, O'Brien N: Neonatal stridor with Larsen's syndrome. *Isr J Med Sci* 13:912-914, 1977
10. Latta RJ, Graham CB, Aase J, et al: Larsen's Syndrome: a skeletal dysplasia with multiple joint dislocations and unusual facies. *J Pediatr* 78:291-298, 1971
11. Fraser RG: Measurements of the calibre of human bronchi in three phases of respiration by cinebronchography. *J Can Assoc Radiol* 12:102-112, 1961
12. Wittenborg MH, Gyepes MT, Crocker D: Tracheal dynamics in infants with respiratory distress, stridor and collapsing trachea. *Radiology* 88:653-662, 1967
13. Chapin JC, Downs JB, Douglas ME, et al: Lung expansion, airway pressure transmission, and positive end-expiratory pressure. *Arch Surg* 114:1193-1197, 1979