

Title: NONLETHAL SLOW INTRAVENOUS AIR INFUSION: EFFECTS OF IPPV AND HIGH FREQUENCY VENTILATION (HFV)

Authors: B. H. Hoff, M.D., A. R. Benedetto, M.Eng., M. L. Nusynowitz, M.D., E. A. Wilson, M.D., R. B. Smith, M.D., G. Pentoja

Affiliations: Department of Anesthesiology and Division of Nuclear Medicine, The University of Texas Health Science Center at San Antonio, Texas 78284

Introduction: Air entry into the central venous circulation can result in circulatory and respiratory insufficiency. This study was performed to determine the effects of IPPV and HFV on blood gases, arterial pressure, and gas distribution and clearance from the heart and pulmonary circulation when a sublethal volume of a mixture of air and xenon-133 was slowly injected intravenously in dogs.

Methods. Ten mongrel dogs (mean wt 20 Kg) were anesthetized with pentobarbital (30 mg/Kg), instrumented with femoral arterial and venous cannulae, intubated with a 7 mm tracheal tube, and ventilated at an F_{iO_2} of 1 with either IPPV using a Harvard ventilator or HFV using a prototype Emerson ventilator. During IPPV the tidal volume was varied between 17-23 ml/Kg and the rate between 7 and 10 breaths/min to achieve a PCO_2 of 35 ± 5 torr. For HFV a rate of 1200 cycles/min with an inflow pressure of 10 psi yielding a ventilator volume of 104 L/min was chosen. These settings also yielded a similar PCO_2 . A fluid filled cannula was placed in the trachea distal to the tracheal tube for measurement of airway pressure. For both forms of ventilation the mean airway pressure was maintained at 10 ± 2 torr. Vascular and airway pressures were measured using standard amplifiers and transducers. Blood gases were measured at time 0 and at 9, 30, and 60 min. After stabilization a mixture of air and xenon-133 (8-10 mCi) was infused intravenously at a rate of 20 ml/min for 9 min.

Sequential two minute images of the heart and lungs were obtained for 50 minutes from the start of the infusion using an Anger scintillation camera. Data was recorded in digital format on disk by means of an MDS Modumed® digital data system. The lung and heart data obtained were used to generate images of the distribution, fate, and excretion of the air/xenon emboli and to generate washin and washout curves and rate constants from selected regions of interest over the lungs and right ventricle (RV). At one hour the dogs were injected with 4 mCi of technetium-99m human albumin microspheres (HAM) and multiple images of the lungs made and evaluated for persistent pulmonary perfusion defects. Results were compared with control nonembolic experiments in which dogs ventilated with IPPV or HFV were injected with 10 mCi xenon-133 dissolved in 2-3 ml of saline and pulmonary images generated and rate constants determined. This was followed by HAM perfusion images for comparison with embolism studies.

Results. Control animals showed almost immediate transfer of the radioactivity from the RV to the lungs with peak activity in the lungs at 40 sec. For both heart and lungs washout was rapid ($k=1.2\% \text{ sec}^{-1}$) and by 3 min more than 90% of the xenon was exhaled in the control animals. There was no evidence of localized pulmonary or cardiac accumulation of xenon or of perfusion defects after HAM.

Blood gases and arterial and airway pressures remained stable. In contrast, the infusion of the gas mixture during IPPV and HFV resulted in accumulation of xenon in the heart with a peak activity occurring at 8 min and a slower transfer of gas to the lungs. At the end of the gas infusion there was a decline in systolic pressure of 65 torr and a concomitant decline in PO_2 and pH and a rise in PCO_2 . Washout from both the RV and lungs were significantly slower ($k = 0.8\% \text{ sec}^{-1}$) than the controls and large xenon air emboli were identified in the lungs and RV. The rates of loss of xenon from the RV and the lungs were equal. By 13 min from the peak activity greater than 90% of the xenon was exhaled. By 60 min the blood gases and arterial pressures had returned to baseline and no major perfusion defects were found after HAM imaging. Comparable results were obtained with both IPPV and HFV.

Conclusions. The slow (20 ml/min) infusion of air/xenon produces right atrial, RV, and pulmonary arterial emboli. These emboli are predominantly removed by the transfer of gas out of the heart into the pulmonary circulation followed by transfer to the alveoli and airway. In this study major persistent perfusion defects did not occur and cardiopulmonary functional decrements were transitory. When transfer of gas from the RV to the lungs is continuous and rapid then recovery should be the case. The effects of HFV and IPPV on the transfer process at the rate and volumes of gas infused were similar.

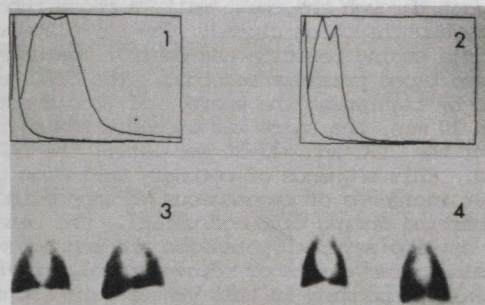


Fig 1. Washin and washout time-activity curves from lungs in control and HFV animal.

Fig 2. Same as Fig. 1 for control and IPPV animal.

Fig 3. HAM lung anterior images for animal of Fig 2. Left, control; right, after embolus. Note absence of major perfusion defects.

Fig 4. HAM lung anterior images for animal of Fig 1. Left, control; right, after embolus. Note absence of major perfusion defects.

This study supported by AHA-Tex Grant #8122.