

Title: RAPID INFUSION AIR EMBOLISM: EFFECTS OF IPPV AND HIGH FREQUENCY VENTILATION (HFV)

Authors: B. H. Hoff, M.D., A. R. Benedetto, M.Eng, M. L. Nusynowitz, M.D., E. A. Wilson, M.D.
R. B. Smith, M.D., G. Pentoja

Affiliations: Department of Anesthesiology and Division of Nuclear Medicine, The University of Texas Health Science Center at San Antonio, Texas 78284

Introduction. The entrainment of air into the central venous circulation can result in respiratory and circulatory decompensation. The object of this study was to determine the effects of intermittent positive pressure ventilation (IPPV) and high frequency ventilation (HFV) on the consequences of rapid intravenous infusion of an air/xenon mixture totalling 6.6 ml/Kg.

Methods. Mongrel dogs with a mean weight of 20 Kg were anesthetized with pentobarbital 30 mg/Kg, intubated with a 7 mm tracheal tube, instrumented with femoral venous and arterial cannulae and with a fluid filled airway cannula placed distal to the tracheal tube. Arterial and airway pressures were continuously monitored. Blood gases were measured. Ventilation was established by either IPPV using a Harvard pump with a minute rate of 7-10 and tidal volume of 17-23 ml/Kg or HFV, using a prototype Emerson ventilator with a rate of 1200 and an inflow pressure of 10 psi yielding a minute outflow of 104 L/min. Ventilation was adjusted to obtain a PCO_2 of 35 ± 5 torr and the mean airway pressure adjusted to 10 ± 2 torr. The FiO_2 was 1 for both types of ventilation. When a stable PCO_2 was obtained the animals were intravenously injected with 6.6 ml/Kg of a mixture of air and xenon-133 (8-10 mCi) at a rate of 50 ml/min. Sequential two min images of the heart and lungs were obtained for 50 min using an Anger scintillation camera and an MDS Modumed® digital data imaging system. At one hour the dogs were injected intravenously with 4 mCi of technetium-99m human albumin microspheres (HAM) and multiple images obtained to evaluate the lungs for persistent perfusion defects. The image data obtained from the xenon/air infusion was used to generate washin and washout curves and rate constants from selected regions of interest over the lungs and right ventricle (RV). Results were compared with control nonembolized dogs which received 10 mCi of xenon-133 dissolved in saline rather than in air and ventilated with IPPV or HFV.

Results. Control dogs showed almost immediate transfer of radioactivity from the RV to the lungs with peak pulmonary activity occurring at 40 sec and rapid washout ($k=1.2\% \text{ sec}^{-1}$). By 9 min, greater than 90% of the xenon was exhaled. In the control animals there was no evidence of localized collections of xenon in the RV or pulmonary artery. Arterial and airway pressures and blood gases remained stable. In contrast, the rapid infusion of the gas mixture resulted in a rapid decline in arterial pressure and a much slower transfer of radioactivity from the RV to the lungs during both IPPV and HFV. The washout rates from the RV and lungs for IPPV were slower than in controls and large air emboli were seen in the lungs and RV. In contrast, corresponding washout rates for HFV approximated those of the controls; large gas emboli were also present. With both forms of ventilation, some animals developed an air lock in the RV which severely retarded

the egress of gas to the lungs; these animals expired rapidly. Figure 1 demonstrates such an embolic RV air lock and a pulmonary embolus; figure 2 shows the slow washout from the RV and lungs. Figure 3 demonstrates transfer of gas to the lungs which was compatible with survival; figure 4 shows the rapid transfer and washout in this animal. Note the markedly differing patterns in the surviving and nonsurviving animals. When a ventricular air lock does not form, an equilibrium is established for gas transfer from the RV to the pulmonary arteries and emboli and to the airways.

Conclusion. The rapid infusion of 6.6 ml/Kg of air was associated with a rapid and profound drop in blood pressure and with the development of an air embolus in the RV. If an air lock was not formed then transfer of air was associated with a return of the blood pressure towards baseline and survival of the animal. Failure of the air lock in the RV to disperse resulted in the demise of the animal. In animals which did not develop an air lock, HFV resulted in more rapid clearance from the RV and lung than IPPV.

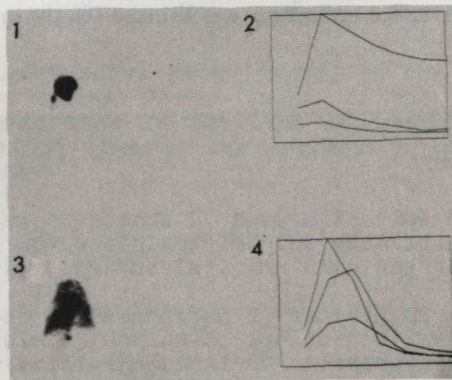


Fig 1. RV air lock and adjacent pulmonary embolus which resulted in demise of dog.
Fig 2. Time-activity washin and washout curves from RV (above) and lungs (below) in dog of Fig 1.
Fig 3. RV and pulmonary radioactivity in a surviving dog.
Fig 4. Time-activity washin and washout curves from RV (above) and lungs (below). Note faster washout rate compared to Fig 2.

This study was supported by AHA-Tex Grant #8122.